

Comparison of therapeutic effect of low-dose low-molecular-weight heparin (enoxaparin) vs. oral prednisone in treatment of patients with lichen planus; A clinical trial

Fariba Iraj, Ali Asilian, Ahmad Saeidi, Amir Hossein Siadat, Ali Reza Saeidi¹, Akbar Hassanzadeh²

Department of Dermatology, Skin Diseases and Leishmaniasis Research Center, Isfahan University of Medical Science, ¹Dental Student's Research Center, School of Dentistry, Isfahan University of Medical Science, ²Epidemiology and Biostatic, School of Health, Isfahan University of Medical Science, Isfahan, Iran

Abstract

Background: The aim of this study was to evaluate and compare the therapeutic efficacy of subcutaneous enoxaparin versus oral prednisone (as a standard treatment) in patients with disseminated lichen planus.

Materials and Methods: In this parallel randomized clinical trial study, overall 48 patients completed the study. 25 patients were treated with subcutaneous enoxaparin 5 mg weekly and 23 patients with 0.5 mg/kg prednisone orally daily until complete remission or a maximum of 8 weeks. The results of itching severity, extent of active lesions and drug side effects were compared. In remission, patients were followed for 6 months for recurrent lesions.

Results: In enoxaparin group, 8 patients (32%) had complete remission and 10 patients (40%) had partial improvement. In the oral prednisone group, 16 patients (69.6%) had complete remission and 6 patients (26.1%) had partial improvement ($P = 0.005$). Average size of active lesions in both groups decreased significantly after treatment, but analysis of covariance showed that the mean lesion size after treatment in the oral prednisone group was significantly lower than the enoxaparin group ($P = 0.005$). The relapse rate from improved patients in the enoxaparin group was 6 (33%) and in oral prednisone group was 9 (40.9%, $P = 0.083$). In the enoxaparin group no serious complications was seen. But 22% in the oral prednisone group show side effect, the most common complications were dyspepsia.

Conclusion: Low dose enoxaparin on lichen Planus have therapeutic effect and is important for the least side effects but not as much as oral prednisone. But it could be accepted as an alternative treatment.

Key Words: Enoxaparin, lichen planus, low molecular weight heparin, prednisone

Address for correspondence:

Dr. Ahmad Saeidi, Department of Dermatology, Alzahra Hospital, Isfahan, Iran. E-mail: ah_saeidi@resident.mui.ac.ir

Received: 19.10.2012, **Accepted:** 03.02.2013

Access this article online	
Quick Response Code:	Website: www.advbiores.net
	DOI: 10.4103/2277-9175.115798

INTRODUCTION

Lichen planus (LP) is a relatively common disease, itchy and inflamed skin, hair follicles and mucosa that is found in all races around the world.^[1,2] The prevalence of skin lesions from 0.22%-1% and mucosal lesions from 0.5 to 4% have been reported.^[3-5]

Copyright: © 2013 Iraj. This is an open-access article distributed under the terms of the Creative Commons Attribution License, which permits unrestricted use, distribution, and reproduction in any medium, provided the original author and source are credited.

How to cite this article: Iraj F, Asilian A, Saeidi A, Siadat AH, Saeidi AR, Hassanzadeh A. Comparison of therapeutic effect of low-dose low-molecular-weight heparin (enoxaparin) vs. oral prednisone in treatment of patients with lichen planus; A clinical trial. *Adv Biomed Res* 2013;2:76.

Disease is usually benign and self-limiting but can cause intolerable generalized itching to patients. One of the most effective treatment in a patients who needs for systemic drug is oral prednisone, but associate with side effect. However, in recent decades as a treatment for LP is use of subcutaneous low- dose low- molecular- weight heparin (enoxaparin).

Although the exact cause of the LP is unknown however, evidence are suggestive of cell-mediated immune responses to changed antigens expressed in keratinocytes as a possible pathogenesis.^[1,2,6] Following the destruction of keratinocytes cytokines release will lead to further accumulation of lymphocytes and eventually led to the destruction of the epidermis and lichenoid reaction. CD4 + lymphocytes produce endoglycosidase (heparanase) which allow them to penetrate into the subendothelial basal lamina.^[2] Low- dose Low- molecular- weight heparin (enoxaparin) has been shown to inhibit expression of heparanase and delayed-type hypersensitivity response.^[7]

To better evaluate the efficacy of enoxaparin in the patients with disseminated lichen planus, the following study was performed.

MATERIALS AND METHODS

Design overview

This was a multicenter, randomized controlled trial study in adult patients with equal randomization (1:1), parallel-group study conducted in the clinics of Isfahan University of Medical Science from February 2010 to March 2012. Written consent was obtained from each patient before study inclusion. The ethics committee of the Isfahan University of Medical Science approved the study protocol (No. 389089), registered in Iranian Registry of clinical Trial, irct.ir.

Participants and setting

Inclusion criteria were all adults age 18 years or older, ability to give informed consent and follow the treatment procedure, and disseminated lichen planus at least for 6 month that confirmed by histopathology.

Exclusion criteria were: (1) any contraindications for heparin and its derivatives such as congenital or acquired homeostasis disorders, uncontrolled hypertension, active peptic ulcer, recent cerebrovascular event, hypersensitivity for heparin and its derivatives (2) liver and renal dysfunction (3) viral hepatitis B and C (4) contraindication for oral prednisone (5) past history for use of drugs that can cause drug induced LP like reaction (6) lichen planopilaris (7) nail lichen planus (8) ulcerative lichen planus (9) pregnancy and lactation (10) side effects that continue of treatment

become at risk such as drug hypersensitivity and acute bleeding.

Randomization and interventions

Patients were randomly divided into two groups. Randomization was simple and alternate, according to patient refer to clinic. In one group injection of enoxaparin (Clexane Sanofi-aventis SpA Milano); 5mg subcutaneously every week until complete remission or a maximum of 8 weeks, Another group were treated with oral prednisone (Nisopred[®], iran hormone) 0.5mg/kg daily until complete remission or a maximum of 8 weeks.

Outcomes and measurements

Before treatment and weekly during treatment patients in both groups were evaluated for severity of pruritus according to visual analogue scale (VAS 0-10), extension of involvement of active lesions according to the percentage of body surface and complications. After treatment patients follow up for 6 mouths (mouths 1, 3 and 6) for recurrence. The primary outcomes were the complete remission. The secondary outcomes were partially remission, change in extension of active lesion, Period between started treatment and remission, recurrence after stop treatment and adverse events.

Statistical analysis

The statistical analysis of the results was done by SPSS (version 20) for Windows software using Chi-Square test for complete remission and drug side effects, Mann-Whitney test for severity of pruritus and analysis of covariance (ANCOVA) for the comparison of active lesion after treatment.

RESULTS

Among 54 patients, finally 48 patients completed treatment modality. One cases due to migration, one case due to scalp involvement and four cases left the study by own. Finally 25 patients were treated with subcutaneous enoxaparin and 23 patients with oral prednisone. The youngest patient was 21 years old and the oldest patient was 75 years old. The mean age of the group treated with subcutaneous enoxaparin was 38.8 ± 14.4 (y) and the group treated with oral prednisone was 36.7 ± 13.7 (y). The two groups had no significant difference in age ($P = 0.61$). Total patients were 19 males and 29 females, 9 males and 16 females in the subcutaneous enoxaparin group and 10 men and 13 women were on oral prednisone group. The two groups had no significant difference in gender ($P = 0.597$).

The mean duration of disease prior to treatment in oral prednisone and enoxaparin groups, respectively

was 6.3 ± 5.6 and 6.4 ± 5 months and Chi-square test showed no difference between the two groups ($P = 0.95$). In enoxaparin group, complete remission was 32% (8 of 25 patients) and relative remission was 40% (10 of 25 patients), but in oral prednisone group, complete remission was 69.6% (16 of 23 patients) and relative remission was 26% (6 of 23 patients). Although each of the treatments had a positive effect on recovery but Mann-Whitney test showed that the rate of improvement in the oral prednisone was significantly better than subcutaneous enoxaparin ($P = 0.005$).

Chi square test showed complete recovery from the effects of oral prednisone significantly better than subcutaneous enoxaparin ($P < 0.001$). [Figure 1].

Independent *t*-test showed that the mean extent of active lesions before treatment in the two groups had no significant difference. After treatment by using *t*-paired test the mean extension of active lesion was significantly reduced in both groups but the analysis of covariance showed that the mean size of active lesions after oral prednisone was significantly lower than enoxaparin ($p = 0.005$) [Table 1].

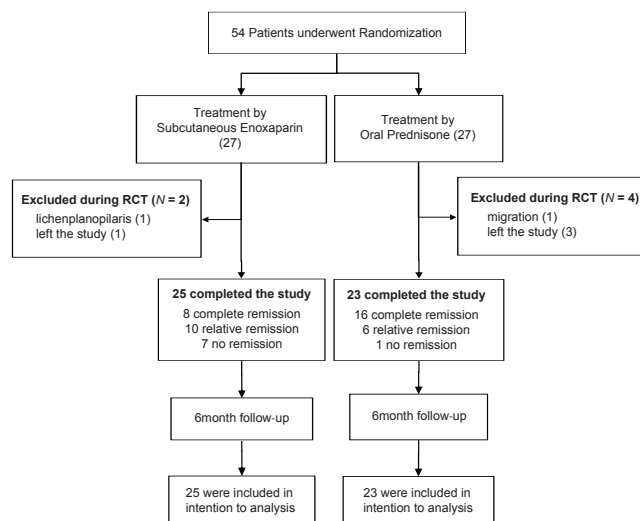
The average time between the start of treatment to improve in enoxaparin was 25.2 ± 13 days and in oral prednisone was 9.7 ± 6 days. The *t*-test showed that the mean onset of therapeutic effect in oral prednisone was significantly lower than enoxaparin ($P < 0.001$).

The relapse rate from improved patients in the enoxaparin group was 33% (6 of 18 patients) and in oral prednisone group was 40.9% (9 of 22 patients), Chi-square test showed no significant difference ($P = 0.46$). The average interval between remission and relapse in prednisone group was 19.6 ± 11 days and in the enoxaparin group was 33.3 ± 16 days ($P = 0.083$).

Mann-Whitney test showed that pre-treatment of itching score did not differ between the two groups ($P = 0.49$), but after treatment itching score in oral prednisone was significantly lower than enoxaparin group ($P = 0.005$).

Reduced itching scores after treatment than before treatment in the prednisone group was significantly more than enoxaparin group ($P = 0.004$) [Table 2].

There was no serious complication such as bleeding or hypersensitivity in the enoxaparin group patients and only in one case itching and new lesions were seen at the injection site. But 22% of patients in the oral prednisone group, had complications, the most common complication was dyspepsia in 4 patients.



Study flow diagram

Table 1: Percentage of active lesions before and after treatment

Groups	Lesion size		P value
	Before treatment	After treatment	
	Mean (SE) %	Mean (SE) %	
Enoxaparin	31.6 (3.04)	19.2 (4.1)	<0.001*
Oral prednisone	36.1 (3.7)	11.3 (5)	<0.001*
P value	0.35**	0.005***	

*Paired *t*-test, **Independent test, ***ANCOVA test, SE: Standard error

Table 2: Itching score before and after treatment

Groups	Itching score			P value
	Before treatment	After treatment	Difference between before and after treatment	
	Enoxaparin	5.96	2.84	
Oral prednisone	6.43	0.83	5.6	<0.001*
P value	**0.49	**0.005	**0.004	

**t*-paired test, **Mann-Whitney test

Dizziness and lethargy in 3 cases, nausea in 1 and 1 case noted flushing.

DISCUSSION

Although the exact cause of lichen planus is unknown, but evidence indicates that cell-mediated immune response to surface antigens of keratinocytes is altered.^[1,2,6] T-Cell Lymphocyte attack to keratinocytes during the process and lymphocytotoxic cytokines released from keratinocytes and cause more attacks of lymphocytes.

Tumor necrosis factor (TNF) α is the pro-inflammatory cytokine has been reported that roles in the pathogenesis and inflammatory process of lichen planus.^[8,9] It has been suggested that heparin inhibits the production of TNF α .^[7]

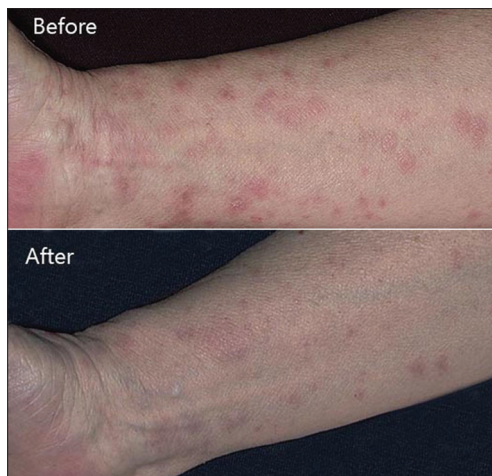

Figure 1: A Patient before and after treatment by subcutaneous Enoxaparin

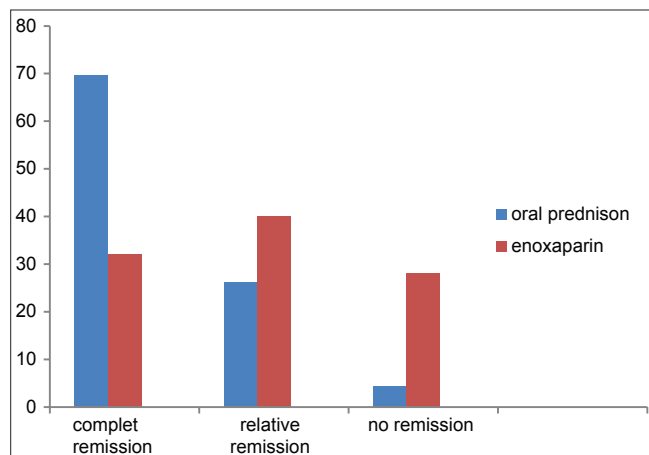


Chart 1: Frequency recovery rate in the two groups

CD4+ cells have been shown to produce endoglycosidase (heparanase) which allows them to penetrate into the subendothelial basal lamina. Low molecular weight heparin (LMWH) has been shown to inhibit expression of heparanase.^[2] In other words, heparin is very similar to heparan sulfate (a component of the dermal extracellular matrix) and may act as a competitive inhibitor of the enzyme heparanase by occupying its binding site.^[10] Also very low dose heparin can inhibit the delayed-type hypersensitivity response.^[7]

In a study of Hodak *et al.*, in 1998 reported on 10 patients with lichen planus treated with enoxaparin did not observe improvement in only 2 cases.^[11] Also in 1999, M.P. Stefanidou study on 18 patients, complete remission was observed in 61% of patients.^[7] Although other studies, including H. Pacheco in 2001, a significant improvement in 5 of the 7 patients,^[12] S. Akdeniz *et al.*, in 2005 on 24 patients and complete remission was reported in 83%,^[2] But several studies

also did not show the improvement in lichen planus with enoxaparin including A. Ferahbaz *et al.*, in 2003,^[10] And Ria R. *et al.*, in 2002.^[13]

When we search the literature, there are reports of other forms of lichen planus such as palmoplantar^[14] and oral^[15] that have improved with low molecular weight heparin.

There are also case reports of patients with chronic and refractory lichen planus that responded only to low molecular weight heparin.^[16]

Usefulness of enoxaparin in the treatment of LP is safety and minimal side effects. Although in this study there was a rash of new lesions at the injection site in one patient that is believed to be caused by Koebner phenomenon, but no serious side effects were observed.

Our results support the positive effect of enoxaparin in treatment of LP, so that 72% of patients showed complete or partial remission. But when compare with oral prednisone that remission was 95.7% this difference is significant. Moreover, even in cases of remission by enoxaparin, treatment significantly was later onset compare with oral prednisone.

One of the positive aspects of the enoxaparin in this study is lower and delayed relapse rate of disease after treatment. Although by this data the difference was not significant.

Finally, we can conclude that low-dose enoxaparin in the treatment of lichen planus could be considered because safety and effectiveness, however, oral prednisone therapy is important in certain cases, especially in cases requiring a rapid, more effective and reliable treatment.

ACKNOWLEDGMENT

We thank all the patients who participated in this study, Isfahan University of Medical Science and skin disease and leishmaniasis research center for support of this study.

This study is registered in www.irct.ir with the code of IRCT2012122211841N1.

REFERENCES

- James WD, Berger TG, Elston DM. Lichen planus and related conditions. In: James WD, Berger TG, Elston DM, editors. *Andrews disease of the skin clinical dermatology*. 10th ed. New York: Elsevier; 2006. p. 217-30.
- Akdeniz S, Harman M, Atmaca S, Yaldiz M. The management of lichen planus with low-molecular-weight heparin (enoxaparin). *Int J Clin pract*

- 2005;59:1268-71.
3. Tetsuo S, Yoko K. Lichen planus and lichenoid dermatosis. In: Bologna JL, Jorizzo JL, Rapini RP, editors. *Dermatology*. 2nd ed. New York: Mosby; 2008. p. 159.
 4. Al-hashimi I, Schifter M, Lockhart PB, Wary D, Brennan M, Migliorati CA, et al. Oral lichen planus and oral lichenoid lesions: Diagnostic and therapeutic considerations. *Oral Surg Oral Med Oral Pathol Oral Radiol Endod* 2007;25:1-12.
 5. Setterfield JF, Blach MM, Challacombe SJ. The management of oral lichen planus. *Clin Exp Dermatol* 2000;25:176-82.
 6. Mark RP, Mazen SD. Lichen planus. In: Wolff K, Goldsmith LA, Katz SI, editors. *Fitzpatrick's dermatology in general medicine*, 7th ed. New York: McGraw Hill; 2008. p. 244-54.
 7. Stefanidou MP, Ioannidou DJ, Panayiotides JG, Tosca AD. low molecular weight heparin; a novel alternative therapeutic approach for lichen planus. *Br J Dermatol* 1999;141:1040-45.
 8. Kobkan T, Kittipong D. Steroids in the treatment of lichen planus: A review. *J Oral Sci* 2008;50:377-85.
 9. Thongprason K, Dhanuthai K, Sarideechaigul W, Chaiyarit P, Chaimusig M. Expression of TNF α in oral lichen planus treated with fluocinolone acetonide 0.1%. *J Oral Pathol Med* 2006;35:161-6.
 10. Ferahbas A, Uksal U, Kutlugun C, Contas O. Low-molecular-weight heparin (enoxaparin) in the treatment of lichen planus. *J Eur Acad Dermatol Venereol* 2003;17:601-19.
 11. Hodak E, Yosipovitch G, David M, Ingber A, Chorev L, Lider O, et al. Low-dose Low-molecular-weight heparin (enoxaparin) is beneficial in lichen planus. *J Am Acad Dermatology* 1998;38:564-8.
 12. Pacheco H, Kerdel F. Successful treatment of lichen planus with low- molecular-weight heparin: A case series of seven patients. *J Dermatol Treat* 2001;12:123-6.
 13. Ria R, Kaur I, Kumar B. Low-dose low-molecular-weight heparin in lichen planus. *J Am Acad Dermatol* 2002;46:141-3.
 14. Yasar S, Serdar ZA, Goktay F, Doner N, Tanzer C, Akkaya D, et al. The successful treatment of palmoplantar hyperkeratotic lichen planus with enoxaparin. *Indian J Dermatol Venereol Leprol* 2011;77:64-6.
 15. Femiano F, Scully C. Oral lichen planus: Clinical and histological evaluation in an open trial using a low molecular weight heparinoid (sulodexide). *Int J Dermatol* 2006;45:986-9.
 16. Neville JA, Hancox JG, Williford PM, Yosipovich G. Treatment of severe cutaneous ulcerative lichen planus with low molecular weight heparin in a patient with hepatitis C. *Cutis* 2007;76:37-40.

Source of Support: Isfahan University of Medical Science, **Conflict of Interest:** None declared.