

# Evaluation of repair in duodenal perforation with human amniotic membrane: An animal model (dog)

Leila Ghahramani, Ali Bagherpour Jahromi, Mohammad Reza Dehghani, Mohammad Javad Ashraf, Salar Rahimikazerooni, Abbas Rezaianzadeh, Ali Reza Safarpour, Seyed Vahid Hosseini

Colorectal Research Center, Shiraz University of Medical Sciences, Shiraz, Iran

## Abstract

**Background:** There is a growing tendency toward application of human amniotic membrane (HAM) as a biologic substitute in various tissue injuries where a significant tissue loss is a matter of concern. In gastrointestinal injuries especially duodenal ones, some potential limitations in current surgical techniques contribute to not fully acceptable healing outcomes. Thus, this study was carried out to assess repair with HAM patch for duodenal defect in comparison with simple duodenorrhaphy in an animal model (dog).

**Materials and Methods:** A total of 15 male German shepherd dogs weighing 23-27 kg were randomly divided into two groups. Group A with 10 dogs, which were a candidate for duodenal repair by amniotic membrane patch and Group B consisted of 5 dogs perform simple duodenorrhaphy. A precise control was made to match all conditions except surgical technique. Macroscopic and microscopic features of the healed duodenal lumen in both groups were recorded.

**Results:** Gross evaluation revealed no difference in luminal diameter in both groups. Statistical analysis of duodenal diameter between both groups after operation also showed no significant difference ( $P_v = 0.789$ ). Histological assessment indicated less inflammation with better wound healing in Group A.

**Conclusion:** It seems that repairing duodenal wall defect with HAM would result in better histological outcomes compared with what is seen in simple duodenorrhaphy in animal models. However, there is no significant difference regarding surgical findings.

**Key Words:** Amniotic membrane, duodenum, experimental study, wound healing

## Address for correspondence:

Dr. Salar Rahimikazerooni, Colorectal Research Center, Shiraz University of Medical Sciences, Shiraz, Iran.

E-mail: [colorectal2@sums.ac.ir](mailto:colorectal2@sums.ac.ir)

Received: 07.09.2013, Accepted: 26.10.2013

## INTRODUCTION

The first academic report of applying human amniotic

membrane (HAM) as a biologic tissue substitute dates back to more than 100 years ago in Johns Hopkins Hospital where 550 patients suffering from skin injuries were treated by this new concept.<sup>[1]</sup> Amniotic membrane has been used for tissue reconstruction, abdominal adhesiolysis, neurolysis, tenolysis and injuries of the vagina and dura matter since that time.<sup>[1-4]</sup>

Significant advantages of HAM applying such as easy availability, low immunogenicity and high potency of differentiation has encouraged researchers to continue this trend to use it for dressing of wounds, repairing

Access this article online	
Quick Response Code:	Website: <a href="http://www.advbiores.net">www.advbiores.net</a>
	DOI: 10.4103/2277-9175.131029

Copyright: © 2014 Ghahramani. This is an open-access article distributed under the terms of the Creative Commons Attribution License, which permits unrestricted use, distribution, and reproduction in any medium, provided the original author and source are credited.

**How to cite this article:** Ghahramani L, Jahromi AB, Dehghani MR, Ashraf MJ, Rahimikazerooni S, Rezaianzadeh A, *et al.* Evaluation of repair in duodenal perforation with human amniotic membrane: An animal model (dog). *Adv Biomed Res* 2014;3:113.

of tendons and treating corneal ulcers.<sup>[4-9]</sup> However, in terms of gastrointestinal (GI) surgeries few articles have been published. To the best of our knowledge, there is only one trial assessing usage of HAM for duodenal injuries repair.<sup>[10]</sup>

Reconstructing some parts of GI tract (esophagus, duodenum and rectum), surgeons may encounter problems due to limitations of the operation site such as fixation and segmental blood supply. Thus, finding techniques to deal with these limitations is inevitable. Using synthetic or biologic grafts is an example of these techniques.<sup>[11,12]</sup> In duodenum, alkaline content is another obstacle of the process of wound healing. Therefore, it seems rational that acceptable results in using HAM for duodenal repairs would provide a practical option in GI tract.

Proper management of duodenal injuries still remains a challenge for surgeons.<sup>[11,13]</sup> In elective and emergency procedure,<sup>[14,15]</sup> conventional duodenal repairing methods may lead to several complications such as suture line disruption, lumen stenosis, obstruction and adhesion bands.<sup>[11]</sup> Therefore, surgeons have not been able to follow a clear algorithm on handling patients in complex duodenal injuries.<sup>[16]</sup>

Considering increased tendency for using HAM in tissue injuries,<sup>[2,8]</sup> we determined the outcome of repairing duodenal defects with HAM patch in comparison with simple duodenoraphy in an animal model (dog). Since the only similar previous study was conducted on the small size animals, working on large size animals would provide more comparative context.

## MATERIALS AND METHODS

A total of 15 male German shepherd dogs, 8-10 months of age, weighing 23-27 kg were purchased from the animal laboratory department of Pasteur Pharmaceutical Institute of Iran in April, 2011. All the dogs were initially evaluated for any probable underlying illnesses with physical examination and screening tests by a single veterinarian. Dogs were individually housed in cages and handled with guideline instructions for care of laboratory dogs provided by Shiraz Animal Laboratory Center in accordance with global standards of laboratory biosafety guidelines. The study was approved by the Research and Ethics Committee of Shiraz University of Medical Sciences.

Animals were randomly divided into Groups A and B. Group A consisted of 10 dogs, which were a candidate for duodenal repair by HAM patch and Group B consisted of 5 dogs undergoing simple duodenoraphy. We performed all the procedures under aseptic conditions.

Protocols for anesthesia, pre- and post-operation care and sacrifice were the same for both groups.

Anesthesia was induced by intravenous thiopental (17 mg/kg) and after endotracheal intubation it was maintained by means of inhalatory gases including halothane and oxygen under controlled ventilation. Normal saline was infused intravenously during operation at a rate of 10 mL/kg/h. After preparation and draping through a 20 cm midline incision, the abdominal cavity was opened. We found gall bladders and duodenum. Proximal and distal parts of duodenum were closed by atraumatic clamp to prevent leakage. Then we induced a semi-circumferential full-thickness defect measuring about 50% of duodenum with a pair of surgical scissors in the anti-mesenteric border of the second part of the duodenum. Duodenal diameter was measured in all animals.

HAM was provided and processed by Shiraz Transplant Research Center and preserved in glutaraldehyde and froze in  $-20^{\circ}\text{C}$ . A fragment of HAM measuring 2.5 cm  $\times$  2 cm was protected from dehydration by floating in to normal saline for 5-10 min in  $24^{\circ}\text{C}$ . HAM was utilized to repair duodenal wall defect as a patch. We fixed it by a 3-0 Vicryl (Polyglactin 910) suture material (semi-absorbable) 3 mm around the defect in 10 selected dogs. Abdominal closure was carried out in layers by running suture of 0-nylon for fascia, 3-0 chromic for subcutaneous plane and 3-0 nylon for skin. In the remaining 5 dogs, the defect was closed by duodenorrhaphy using 3-0 Vicryl suture material (simple repair with separated sutures). The diameter of duodenal lumen was measured in the site of repair in both groups. A single dose of ceftriaxon was administered during operation and continued in the post-operative period for 3 days (dosage of 75 mg/kg divided q12h).

Although NG insertion is routine in management of duodenal injuries none of dogs tolerated it. No oral feeding was given on the 1<sup>st</sup> day; fluid was started on the 2<sup>nd</sup> day, liquid diet on the 3<sup>rd</sup> day and full alimentation on the 4<sup>th</sup> day post-operation. All cases tolerated oral feeding with no considerable adverse events.

All the animals survived up to the time of sacrifice. All the 15 dogs were killed by intravenous Nesdonal at the end of the 8<sup>th</sup> week. Abdomen was opened and the whole duodenum was excised and placed in a fixative solution (Formalin). The diameter of duodenal lumen was measured again in the site of healing as surgical outcome.

Multiple cross-sections were taken from the healing site and anastomosis area and stained with standard hematoxylin and eosin. The effectiveness of HAM in

repairing duodenal wall defect was measured on the basis of pathological assessment as histological outcome.

## RESULTS

In gross evaluation of both groups, no patch disruption occurred. No fistula or leakage was detected in the site of anastomosis. The diameter of duodenal lumen of all animals before and after intervention is shown in Table 1. “A Wilcoxon test illustrated that the diameter of duodenal lumen in control and treatment groups was not significantly affected by types of our intervention ( $z = -1.414$  and  $P = 0.157$ ,  $z = -1.633$  and  $P = 0.102$  in control and treatment groups respectively)”.

A Mann-Whitney test, also showed no significant difference in diameter of duodenal lumen between two groups of study after surgery ( $P = 0.789$ ).

Histological assessing of Group A demonstrated complete repair of mucosa, submucosa and muscular layer associated with mild to moderate chronic inflammatory cell infiltration around the site of patch graft. Serosal surface of the graft was covered with a layer of mesothelial cells. A narrow fibrotic layer was seen between serosal surface and HAM patch [Table 2 and Figure 1].

In Group B, simple duodenoraphy, the inflammatory reaction was a mixture of acute and chronic inflammation. Mucosal epithelialization was nearly complete. Muscle layer showed regeneration with mild to moderate fibrosis and severe inflammation. Serosal surface was healed by fibrous tissue formation [Figure 2].

## DISCUSSION

Our study revealed that repairing duodenal wall defects with HAM in dogs leads to better histological

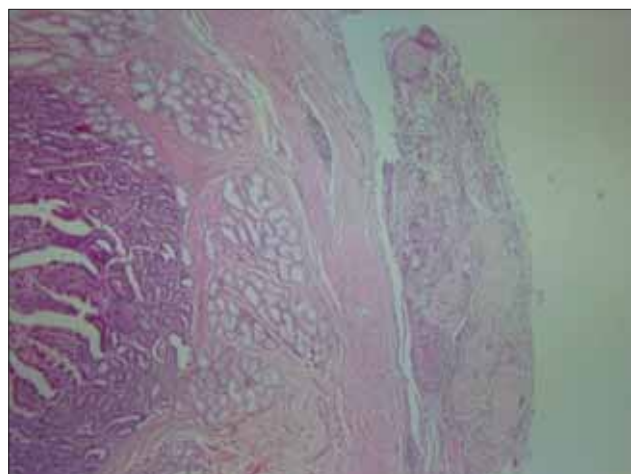
outcomes compared with simple duodenoraphy. This result is in concordance with the findings of some other studies on the small size animals.<sup>[10,17-19]</sup> In a study on 50 Wistar rats, Schimidt *et al.* proved that “HAM allows the wound to heal by second-intention, with re-establishment of duodenal wall structure.”<sup>[10]</sup> HAM was also applied in ileal defects in a study on rabbits by Barlas in Turkey, which resulted in less intestinal obstruction because of better healing resulted from formation of neo-mucosa in site of repair.<sup>[17]</sup> Reduction of intraperitoneal adhesion is another consequence of using HAM graft as a substrate for mesothelial

**Table 1: Duodenal lumen diameter of animals of both groups before and after the operation**

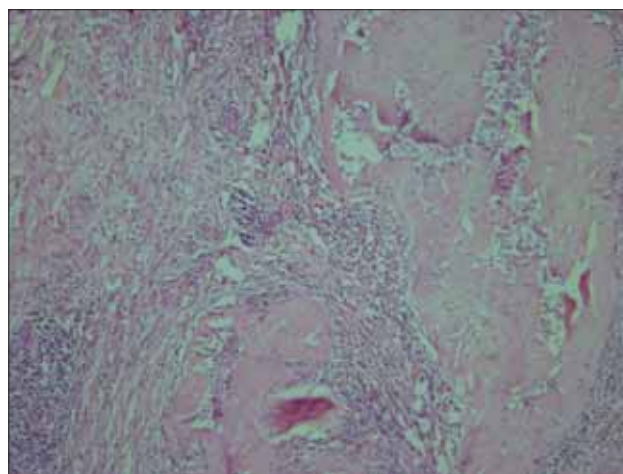
Cases	Operation (diameter/cm)			
	Control (group A)		Treatment (group B)	
	Before	After	Before	After
Dog 1	1.6	1.6	1.6	1.5
Dog 2	1.7	1.6	1.6	1.5
Dog 3	1.5	1.5	1.6	1.6
Dog 4	1.6	1.5	1.6	1.7
Dog 5	1.6	1.6	1.5	1.5
Dog 6			1.7	1.7
Dog 7			1.5	1.5
Dog 8			1.6	1.6
Dog 9			1.7	1.7
Dog 10			1.5	1.5

**Table 2: Histological assessment**

Histopathological findings	Control (group B)	Treatment (group A)
Epithelialization of mucosa	Nearly complete	Complete
Repair of muscular layer	Complete with mild to moderate fibrosis	Complete with minimal fibrosis
Inflammation	Mixture of severe acute and chronic	Mild to moderate, chronic
Fibrosis	Marked	Minimal



**Figure 1:** Complete epithelialization and repair of wall and portion of amniotic membrane patch graft at right side of image, (H and E, x40)



**Figure 2:** Absence of epithelialization and repair, severe acute inflammation, (H and E, x40)

regeneration in a research on rats conducted by Kuriu *et al.*<sup>[20]</sup> Zachariou showed that combining HAM with Vicryl-net results in not only decrease of foreign body reaction, but also increase of higher graft stability.<sup>[21]</sup>

The definite mechanism of HAM to reduction inflammation and increases the process of wound healing has been clear yet. Many research claims that anti-inflammatory mechanism of HAM works by suppressing inflammatory cytokines and expressing anti-inflammatory proteins. In addition tissue growth factors and multi-potent cells of HAM can result in angiogenesis and fibroblastic activity thus, wound strength.<sup>[2,9,18,19,22]</sup>

In contrast, some studies indicate that few features of HAM displayed variations in different organs. For instance, Kobayashi *et al.* showed suppression of corneal angiogenesis because of HAM transplant.<sup>[23]</sup> Moreover, Schimidt *et al.* reported intraperitoneal adhesion in many rats that received HAM graft for the repair of duodenal wall defect. They also point to a trial in which graft necrosis was reported within 1 week after using HAM to repair defects in rat's colon.<sup>[10]</sup> However, Uludag *et al.* conducted a study to evaluate effects of HAM on the healing of colonic anastomoses in 90 rats and they emphasized the role of HAM in preventing adhesion and inflammation.<sup>[18]</sup>

In this regard, we should like to point that if we had facility for fluoroscopy in our animal lab, we could able to evaluate probable post-operative stenosis in both groups that which would improve the validity of our survey would be much more. In addition, potential long-term adverse effects of application of HAM on GI tract should be evaluated in further studies. The difference between health condition of patients suffering from duodenal injury and cases of this study should be regarded as the other limitation.

We hope that working on a large size animal with more similarities to human, regarding GI tract, would lead to application of HAM in eligible human studies.

## CONCLUSION

Since HAM serves a role in regeneration of all layers of duodenal wall, it can be concluded that repairing duodenal wall defects with HAM would result in better surgical and histological outcomes compare with those of simple duodenoraphy in animal models.

## REFERENCES

1. Kesting MR, Wolff KD, Hohlweg-Majert B, Steinstraesser L. The role of allogenic amniotic membrane in burn treatment. *J Burn Care Res* 2008;29:907-16.
2. Uludag M, Ozdilli K, Citgez B, Yetkin G, Ipcioglu OM, Ozcan O, *et al.* Covering the colon anastomoses with amniotic membrane prevents the

- negative effects of early intraperitoneal 5-FU administration on anastomotic healing. *Int J Colorectal Dis* 2010;25:223-32.
3. Yetkin G, Uludag M, Citgez B, Karakoc S, Polat N, Kabukcuoglu F. Prevention of peritoneal adhesions by intraperitoneal administration of vitamin E and human amniotic membrane. *Int J Surg* 2009;7:561-5.
4. Liang H, Li C, Gao A, Liang P, Shao Y, Lin T, *et al.* Spinal duraplasty with two novel substitutes restored locomotor function after acute laceration spinal cord injury in rats. *J Biomed Mater Res B Appl Biomater* 2012;100:2131-40.
5. Toda A, Okabe M, Yoshida T, Nikaido T. The potential of amniotic membrane/amnion-derived cells for regeneration of various tissues. *J Pharmacol Sci* 2007;105:215-28.
6. Mohammadi AA, Johari HG. Anchoring sutures: Useful adjuncts for amniotic membrane for skin graft fixation in extensive burns and near the joints. *Burns* 2010;36:1134.
7. Thatte S. Amniotic membrane transplantation: An option for ocular surface disorders. *Oman J Ophthalmol* 2011;4:67-72.
8. Mohammadi AA, Seyed Jafari SM, Kiasat M, Tavakkolian AR, Imani MT, Ayaz M, *et al.* Effect of fresh human amniotic membrane dressing on graft take in patients with chronic burn wounds compared with conventional methods. *Burns* 2013;39:349-53.
9. Kruse FE, Meller D. Amniotic membrane transplantation for reconstruction of the ocular surface. *Ophthalmology* 2001;98:801-10.
10. Schimidt LR, Cardoso EJ, Schimidt RR, Back LA, Schiazawa MB, d'Acampora AJ, *et al.* The use of amniotic membrane in the repair of duodenal wounds in Wistar rats. *Acta Cir Bras* 2010;25:18-23.
11. Nikeghbalian S, Atefi S, Kazemi K, Jalaeian H, Roshan N, Naderi N, *et al.* Repairing large duodenal injuries in dogs by expanded polytetrafluoroethylene patch. *J Surg Res* 2008;144:17-21.
12. Hosseini SV, Abbasi HR, Rezvani H, Vasei M, Ashraf MJ. Comparison between gallbladder serosal and mucosal patch in duodenal injuries repair in dogs. *J Invest Surg* 2009;22:148-53.
13. Cogbill TH, Moore EE, Feliciano DV, Hoyt DB, Jurkovich GJ, Morris JA, *et al.* Conservative management of duodenal trauma: A multicenter perspective. *J Trauma* 1990;30:1469-75.
14. Soori H, Naghavi M. Deaths from unintentional injuries in rural areas of the Islamic Republic of Iran. *East Mediterr Health J* 1999;5:55-60.
15. Pandey S, Niranjana A, Mishra S, Agrawal T, Singhal BM, Prakash A, *et al.* Retrospective analysis of duodenal injuries: A comprehensive overview. *Saudi J Gastroenterol* 2011;17:142-4.
16. Chen GQ, Yang H. Management of duodenal trauma. *Chin J Traumatol* 2011;14:61-4.
17. Barlas M, Gökçora H, Erekuş S, Dindar H, Yücesan S. Human amniotic membrane as an intestinal patch for neomucosal growth in the rabbit model. *J Pediatr Surg* 1992;27:597-601.
18. Uludag M, Citgez B, Ozkaya O, Yetkin G, Ozcan O, Polat N, *et al.* Effects of amniotic membrane on the healing of normal and high-risk colonic anastomoses in rats. *Int J Colorectal Dis* 2009;24:809-17.
19. Uludag M, Citgez B, Ozkaya O, Yetkin G, Ozcan O, Polat N, *et al.* Effects of amniotic membrane on the healing of primary colonic anastomoses in the cecal ligation and puncture model of secondary peritonitis in rats. *Int J Colorectal Dis* 2009;24:559-67.
20. Kuriu Y, Yamagishi H, Otsuji E, Nakashima S, Miyagawa K, Yoshikawa T, *et al.* Regeneration of peritoneum using amniotic membrane to prevent postoperative adhesions. *Hepatogastroenterology* 2009;56:1064-8.
21. Zachariou Z. Amniotic membranes as prosthetic material: Experimental utilization data of a rat model. *J Pediatr Surg* 1997;32:1458-63.
22. Niknejad H, Peirovi H, Ahmadiani A, Ghanavi J, Jorjani M. Differentiation factors that influence neuronal markers expression *in vitro* from human amniotic epithelial cells. *Eur Cell Mater* 2010;19:22-9.
23. Kobayashi N, Kabuyama Y, Sasaki S, Kato K, Homma Y. Suppression of corneal neovascularization by culture supernatant of human amniotic cells. *Cornea* 2002;21:62-7.

**Source of Support:** The research vice chancellor of Shiraz University of Medical Sciences, **Conflict of Interest:** None declared.