

The effect of pterygium surgery on wavefront analysis

Hasan Razmjoo, Mohammad-Hadi Vaezi, Alireza Peyman, Nima Koosha, Zahra Mohammadi, Maryam Alavirad¹

Departments of Ophthalmology, ¹Psychiatry, Isfahan University of Medical Sciences, Isfahan, Iran

Abstract

Background: Pterygium is a common disorder of the ocular surface. It causes vision impairment -usually irregular type astigmatism- through different mechanisms. In addition, it is believed that surgical excision of the pterygium improves visual problems. The appropriate method to investigate irregular astigmatism is using wavefront analysis. This study was aimed to evaluate wavefront analysis pre and post pterygium surgery.

Materials and Methods: This study was performed on 32 patients who underwent surgical excision of pterygium in January 2012. Data were recorded and compared after pre and postoperative comprehensive ophthalmologic examinations including uncorrected and best corrected visual acuity, Orbscan, wavefront analysis and autorefraction to figure out the effects of surgery on different parameters.

Results: Comparison of pre and postoperative parameters showed that surgical treatment of the pterygium improves numerous parameters significantly including uncorrected and best corrected visual acuity, spherical and cylinder refractive error, higher order aberration, quadrafoil (Z440), corneal astigmatism and 3 and 5 mm central zone corneal irregularity (all *P*-values < 0.0001). In addition, it improves vertical coma (*P*:0.003) and secondary astigmatism (Z420) (*P*:0.004).

Conclusion: It is concluded that surgical excision of the pterygium improves visual acuity, refractive errors and most of the corneal topographic indices and wavefront analysis parameters.

Key Words: Pterygium, wavefront analysis, wavefront aberration, irregular astigmatism, pterygium surgery

Address for correspondence:

Dr. Mohammad Hadi Vaezi, Departments of Ophthalmology, Isfahan University of Medical Sciences, Isfahan, Iran. E-mail: mhadivaezi@gmail.com

Received: 02.07.2012, **Accepted:** 21.07.2012

INTRODUCTION

Pterygium is a benign, elevated, superficial, wedge-shaped fibrovascular proliferation of the conjunctiva which extends onto the corneal surface.^[1-3] It occurs more commonly in people who have had

prolonged UV light exposure, and who lives or works in hot dry windy or dusty environments.^[4]

Pterygium invades into the cornea, and consequently, may cause visual disturbance due to corneal curvature abnormalities. It causes blurred vision as a result of astigmatism which is usually irregular type.^[3,5-7] On the other hand, several studies report that surgical removal of the pterygium leads to improvement of the pterygium induced impaired vision.^[3,5,8-12]

Given the importance of vision impairment, some investigations are performed to determine the impacts of pterygium on refraction and corneal topography. Most of these studies have quantified pterygium

Access this article online	
Quick Response Code:	Website: www.advbiores.net
	DOI: 10.4103/2277-9175.140677

Copyright: © 2014 Razmjoo. This is an open-access article distributed under the terms of the Creative Commons Attribution License, which permits unrestricted use, distribution, and reproduction in any medium, provided the original author and source are credited.

How to cite this article: Razmjoo H, Vaezi M, Peyman A, Koosha N, Mohammadi Z, Alavirad M. The effect of pterygium surgery on wavefront analysis. *Adv Biomed Res* 2014;3:196.

induced visual disturbances as sphere or astigmatism changes; however, it is well-known that sphere and cylinder are not appropriate methods to assess irregular astigmatism.^[3,5,9-13]

Wavefront analysis is a more accurate method for detailed evaluation of optical system of the eye. Imperfections in the refractive surface of the anterior and posterior cornea and the lens can be detected through this method. The estimation of the optical quality of the eye provided by the wavefront analysis is extended beyond the description of spherical and cylindrical refractive errors, and it can measure higher order aberrations (HOA).^[14-17] Therefore, it is believed that wavefront analysis can provide a better assessment of the pterygium induced irregular astigmatism, its effects on the eyesight and impacts of surgery on restoration of normal vision.^[18]

This study was designed to determine and compare wavefront analysis before and after the surgical treatment of pterygium.

MATERIALS AND METHODS

This study was performed on patients with visually significant pterygium referred to the Feiz medical center (Isfahan, Iran) in January 2012.

After approval of the study by the ethic committee of Isfahan University of Medical Sciences and obtaining informed consent, 32 patients who had pterygium on the nasal side of the eye entered this investigation.

Patients who had recurrent pterygium, atypical pterygium, cataract or keratoconus were excluded from the study.

In order to record preoperative characteristics, a comprehensive ophthalmologic examination was performed on all patients before the surgery. This examination included uncorrected and best corrected visual acuity, Orbscan, wavefront analysis and autorefractation.

Then, patients underwent pterygium excision with conjunctival autograft, accompanied by using mitomycin C. The surgery was performed by a single ophthalmologist.

After the surgery, all patients were commenced on Betamethasone eye drop (1 drop every 3 hours) and Ciprofloxacin eye drop (1 drop every 6 hours) for 3 and 1 week, respectively.

Three months after the procedure, patients were

re-examined regarding uncorrected and corrected visual acuity. Moreover, corneal topography and corneal wavefront analysis were performed for all patients. In order to minimize artifacts and aberration, the examination was done with pupil size of 5 mm.

Data were analyzed by SPSS 16 software. One-way ANOVA and paired-*T*-test were used when appropriate.

P values less than 0.05 were considered statistically significant.

RESULTS

Baseline characteristics

The present study investigated 32 patients (18 men and 14 women) with a mean age of 52.23 ± 12.35 years (range: 18-76 years).

Visual acuity

Three months after the operation, both uncorrected and best corrected visual acuity was significantly higher than preoperative values [Table 1]. Comparison of the mean of pre and postoperative LogMar is presented in Figure 1.

None of the patients had postoperative deteriorated visual acuity [Figure 2].

Wavefront analysis

Preoperative mean refractive sphere was $1.67 \pm 2.17D$ which was significantly higher than postoperative refractive sphere 0.89 ± 1.27 (*P* value: 0.007). Similarly, there was significant difference between preoperative and postoperative mean refractive cylinder (-1.89 ± 1.69 vs. -0.77 ± 0.58 , respectively, *P*-value < 0.0001).

No significant difference was found between preoperative and postoperative axis (118.43 ± 64.60 vs. 109.28 ± 10.51 , *P* value: 0.13).

In regard with other wavefront analysis parameters, we found significant difference between preoperative and postoperative values of high order root mean square (HO RMS) for 5 mm wavefront diameter, RMS of vertical coma, RMS of quadrafoil (Z440) and RMS of secondary astigmatism(Z420) [Table 2 and Figure 3].

Table 1: Comparison of preoperative and postoperative visual acuity

	Preoperative	Postoperative	<i>P</i> value
Uncorrected visual acuity	0.31 ± 0.26	0.14 ± 0.17	<0.0001
Best corrected visual acuity	0.19 ± 0.21	0.03 ± 0.04	<0.0001

Data are presented as mean±SD of pre and postoperative LogMar

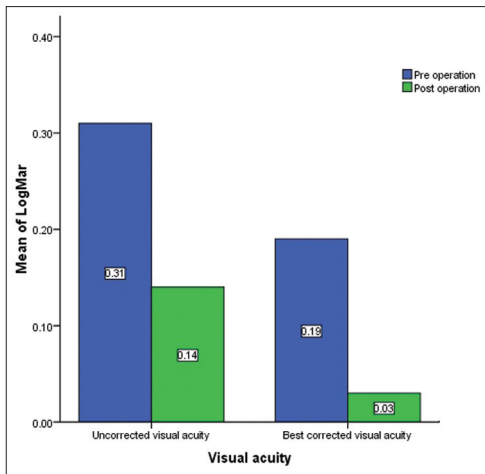


Figure 1: Comparison of the mean of preoperative and postoperative LogMar (uncorrected and best corrected visual acuity). ($P < 0.0001$)

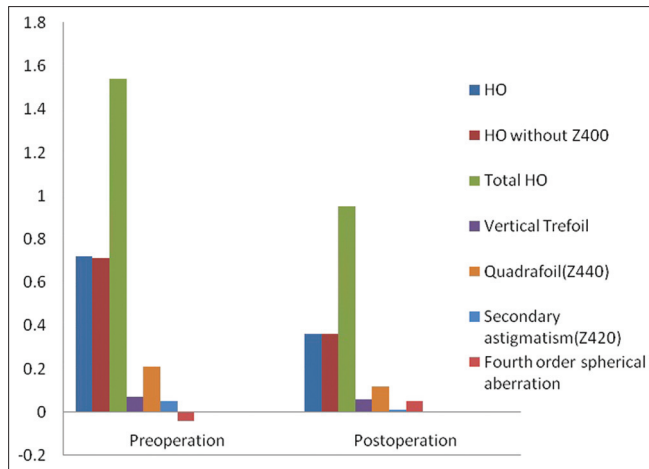


Figure 3: comparison of high-order parameters pre and postoperation

Table 2: Comparison of pre and postoperative HOA parameters

	Preoperative	Postoperative	P value
HO RMS for 5 mm wavefront diameter			
HO (μm)	0.72 ± 0.46	0.38 ± 0.25	<0.0001
HO without Z400 (μm)	0.71 ± 0.46	0.36 ± 0.25	<0.0001
Total (μm)	1.54 ± 1.19	0.95 ± 0.76	<0.0001
RMS of Trefoil			
Vertical(μm)	0.07 ± 0.21	0.06 ± 0.06	0.78
Horizontal (μm)	0.01 ± 0.62	-0.08 ± 0.30	0.15
RMS of coma			
Vertical(μm)	-0.06 ± 0.15	0.0006 ± 0.13	0.003
Horizontal (μm)	-0.003 ± 0.33	0.002 ± 0.18	0.87
RMS of Quadrafoil			
Z440(μm)	0.21 ± 0.16	0.12 ± 0.12	<0.0001
Z441(μm)	-0.03 ± 0.14	0.0006 ± 0.07	0.07
RMS of secondaryastigmatism			
Z420(μm)	0.05 ± 0.09	0.01 ± 0.05	0.004
Z421(μm)	-0.0009 ± 0.05	0.008 ± 0.02	0.20
RMS of fourth order spherical aberration (μm)			
	-0.04 ± 0.11	0.05 ± 0.09	0.59

Data are presented as mean \pm SD, RMS: Root mean square, HO: High order, HOA: High order aberration

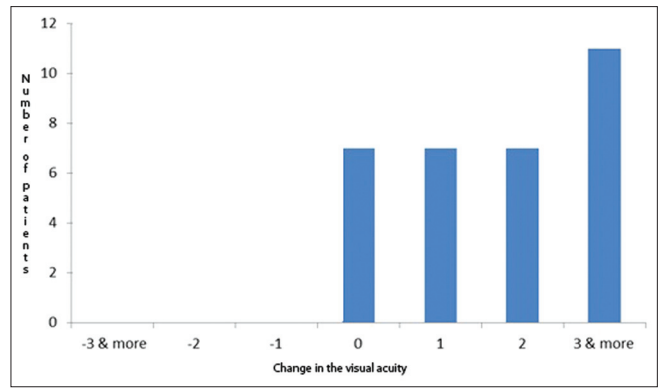


Figure 2: Postoperative visual acuity change status presented as the number of patients and change in the number of Snellen chart lines

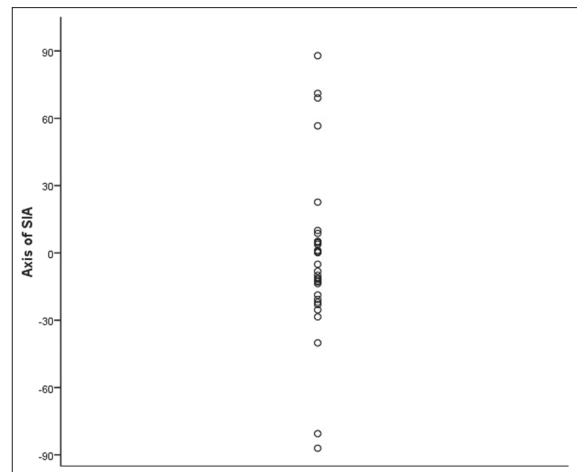


Figure 4: Angle of surgically induced astigmatism (SIA: Surgically induced astigmatism)

Table 3: Comparison of pre and postoperative topographic parameters

	Preoperative	Postoperative	P value
Corneal astigmatism (D)	1.91 ± 1.48	0.90 ± 0.90	<0.0001
Central zone corneal irregularity (D)			
3 mm zone	2.74 ± 1.18	1.70 ± 0.80	<0.0001
5 mm zone	3.86 ± 1.3	2.38 ± 1.06	<0.0001

Data are presented as mean \pm SD, Corneal astigmatism: SimK max-SimK min, SimK: Simulated K, D: Diopter

Orbscan topography

Comparison of preoperative and postoperative Orbscan corneal topography revealed significant difference in corneal astigmatism, corneal irregularity in the central 3 mm and 5 mm zone [Table 3]. Angle of surgically induced astigmatism is presented in Figure 4.

DISCUSSION

Pterygium is a common disease of the ocular surface which has well known impacts on optical irregularities and distortion. It causes visual impairment not only by invading the visual axis or distorting the central

topography, but also by inducing a focal corneal flattening and severe astigmatism;^[7,10] however, the exact mechanism of these changes has not been well understood yet.^[18] Based on the available evidence, surgical treatment of the pterygium usually improves corneal irregularity and visual performance,^[3,5,8-12] and reverses most of the corneal topographic changes.^[19-21]

In the present study, we investigated effects of surgical treatment of pterygium on different aspects of visual performance.

Pterygium may cause correctable refractive errors.^[18] Postoperative mean refractive error (both spherical and cylinder) was significantly lower than preoperative values. Consequently, comparing to the preoperative examination, both uncorrected and best corrected postoperative visual acuity had significant improvement. These findings confirm the previous studies performed by Oh *et al.*^[22] and Bahar *et al.*^[19] which reported improved visual acuity after pterygium surgery. Pterygium induced impaired visual acuity may be caused by alteration in tear film or by mechanical effects of the lesion. Therefore, excision of the lesion may lead to reconstruction of the normal surface, and thus, improvement in the visual acuity.

The most important part of the optical quality of the eye is comprised of ocular wavefront aberrations.^[8] It is believed that pterygium is associated with wavefront aberrations, and increases higher order wavefront aberrations for all Zernike orders and modes, especially trefoil. According to the previous studies, most of the HOA are eliminated after surgical removal of the pterygium.^[18]

Based on our results, pterygium surgery improves several parameters of wavefront analysis. The present study supports findings of Pesudovs *et al.*^[18]

Comparison of pre and postoperative corneal topography also revealed significant changes in the majority of topographic parameters. Similar to what we observed, numerous studies have documented improvement in the corneal condition and topographic indices after pterygium excision.^[19,21,23-25]

Two other studies performed by Maheshwari^[26] and Yousuf^[27] demonstrated that after removal of the pterygium, cornea becomes more regular.

Unlike Yasar *et al.*^[28] who considered no role for fibrovascular traction in pterygium induced corneal changes, Oldenburg *et al.*^[29] and Budak *et al.*^[30] hypothesized that flattening of the cornea and changes in the corneal topography may be produced by a pooling of tears at the apex of the pterygium or by its

mechanical traction. These abnormalities and their effects on the cornea are mostly reversible by the surgery especially in the cases of early intervention.^[12]

In summary, we conclude that surgical excision of the pterygium improves visual acuity, refractive errors and most of the corneal topographic indices and wavefront analysis parameters.

ACKNOWLEDGMENT

Our heartfelt acknowledgement goes to the patients who kindly participated in this research project. We would also like to thank the personnel of Feiz Hospital operation room and Refractive surgery Department.

REFERENCES

1. Coroneo MT, Di Girolamo N, Wakefield D. The pathogenesis of pterygia. *Curr Opin Ophthalmol* 1999;10:282-8.
2. Saleem MI, Channar MS, Saleem MF. Effects of pterygium excision on corneal curvatures. *Pak J Med Sci* 2011;27:325-8.
3. Zare M, Zarei-Ghanavati S, Ansari-Astaneh MR, Baradaran-Rafiee A, Einolahi B. Effects of pterygium on ocular aberrations. *Cornea* 2010;29:1232-5.
4. Kheirkhah A, Casas V, Sheha H, Raju VK, Tseng SC. Role of conjunctival inflammation in surgical outcome after amniotic membrane transplantation with or without fibrin glue for pterygium. *Cornea* 2008;27:56-63.
5. Bedrossian RH. The effects of pterygium surgery on refraction and corneal curvature. *Arch Ophthalmol* 1960;64:553-7.
6. Uy HS, Reyes JM, Flores JD, Lim-Bon-Siong R. Comparison of fibrin glue and sutures for attaching conjunctival autografts after pterygium excision. *Ophthalmology* 2005;112:667-71.
7. Starck T, Kenyon KR, Serrano F. Conjunctival autograft for primary and recurrent pterygia: Surgical technique and problem management. *Cornea* 1991;10:196-202.
8. Gumus K, Erkilic K, Topaktas D, Colin J. Effect of pterygia on refractive indices, corneal topography, and ocular aberrations. *Cornea* 2011;30:24-9.
9. Fong KS, Balakrishnan V, Chee SP, Tan DT. Refractive change following pterygium surgery. *CLAO J* 1998;24:115-7.
10. Lin A, Stern G. Correlation between pterygium size and induced corneal astigmatism. *Cornea* 1998;17:28-30.
11. Tomidokoro A, Miyata K, Sakaguchi Y, Samejima T, Tokunaga T, Oshika T. Effects of pterygium on corneal spherical power and astigmatism. *Ophthalmology* 2000;107:1568-71.
12. Tomidokoro A, Oshika T, Amano S, Eguchi K, Eguchi S. Quantitative analysis of regular and irregular astigmatism induced by pterygium. *Cornea* 1999;18:412-5.
13. Maloney RK, Bogan SJ, Waring GO 3rd. Determination of corneal image-forming properties from corneal topography. *Am J Ophthalmol* 1993;115:31-41.
14. Visser N, Berendschot TT, Verbakel F, Tan AN, de Brabander J, Nuijts RM. Evaluation of the comparability and repeatability of four wavefront aberrometers. *Invest Ophthalmol Vis Sci* 2011;52:1302-11.
15. Schallhorn SC, Farjo AA, Huang D, Boxer Wachler BS, Trattler WB, Tanzer DJ, *et al.* Wavefront-guided LASIK for the correction of primary myopia and astigmatism a report by the American Academy of Ophthalmology. *Ophthalmology* 2008;115:1249-61.
16. Kohnen T, Klaproth OK, Bühren J. Effect of intraocular lens asphericity on quality of vision after cataract removal: An intraindividual comparison. *Ophthalmology* 2009;116:1697-706.
17. Katsoulos C, Karageorgiadis L, Vasileiou N, Mousafeiropoulos T, Asimellis G. Customized hydrogel contact lenses for keratoconus incorporating correction for vertical coma aberration. *Ophthalmic Physiol Opt* 2009;29:321-9.

Hasan, *et al.*: The effect of pterygium surgery on wavefront analysis

18. Pesudovs K, Figueiredo FC. Corneal first surface wavefront aberrations before and after pterygium surgery. *J Refract Surg* 2006;22:921-5.
19. Bahar I, Loya N, Weinberger D, Avisar R. Effect of pterygium surgery on corneal topography: A prospective study. *Cornea* 2004;23:113-7.
20. Maheshwari S. Pterygium Induced Refractive Changes. *Indian J Ophthalmol* 2007;55:383-6.
21. Yilmaz S, Yuksel T, Maden A. Corneal topographic changes after four types of pterygium surgery. *J Refract Surg* 2008;24:160-5.
22. Oh JY, Wee WR. The effect of pterygium surgery on contrast sensitivity and corneal topographic changes. *Clin Ophthalmol* 2010;4:315-9.
23. Cinal A, Yasar T, Demirok A, Topuz H. The effect of pterygium surgery on corneal topography. *Ophthalmic Surg Lasers* 2001;32:35-40.
24. Stern GA, Lin A. Effect of pterygium excision on induced corneal topographic abnormalities. *Cornea* 1998;17:23-7.
25. Yagmur M, Ozcan AA, Sari S, Ersöz TR. Visual acuity and corneal topographic changes related with pterygium surgery. *J Refract Surg* 2005;21:166-70.
26. Maheshwari S. Effect of pterygium excision on pterygium induced astigmatism. *Indian J Ophthalmol* 2003;51:187-8.
27. Yousuf M. Role of pterygium excision in pterygium induced astigmatism. *JK-Practitioner* 2005;12:91-2.
28. Yasar T, Ozdemir M, Cinal A, Demirok A, Ilhan B, Durmus AC. Effects of fibrovascular traction and pooling of tears on corneal topographic changes induced by pterygium. *Eye (Lond)* 2003;17:492-6.
29. Oldenburg JB, Garbus J, McDonnell JM, McDonnell PJ. Conjunctival pterygia. Mechanism of corneal topographic changes. *Cornea* 1990;9:200-4.
30. Budak K, Khater TT, Friedman NJ, Koch DD. Corneal topographic changes induced by excision of perilimbal lesions. *Ophthalmic Surg Lasers* 1999;30:458-64.

Source of Support: Isfahan University of Medical Sciences as dissertation for Ophthalmology speciality graduation, **Conflict of Interest:** None declared.