

# An observational study on the expression of cyclooxygenase-2 in meningioma

Parvin Mahzouni, Tannaz Sarmadi

Department of Pathology, Isfahan University of Medical Sciences, Isfahan, Iran

## Abstract

**Background:** The cyclooxygenase-2 (COX-2) enzyme is overexpressed in different types of tumors and is known to be associated with malignant behavior of tumors. We determined the association of COX-2 expression and different grades of human meningioma.

**Materials and Methods:** This retrospective study was conducted on specimens obtained from adult patients with meningioma. Meningioma was classified according to the WHO 2007 classification protocol (I, II, and III). COX-2 expression intensity was scored based on the percentage of immunopositive cells as 0: 0-10%; +1: >10% and a part of the cell membrane; +2: >10% and complete cell membrane; and +3: >30% and complete cell membrane. Scores of +2 or +3 were considered as COX-2 positive.

**Results:** Ninety meningioma cases (mean age =  $53.0 \pm 13.2$  years, 71.1% female) were studied. COX-2 was positive in 25% (17/68), 68.4% (13/19), and 100% (3/3) of cases with tumor grade I, II, and III, respectively ( $P < 0.001$ ). There was a significant correlation between tumor grade and COX-2 expression score (Spearman's correlation coefficient = 0.422,  $P < 0.001$ ).

**Conclusions:** There is a strong association between COX-2 expression and tumoral grade in meningioma with more aggressive tumors expressing COX-2 with more intensity. Prospective studies examining the association of COX-2 expression with tumor recurrence and interventional studies examining the role of COX-2 inhibitors anticancer therapy of meningioma are warranted.

**Key Words:** Central nervous system neoplasms, cyclooxygenase-2, meningioma

## Address for correspondence:

Dr. Tannaz Sarmadi, Department of Pathology, Isfahan University of Medical Sciences, Isfahan, Iran. E-mail: [tannazsarmadi@gmail.com](mailto:tannazsarmadi@gmail.com)

Received: 12.02.2014, Accepted: 18.05.2014

## INTRODUCTION

Meningiomas are among the most common primary central nervous system (CNS) tumors accounting for 28% of all CNS tumors in Iran.<sup>[1]</sup> According to the

World Health Organization (WHO) classification, meningiomas are classified into three grades; the grade I refers to curable benign tumors with low proliferative index, grade II indicates naturally infiltrative tumors, which often recur and tend to progress to higher grades of malignancy, and grade III is known as malignant meningioma.<sup>[2]</sup> Studies showed that 90% of all meningiomas are benign tumors and 10% are in grade II or III, with unfavorable clinical courses.<sup>[3]</sup> Grade I meningioma sometimes shows malignant progression and recurrence is also observed among this grade.<sup>[4,5]</sup> However, the risk of recurrence is 30-40% for grade II with 5-year survival of 67.5% and 50-80% for grade III with 5-year survival of 60%.<sup>[4]</sup>

Access this article online	
Quick Response Code:	Website: <a href="http://www.advbiores.net">www.advbiores.net</a>
	DOI: 10.4103/2277-9175.143256

Copyright: © 2014 Mahzouni. This is an open-access article distributed under the terms of the Creative Commons Attribution License, which permits unrestricted use, distribution, and reproduction in any medium, provided the original author and source are credited.

**How to cite this article:** Mahzouni P, Sarmadi T. An observational study on the expression of cyclooxygenase-2 in meningioma. *Adv Biomed Res* 2014;3:211.

The treatment strategies suggested for meningioma include surgical resection as well as non-surgical interventions. The high recurrence rate after the surgery in resected meningioma has led to the use of additional therapy to control the tumor growth.<sup>[6]</sup> However, controlling the recurrence rate continues to be a clinical challenge, and routinely there is no pharmaceutical agent to use for adjuvant chemotherapy of meningioma.<sup>[7,8]</sup> Recent studies have focused on new molecular markers as potential therapeutic targets in the treatment of malignant tumors. Cyclooxygenase-2 (COX-2) is one of the new molecular markers studied in this regard. The COX-2 enzyme is overexpressed in different types of tumors including lung, pancreatic, colon, glioma, head and neck, and prostate tumors. This enzyme is also known to be associated with malignant behavior of tumors.<sup>[8-13]</sup>

COX-mediated synthesis of prostaglandins is believed to be associated with the development of inflammation; therefore, non-steroidal anti-inflammatory drugs have anti-inflammatory effects by inhibiting COX through this way. Experimental animal studies suggested that COX-2 inhibitors may slow down the growth of tumors.<sup>[14,15]</sup> Also, the studies on COX-2 inhibitors and their effect on the response of malignant tumors to radiotherapy showed that COX-2 inhibitors can increase the therapeutic effects of radiotherapy.<sup>[16-19]</sup>

Up to now, there are limited data regarding the expression of COX-2 in human meningioma. We determined the association of COX-2 expression with different grades of human meningioma to evaluate COX-2 as a potential target for chemical intervention in these tumors.

## MATERIALS AND METHODS

This retrospective study was conducted on surgical specimens obtained from adult patients with meningioma referred to the Alzahra University Hospital in Isfahan City (Iran) between 2012 and 2013. The study was approved by the Ethics Committee of the Isfahan University of Medical Sciences.

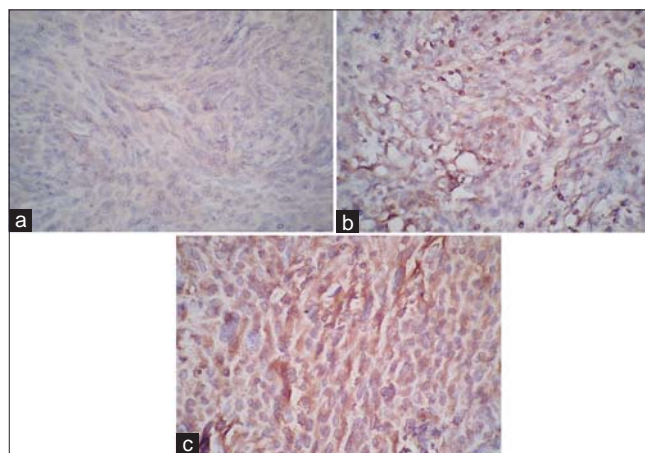
Data regarding patient's age and gender were gathered from the patients' documents. All the slides were examined for the expression of COX-2 by a single pathologist as follows:

### Section preparation

The specimens were fixed with formalin, embedded in paraffin, and stained with hematoxylin and eosin (H and E) and the sections were prepared and meningioma was approved and classified according to

the WHO 2007.<sup>[2]</sup> The tumors immunohistochemical study and grading performed on paraffin-embedded sections of meningioma specimens. The specimens were deparaffinized, dehydrated, and then were boiled in ethylene-diamine-tetraacetic acid buffer (pH 9.0) for 20 minutes. The anti-COX-2 antibody (Genova Scientific S.L.C, Spain, Johann Gulenberg, Clone: SP21, Rabbit Mc Ab) were incubated at 4°C overnight and reacted with a dextran polymer reagent combined with secondary antibodies and peroxidase (Envision, Biogenex, San Ramon, CA). The scoring of COX-2 staining intensity was done on the basis of the percentage of immunopositive cells as follows: 0 was considered when 0-10% of tumoral cells were stained; +1 was considered as more than 10% of the tumoral cells and a part of the cell membrane stained weakly; +2 was considered as more than 10% of the tumoral cells and complete cell membrane stained weakly; and +3 was considered as more than 30% of the tumoral cells and complete cell membrane stained. If the samples were scored 0 or +1 the marker of COX-2 was considered as negative and if the samples were scored +2 or +3 the marker of COX-2 was considered as positive [Figure 1a-c].<sup>[20]</sup> Positive control staining was done with a certain breast cancer with +3 COX-2 expression and negative control staining was done with non-tumoral stromal cells of the breast cancers specimens.

Analyses were done using the SPSS software (version 16.0) for windows. Quantitative and qualitative variables are presented as mean  $\pm$  standard deviation (SD) and number (%), respectively. Association between the tumor grades and COX-2 expression was checked using the Chi-Square test, with a *P* value less than 0.05 considered as statistically significant.



**Figure 1:** The COX-2 staining intensity. (a) More than 10% of the tumoral cells and a part of the cell membrane are stained weakly (score +1). (b) More than 10% of the tumoral cells and complete cell membrane are stained weakly (score +2). (c) More than 30% of the tumoral cells and complete cell membrane are stained (score +3)

**RESULTS**

A total of 90 meningioma sections from 26 (28.9%) male and 64 (71.1%) female patients with mean ± SD of age = 53.0 ± 13.2 years were studied. WHO tumor grade was I in 68 (75.6%), II in 19 (21.1%), and III in 3 (3.3%) of the studied cases.

Among all tumoral grades, 33 (36.7%) slides were COX-2 positive. The association between tumoral grades with COX-2 expression is described in Table 1. COX-2 was positive more frequently in tumors with higher WHO grades ( $P < 0.001$ ). There was a significant correlation between WHO tumor grade and COX-2 expression; more aggressive tumors were associated with increasingly higher levels of COX-2 expression, Figure 2 ( $r = 0.519, P < 0.001$ ). No association was found between COX-2 expression and age ( $P = 0.765$ ) or gender ( $P = 0.290$ ).

**DISCUSSION**

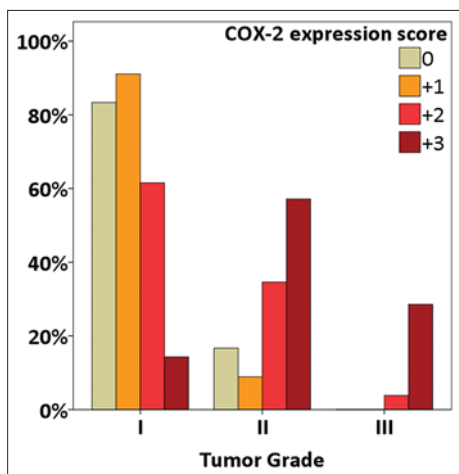
The aim of this study was to investigate the association between different grades of human meningioma and COX-2 expression, to evaluate the COX-2 as a potential target for chemical intervention in these tumors. Our study results showed a significant association

between tumor grade and COX-2 expression among human meningioma as more aggressive tumors were associated with higher levels of COX-2 expression. Previous studies in this regard have shown similar results. Pfister and colleagues in their study on 124 meningioma surgical specimens and normal human cortical tissue samples found high COX-2 immunoreactivity in 100%, 88%, and 63% of malignant, atypical, and benign meningiomas, respectively, but not in normal human cortex and dura tissue.<sup>[21]</sup> A study by Lee *et al.* on 88 specimens of meningioma showed a correlation between COX-2 expression and the recurrence and invasiveness of meningioma. It was also observed that there is a relationship between vascular endothelial growth factor (VEGF) level and COX-2 expression, and they were both correlated with tumor necrosis.<sup>[22]</sup> Another study on the expression of COX-2 in human meningioma and its correlation with vasogenic brain edema showed that COX-2 and VEGF expression are associated with more aggressive meningioma, and also are related with the development of meningioma-associated brain edema.<sup>[23]</sup> The study by Kato and colleagues on 76 cases of meningioma indicated that COX-2 expression was significantly correlated with MIB-1 labeling index which is an accurate predictor for tumor grade and risk of recurrence.<sup>[24]</sup> In this regard, a cohort study on 247 cases of meningioma showed that the recurrence rate among the patients with COX-2 presenting tumors is significantly higher compared with non-recurrent tumors.<sup>[25]</sup>

**Table 1: The association of tumoral grade with COX-2 expression, number (%)**

COX-2 expression	WHO tumor grade			P
	I, n=68	II, n=19	III, n=3	
0	10 (14.7)	2 (10.5)	0	<0.001
+1	41 (60.2)	4 (21.0)	0	
+2	16 (23.5)	9 (47.3)	1 (33.3)	
+3	1 (1.4)	4 (21.0)	2 (66.6)	
COX-2 positive	17 (25)	13 (68.4)	3 (100)	<0.001

WHO: World Health Organization, COX-2: Cyclooxygenase-2



**Figure 2:** The association of tumoral grade with COX-2 expression;  $r = 0.519, P < 0.001$

The studies with the purpose of mechanical evaluation of the association between COX-2 expression and tumors' aggressive behavior revealed that COX-2 derives prostaglandins that can cause tumor growth by inducing newly formed blood vessels and sustain the viability of tumoral cell.<sup>[26]</sup> These findings lead us to two leaps in diagnosis as well as the management of meningioma: (1) in the cases that histological grading of meningioma is not straightforward, immunohistochemical evaluation of COX-2 expression can provide information about the behavior of the tumor; the tumors that are presenting more COX-2 marker are more aggressive with undesirable future, and (2) as the current management strategies for recurrent or malignant meningioma with adjuvant therapies has not been satisfactory,<sup>[7]</sup> the study on new molecular markers to act as therapeutic targets is valuable. The COX-2 is universally expressing in meningioma but not in normal human cortex and dural tissue. Therefore, it can be a possible target for chemotherapeutic intervention and mechanistically anti-COX2 agents can have antiangiogenic activity. In this regard, study on a rat model of angiogenesis showed that corneal blood vessel formation is suppressed by

celecoxib which is an anti-COX-2 agent.<sup>[26]</sup> Another similar study on nude mice showed that celecoxib can inhibit the growth of meningioma, reduce the vascularity, and increase tumoral cell apoptosis.<sup>[27]</sup>

There are some limitations to our study. We did not follow patients to evaluate the association between COX-2 expression and tumor recurrence. Also, there were only three cases with tumor grade III in our study and a larger sample size would provide a better analysis.

## CONCLUSION

In summary, our study showed that there is a strong relationship between COX-2 expression and tumoral grade in meningioma and more aggressive tumors present more COX-2 marker. Prospective studies are needed to determine the association of COX-2 expression with tumor recurrence. COX-2 inhibitors may play a role in anticancer therapy of meningioma and studies are warranted in this regard.

## ACKNOWLEDGMENTS

This study was supported by the Isfahan University of Medical Sciences (grant # 391338). We are thankful to Farinaz Shamsfar, Atefeh Zeidi, Zhila Afshin Nik for preparing IHC staining slides, and Dr. Leila Mirbagher for data analysis and editing this report.

## REFERENCES

- Jazayeri SB, Rahimi-Movaghar V, Shokraneh F, Saadat S, Ramezani R. Epidemiology of primary CNS tumors in Iran: A systematic review. *Asian Pac J Cancer Prev* 2013;14:3979-85.
- Louis DN, Ohgaki H, Wiestler OD, Cavenee WK. WHO Classification of Tumours of the Central Nervous System. 4<sup>th</sup> ed. Lyon: IARC; 2007.
- Norden AD, Drappatz J, Wen PY. Advances in meningioma therapy. *Curr Neurol Neurosci Rep* 2009;9:231-40.
- Lamszus K. Meningioma pathology, genetics, and biology. *J Neuropathol Exp Neurol* 2004;63:275-86.
- Al-Mefty O, Kadri PA, Pravdenkova S, Sawyer JR, Stangeby C, Husain M. Malignant progression in meningioma: Documentation of a series and analysis of cytogenetic findings. *J Neurosurg* 2004;101:210-8.
- Barbaro NM, Gutin PH, Wilson CB, Sheline GE, Boldrey EB, Wara WM. Radiation therapy in the treatment of partially resected meningiomas. *Neurosurgery* 1987;20:525-8.
- Taylor BW Jr, Marcus RB Jr, Friedman WA, Ballinger WE Jr, Million RR. The meningioma controversy: Postoperative radiation therapy. *Int J Radiat Oncol Biol Phys* 1988;15:299-304.
- Goldsmith BJ, Wara WM, Wilson CB, Larson DA. Postoperative irradiation for subtotally resected meningiomas. A retrospective analysis of 140 patients treated from 1967 to 1990. *J Neurosurg* 1994;80:195-201.
- Tucker ON, Dannenberg AJ, Yang EK, Zhang F, Teng L, Daly JM, *et al*. Cyclooxygenase-2 expression is up-regulated in human pancreatic cancer. *Cancer Res* 1999;59:987-90.
- Chan G, Boyle JO, Yang EK, Zhang F, Sacks PG, Shah JP, *et al*. Cyclooxygenase-2 expression is up-regulated in squamous cell carcinoma of the head and neck. *Cancer Res* 1999;59:991-4.
- Yoshimura R, Sano H, Masuda C, Kawamura M, Tsubouchi Y, Chargui J, *et al*. Expression of cyclooxygenase-2 in prostate carcinoma. *Cancer* 2000;89:589-96.
- Soslow RA, Dannenberg AJ, Rush D, Woerner BM, Khan KN, Masferrer J, *et al*. COX-2 is expressed in human pulmonary, colonic, and mammary tumors. *Cancer* 2000;89:2637-45.
- Gaffney DK, Holden J, Davis M, Zempolich K, Murphy KJ, Dodson M. Elevated cyclooxygenase-2 expression correlates with diminished survival in carcinoma of the cervix treated with radiotherapy. *Int J Radiat Oncol Biol Phys* 2001;49:1213-7.
- Koki AT, Leahy KM, Masferrer JL. Potential utility of COX-2 inhibitors in chemoprevention and chemotherapy. *Expert Opin Investig Drugs* 1999;8:1623-38.
- Abou-Issa HM, Alshafie GA, Seibert K, Koki AT, Masferrer JL, Harris RE. Dose-response effects of the COX-2 inhibitor, celecoxib, on the chemoprevention of mammary carcinogenesis. *Anticancer Res* 2001;21:3425-32.
- Milas L, Kishi K, Hunter N, Mason K, Masferrer JL, Tofilon PJ. Enhancement of tumor response to gamma-radiation by an inhibitor of cyclooxygenase-2 enzyme. *J Natl Cancer Inst* 1999;91:1501-4.
- Kishi K, Petersen S, Petersen C, Hunter N, Mason K, Masferrer JL, *et al*. Preferential enhancement of tumor radiosensitivity by a cyclooxygenase-2 inhibitor. *Cancer Res* 2000;60:1326-31.
- Petersen C, Petersen S, Milas L, Lang FF, Tofilon PJ. Enhancement of intrinsic tumor cell radiosensitivity induced by a selective cyclooxygenase-2 inhibitor. *Clin Cancer Res* 2000;6:2513-20.
- Dicker AP, Williams TL, Grant DS. Targeting angiogenic processes by combination rofecoxib and ionizing radiation. *Am J Clin Oncol* 2001;24:438-42.
- Dabbs DJ. Diagnostic Immunohistochemistry: Theranostic and Genomic Applications. 3<sup>rd</sup> ed. Philadelphia: Saunders; 2010.
- Pfister C, Ritz R, Pfrommer H, Bornemann A, Tatagiba MS, Roser F. Are there attacking points in the eicosanoid cascade for chemotherapeutic options in benign meningiomas? *Neurosurg Focus* 2007;23:E8.
- Lee SH, Lee YS, Hong YG, Kang CS. Significance of COX-2 and VEGF expression in histopathologic grading and invasiveness of meningiomas. *APMIS* 2014;122:16-24.
- Pistolessi S, Boldrini L, Gisfredi S, Ursino S, Ali G, Nuti S, *et al*. Expression of cyclooxygenase-2 and its correlation with vasogenic brain edema in human intracranial meningiomas. *Cancer Invest* 2007;25:555-62.
- Kato Y, Nishihara H, Mohri H, Kanno H, Kobayashi H, Kimura T, *et al*. Clinicopathological evaluation of cyclooxygenase-2 expression in meningioma: Immunohistochemical analysis of 76 cases of low and high-grade meningioma. *Brain Tumor Pathol* 2014;31:23-30.
- Ruiz J, Martinez A, Hernandez S, Zimman H, Ferrer M, Fernandez C, *et al*. Clinicopathological variables, immunophenotype, chromosome 1p36 loss and tumour recurrence of 247 meningiomas grade I and II. *Histol Histopathol* 2010;25:341-9.
- Masferrer JL, Leahy KM, Koki AT, Zweifel BS, Settle SL, Woerner BM, *et al*. Antiangiogenic and antitumor activities of cyclooxygenase-2 inhibitors. *Cancer Res* 2000;60:1306-11.
- Ragel BT, Jensen RL, Gillespie DL, Prescott SM, Couldwell WT. Celecoxib inhibits meningioma tumor growth in a mouse xenograft model. *Cancer* 2007;109:588-97.

**Source of Support:** This work was funded by PhD student grant from Pasteur Institute of Iran, **Conflict of Interest:** None declared.