

## Case Report

# Life-threatening misdiagnosis of bulbar onset myasthenia gravis as a motor neuron disease: How much can one rely on exaggerated deep tendon reflexes

Keivan Basiri, Behnaz Ansari, Ali Asghar Okhovat

Department of Neurology, Isfahan Neurosciences Research Center, Alzahra Hospital, Isfahan University of Medical Sciences, Isfahan, Iran

### Abstract

The autoimmune disease myasthenia gravis (MG), can mimic a variety of neurological disorders leading to a delay in diagnosis and treatment. On occasions, misdiagnosis of MG could lead to unnecessary therapeutic interventions. We report the case of a 50 year-old man, in whom MG was mistaken for motor neuron disease (MND). Subsequently, correct diagnosis and optimal management resulted in saving his life and significant improvement in his functional status. We discuss the importance of considering MG as one of the potential differential diagnoses among cases of new onset or recurrent unexplained bulbar symptoms, despite exaggerated deep tendon reflexes. Also, a literature review on the misdiagnosis of MG and the potential pitfalls in MG diagnosis are discussed.

**Key Words:** Bulbar palsy, motor neuron disease, myasthenia gravis

### Address for correspondence:

Dr. Keivan Basiri, Medical School, Alzahra Hospital, Isfahan Neurosciences Research Center, Isfahan University of Medical Sciences, Sofe Avenue, Isfahan, Iran. E-mail: [Basiri@med.mui.ac.ir](mailto:Basiri@med.mui.ac.ir)

**Received:** 15.02.2014, **Accepted:** 19.08.2014

## INTRODUCTION

Myasthenia Gravis (MG) is the most common disorder of neuromuscular transmission and one of the best defined autoimmune diseases. The characteristic sign of the disorder is a fluctuating weakness in the ocular, bulbar, limb, and respiratory muscles.<sup>[1,2]</sup>

The weakness in MG varies in severity and in location from person to person.

More than 50% of the patients present with ocular symptoms of ptosis and/or diplopia.<sup>[3-5]</sup> Of those who present with ocular manifestations, about half will develop the generalized disease within two years.<sup>[4,6]</sup>

About 15% of the patients present with bulbar symptoms. (Dysarthria, dysphagia, and fatigable chewing).

On occasion, the patient will present with only focal bulbar weakness, as seen in our patient, especially in the late onset of MG (LOMG). This is a new entity and symptoms in these patients appear after 65 years. There has been a continuous increase in the incidence of LOMG, with a clear male predominance. Commonly, patients manifest with focal (ocular or bulbar) weakness. In focal bulbar weakness, a high index of suspicion is required to exclude motor neuron disease, as also to improve the prognosis.<sup>[7]</sup>

Access this article online	
Quick Response Code:	Website: <a href="http://www.advbiores.net">www.advbiores.net</a>
	DOI: 10.4103/2277-9175.151874

Copyright: © 2015 Basiri. This is an open-access article distributed under the terms of the Creative Commons Attribution License, which permits unrestricted use, distribution, and reproduction in any medium, provided the original author and source are credited.

**How to cite this article:** Basiri K, Ansari B, Okhovat AA. Life-threatening misdiagnosis of bulbar onset myasthenia gravis as a motor neuron disease: How much can one rely on exaggerated deep tendon reflexes. *Adv Biomed Res* 2015;4:58.

Motor neuron disease (MND) may produce similar symptoms. Amyotrophic lateral sclerosis (ALS), similar to myasthenia, can involve the bulbar muscles, leading to facial weakness, dysarthria or dysphagia. However, ptosis or ocular dysmotility, as typically seen with MG, are not features of ALS. Other manifestations that distinguish ALS from MG are the simultaneous presence of upper motor neuron signs (hyperreflexia and Babinski sign) and lower motor neuron signs (atrophy and fasciculation).<sup>[8]</sup>

Occasional cases might pose as diagnostic challenges with atypical manifestations.<sup>[9,10]</sup>

We report the case of a patient, who presented with bulbar symptoms and upper motor neuron signs that mimicked the motor neuron disease and review the literature.

### CASE REPORT

A 50-year-old man presented with difficulty in swallowing and nasal speech. First he had difficulty swallowing solids, which later progressed to ingestion of liquids.

He mentioned three episodes of nasal regurgitation of liquids. His consort noticed incomplete closing of his eyes during sleep.

The muscles of jaw closure were involved and produced weakness with a prolonged meal time (fatigable chewing). For evaluation of dysphagia, he was referred to an internist for a barium swallow and video fluoroscopy was performed. Benign narrowing of the hypopharynx and pharyngoesophageal junction was detected. He was advised follow-up and was not offered any treatment for stenosis.

The symptom of the patient progressed and he was referred to a neurologist. The neurologist recommended magnetic resonance imaging (MRI) of the brain, an electrophysiological test, and prescribed an acetylcholinesterase inhibitor (AChEi), pyridostigmine 60 mg twice a day. The brain MRI was normal and the electrophysiological findings were reported as a bulbar onset of amyotrophic lateral sclerosis. The acetylcholine receptor antibody titer was normal and in a pharmacological testing with neostigmine no improvement in the bulbar symptom was seen.

After three months, gait disturbance and generalized weakness was added to his symptoms and low dose pyridostigmine was continued due to lack of response.

Several months after the start of the symptoms, he was urgently admitted to the Emergency Department of our University Hospital because of respiratory failure and intubated. In the first neurological examination hyperreflexia was detected and in the light of his previous history, motor neuron disease was suspected and supportive care and neuroprotective drugs were started. The patient was referred to the Internal Medicine Service with an impression of aspiration pneumonia. A few days after admission, a neuromuscular consultation and electrodiagnosis was requested. On the first neuromuscular visit, the patient was intubated and mechanically ventilated. He was extremely cachectic due to several months of dysphagia, and profoundly ill on account of the intercurrent infection. Hyperreflexia in the upper and lower limbs was prominent. Nerve conduction studies (NCS) and electromyography (EMG) of the limbs was normal and no evidence of motor neuron disease (MND) was seen. A repetitive nerve stimulation test revealed a significant decremental response in the proximal and facial muscles, with post activation facilitation and exhaustion (23% decremental response in the trapezius muscle and 32% in the nasalis muscles) [Figures 1 and 2]. Short-duration polyphasic motor unit action potentials (MUAPs) were detected in the bulbar and proximal muscles, without any neurogenic finding. The electrical findings were consistent with a neuromuscular junction defect. The patient was transmitted to the Neuromuscular Service and treated with plasma exchange, pyridostigmine, and prednisone.

The patient recovered dramatically and the bulbar symptoms and limb weakness improved rapidly. He was extubated in a few days and discharged with significant improvement in his functional state. In a follow-up visit there was no evidence of respiratory or bulbar weakness. Ptosis and facial weakness were the prominent signs and the Cogan and peek signs were

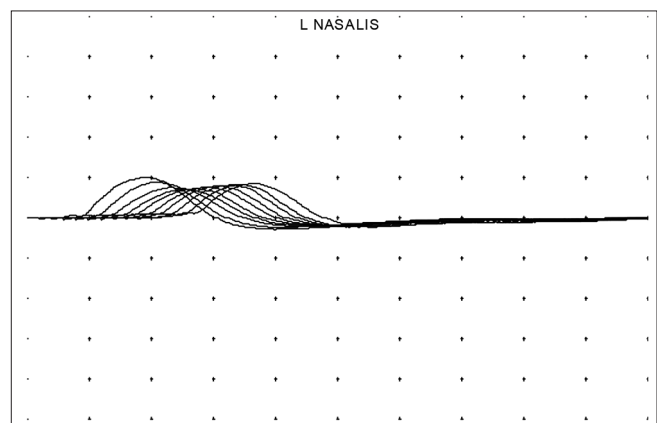


Figure 1: Decremental response in the nasalis muscle

positive. The acetyl choline receptor antibody and anti-MuSK (muscle-specific Kinase) antibody titers were normal. A chest CT scan revealed an anterior mediastinal mass [Figure 3] and the patient was referred for a thymectomy. Thymoma type B2 with capsular invasion was detected in the pathological specimen.

## DISCUSSION

Our patient, with prominent bulbar symptoms and increased tendon reflexes, was mistaken for having motor neuron disease. Prominent bulbar symptoms, lack of obvious ocular findings, and hyperreflexia led to the incorrect interpretation of the findings. Incomplete closure of the eyelids during sleep, in his history, was not adequately addressed. The hyperreflexia and bulbar symptoms deviated the mind of the first examiners toward MND. Hyperreflexia could be physiological or secondary to hyperthyroidism, anxiety or cervical spondylosis, and should not be interpreted as an unchallenging evidence of upper motor disorders. A combination of bulbar symptoms and hyperreflexia probably misled the first electromyographer to interpret myopathic findings in the bulbar muscles as neurogenic features. Another pitfall was the prescription of Acetylcholinesterase inhibitors (AChEi) without a firm diagnosis of MG. This approach was often misleading and in this patient the lack of response to a low dose AChEi was interpreted as evidence against the diagnosis of MG.

This case illustrates the diagnostic challenges posed by MG and the importance of bearing in mind this diagnosis in the case of patients presenting with bulbar symptoms. Therefore, such an atypical presentation, in the absence of obvious ptosis, does not exclude MG.

Careful evaluation and clinical tests would aid in the clinical diagnosis, as well as arranging for appropriate pharmacological, electrophysiological, serological, and imaging studies.

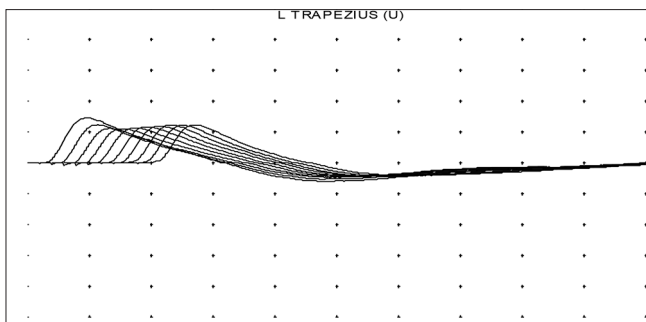


Figure 2: Decremental response in the trapezius muscle

Furthermore, the management pathway should include reconsideration of previous diagnosis at different times, specifically in the context of a poorly documented diagnostic entity in the past.

In the absence of ocular symptoms and signs, limb girdle myasthenia could be misdiagnosed as muscular dystrophy. Rarely, the condition could be confused with central nervous system disorder such as demyelinating disorder or motor neuron disease, especially in the presence of increased deep tendon reflexes.<sup>[11]</sup> A PubMed search revealed 11 cases of MG, which were initially misdiagnosed, or had atypical presentations, leading to a delay in the ultimate diagnosis and treatment.<sup>[12,13]</sup> Patients with initial misdiagnoses had bulbar symptoms that prompted consideration of posterior circulation stroke in the acute setting<sup>[12,14]</sup> or amyotrophic lateral sclerosis similar to our patient. Other misdiagnosis included hysteria,<sup>[15]</sup> myofascial pain syndrome<sup>[16]</sup> and belpharospasm.<sup>[17]</sup>

In our patient, there was a delay of five months in reaching the diagnosis. This delay was compounded by the following issues:

- Sustained increased deep tendon reflexes on neurological examination
- Presence of bulbar palsy at the start of the disease, in the absence of any ocular symptom
- A negative response after cholinesterase inhibitors treatment, such as, a diagnostic test.

It is interesting that many patients with an initial misdiagnosis had bulbar symptoms that prompted a consideration of amyotrophic lateral sclerosis,<sup>[13]</sup> when the bulbar and associated symptoms were of longer duration.

The potential pitfall in the diagnosis of MG includes, first, a variable response to cholinesterase inhibitors. In fact, MG associated with anti-MuSK antibodies may not, at times, significantly benefit from treatment with cholinesterase inhibitors.<sup>[18]</sup> Pharmacological testing with edrophonium or neostigmine and evaluating objective benefits are warranted in all patients

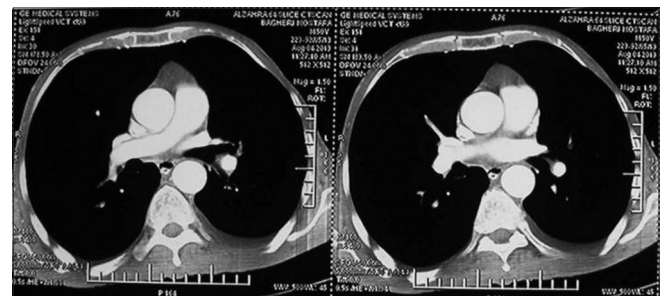


Figure 3: Anterior mediastinal mass (thymoma)

with ocular-bulbar symptoms. The effect of oral acetylcholinesterase inhibitors could not be evaluated objectively and subjective benefit is not reliable for judgment.

The second diagnostic pitfall is a negative acetylcholine receptor antibody and the MuSK antibody in occasional patients. Another diagnostic pitfall is heterogeneity in the clinical progression and course and lack of diurnal variation of the symptoms in some patients. In our patient an atypical bulbar symptom, lack of obvious ocular signs, increased deep tendon reflexes, and lack of response to acetylcholinesterase inhibitors resulted in the misdiagnosis of MG as amyotrophic lateral sclerosis (ALS).

## CONCLUSION

In conclusion, in focal bulbar weakness, a high index of suspicion is required to exclude MG. The present case shows that it is important to consider MG even in cases presenting only with progressive bulbar muscle weakness, especially in older patients, even with an upper motor neuron sign.

## REFERENCES

1. Drachman DB. Myasthenia gravis. *N Engl J Med* 1994;330:1797-810.
2. Keesey JC. Clinical evaluation and management of myasthenia gravis. *Muscle Nerve* 2004;29:484-505.
3. Grob D, Brunner N, Namba T, Pagala M. Lifetime course of myasthenia gravis. *Muscle Nerve* 2008;37:141-9.
4. Grob D, Arsura EL, Brunner NG, Namba T. The course of myasthenia gravis and therapies affecting outcome. *Ann N Y Acad Sci* 1987;505:472-99.
5. Oosterhuis HJ. The natural course of myasthenia gravis: A long term follow up study. *J Neurol Neurosurg Psychiatry* 1989;52:1121-7.
6. Weinberg DH, Rizzo JF 3<sup>rd</sup>, Hayes MT, Kneeland MD, Kelly JJ Jr. Ocular myasthenia gravis: Predictive value of single-fiber electromyography. *Muscle Nerve* 1999;22:1222-7.
7. Akhawahaj NM, Oger J. Late-onset myasthenia gravis: A review when incidence in older adults keeps increasing. *Muscle Nerve* 2013;48:705-10.
8. Mitsumoto H, Chad DA, Pioro EP. Amyotrophic Lateral Sclerosis. *Contemporary Neurology*. Philadelphia: FA Davis Company; 1998.
9. Aragonès JM, Bolibar I, Bonfill X, Bufill E, Mummy A, Alonso F, *IIIa et al.* Myasthenia gravis: A higher than expected incidence in the elderly. *Neurology* 2003;60:1024-6.
10. Andrews PI. Autoimmune myasthenia gravis in childhood. *Semin Neurol* 2004;24:101-10.
11. Khanna S, Liao K, Kaminski HJ, Tomsak RL, Joshi A, Leigh RJ. Ocular myasthenia revisited: Insights from pseudo-internuclear ophthalmoplegia. *J Neurol* 2007; 254:1569-74.
12. Kleiner-Fisman G, Kott HS. Myasthenia gravis mimicking stroke in elderly patients. *Mayo Clin Proc* 1998;73:1077-8.
13. Wheeler SD. Misdiagnosis of myasthenia gravis. *J Natl Med Assoc* 1987;79:425-9.
14. Libman R, Benson R, Einberg K. Myasthenia mimicking vertebrobasilar stroke. *J Neurol* 2002;249:1512-4.
15. Kutz I, Garb R, Kuritzky A. Diagnosis of misdiagnosis: On some of the origins and functions of psychophysical misdiagnosis. *Gen Hosp Psychiatry* 1983;5:197-202.
16. Lloyd JM, Mitchell RG. Myasthenia gravis as a cause of facial pain. *Oral Surg Oral Med Oral Pathol* 1988;66:45-6.
17. Roberts ME, Steiger MJ, Hart IK. Presentation of myasthenia gravis mimicking blepharospasm. *Neurology* 2002;58:150-1.
18. Pasnoor M, Wolfe GI, Nations S, Trivedi J, Barohn RJ, Herbelin L, *et al.* Clinical findings in MuSK-antibody positive myasthenia gravis: A U.S. experience. *Muscle Nerve* 2010;41:370-4.

Source of Support: Nil, Conflict of Interest: None declared.