

Case Report

Toxic epidermal necrolysis in hemodialysis patient

Uday Venkat Mateti, Shankar Prasad Nagaraju¹, Manohar Bairy¹, Ravindra Prabhu Attur¹,
Anantha Naik Nagappa, Anuradha Calicut Kini Rao²

Department of Pharmacy Management, Manipal College of Pharmaceutical Sciences, Departments of ¹Nephrology and ²Pathology,
Kasturba Medical College, Kasturba Hospital, Manipal University, Manipal, Karnataka, India

Abstract Toxic epidermal necrolysis (TEN) is a rare and life-threatening allergic drug reaction. We report a 26-year-old young female with end-stage renal disease on maintenance hemodialysis developing TEN while on filgrastim and phenytoin. It was successfully treated with intravenous immunoglobulins and steroids.

Key words: End stage renal disease, filgrastim, hemodialysis, phenytoin, toxic epidermal necrolysis

Address for correspondence:

Dr. Anantha Naik Nagappa, Professor, Department of Pharmacy Management, Manipal College of Pharmaceutical Sciences,
Manipal University, Manipal - 576 104, Karnataka, India.

E-mail: anantha1232000@gmail.com

Received: 24-10-2013, Accepted: 07-05-2014

INTRODUCTION

Toxic epidermal necrolysis (TEN) is a rare and life-threatening allergic drug reaction. Skin blistering with epidermal and mucosal necrolysis with subsequent detachment from an inflamed underlying dermis is a hallmark of the condition.^[1] The major causative drugs for TEN have been found to be antimicrobials, NSAIDs, and anti-epileptics such as phenytoin, lamotrigine, carbamazepine, and phenobarbital.^[2] We report a case of TEN in an end-stage renal disease patient who was on Phenytoin as an antiepileptic and developed TEN after starting Filgrastim for her leukopenia.

CASE REPORT

A 26-year-old young female with end-stage renal disease due to focal segmental glomerulosclerosis on maintenance hemodialysis was admitted for malignant hypertension to our Nephrology department. She was known to have tuberculous lymphadenitis and was on antituberculosis therapy for the preceding 4 months. On the day of admission, she had an episode of generalized tonic clonic seizures for which she was given 1 gram of phenytoin intravenously as loading dose and was continued on 300 mg PO daily. After 2 weeks, she was noted to have neutropenia (Absolute neutrophil count- <1000/mm³). She was evaluated for neutropenia and filgrastim 300 mcg was injected subcutaneously. Within a few hours of injection she reported itching around the site of injection and swelling of eyes, facial swelling, and itchy red rashes over the lips, face, upper and lower back [Figure 1]. Erythematous papules over legs, hands and several bullae and purpuric lesions over the palm, sole and feet were observed [Figure 2]. She developed desquamation of skin involving >80% of the skin surface and mucosa. There was no involvement

Access this article online	
Quick Response Code:	Website: www.advbiores.net
	DOI: 10.4103/2277-9175.152119

Copyright: © 2015 Mateti. This is an open-access article distributed under the terms of the Creative Commons Attribution License, which permits unrestricted use, distribution, and reproduction in any medium, provided the original author and source are credited.

How to cite this article: Mateti UV, Nagaraju SP, Bairy M, Attur RP, Nagappa AN, Rao AC. Toxic epidermal necrolysis in hemodialysis patient. *Adv Biomed Res* 2015;4:63.

of the eyes. So both phenytoin and filgrastim were withdrawn immediately. A skin biopsy was performed, which showed ulcerated epidermis with necrotic keratinocytes with acrosyringal extension and few eosinophils overlying focally necrotic and edematous papillary dermis with neutrophil and lymphocytic infiltrate, melanin drop out along with perivascular lymphocytosis and adnexal structures. Subepidermal bulla was seen with focal in growth of epidermis [Figure 3]. It was suggestive of TEN.

The patient was shifted to ICU and was treated with intravenous immunoglobulin (IVIG) 2 g/kg over 5 days and steroids with prophylactic antibiotics. Daily dressing was performed. She was continued on hemodialysis during the hospital stay and gradually her skin lesions improved significantly [Figure 4]. Presently she is doing well and is on maintenance hemodialysis.

DISCUSSION

TEN has been reported with antiepileptics especially

with carbamazepine (18.25%) and phenytoin (13.37%) which are usually used in the management of generalized tonic clonic seizures.^[3,4] Most patients who develop TEN on anti-epileptic drugs do so within 8 weeks of starting the drug (85-100%).^[5] Though TEN is a known adverse effect of phenytoin, in our case the patient developed TEN within 4-6 hours after the injection of filgrastim after having been on phenytoin for 2 weeks. So whether the reaction was due to phenytoin or filgrastim or an unknown interaction between the two drugs is unclear. As there was a temporal association with filgrastim, both the drugs were withdrawn. The patient was treated with intravenous immunoglobulins and steroids with complete recovery.

There is a need for continuous reporting of such a rare life-threatening adverse effect of drugs in order to increase awareness and to prevent serious reactions like TEN. This can be confirmed by further detailed assessment of adverse drug reactions which can be performed by using the World Health Organization's (WHO) causality, Naranjo's algorithm and Hartwig scale.

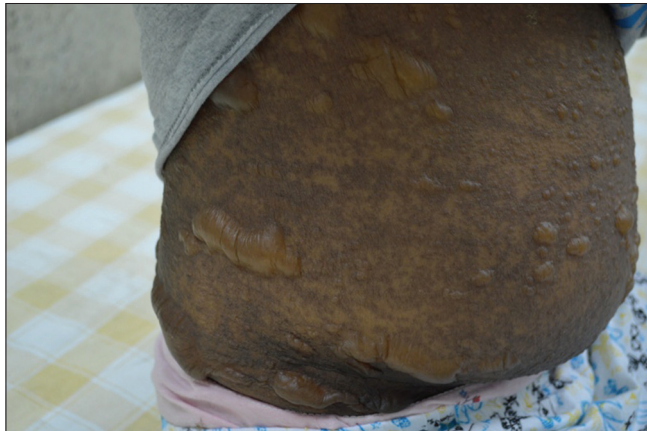

Figure 1: Skin lesions on the trunk

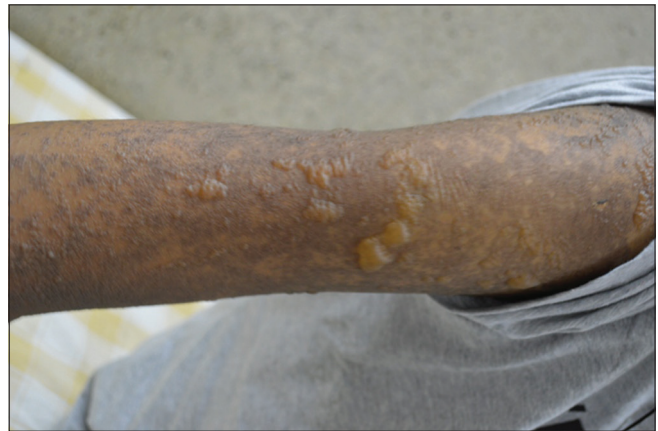

Figure 2: Lesions on the upper limb

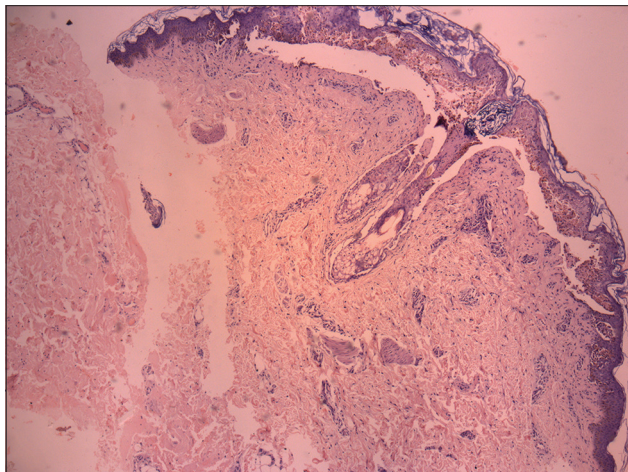


Figure 3: Photomicrograph depicting toxic epidermal necrolysis; H and E stain. (x5)

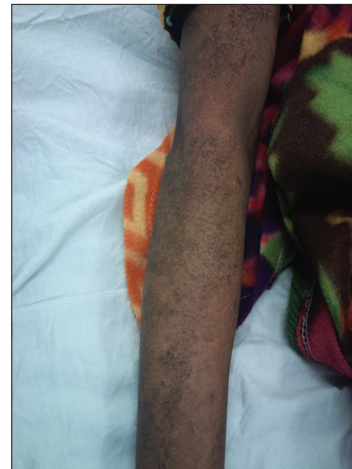

Figure 4: Improvement in the lesions of skin after treatment

REFERENCES

1. Endorf FW, Cancio LC, Gibran NS. Toxic epidermal necrolysis clinical guidelines. *J Burn Care Res* 2008;29:706-12.
2. Fernández FA, Pintor E, Quesada R, Garcés FJ. Toxic epidermal necrolysis induced by phenytoin and whole brain radiotherapy. *Actas Dermosifiliogr* 2007;98:483-5.
3. Radhakrishnan K, Nayak SD, Kumar SP, Sarma PS. Profile of antiepileptic pharmacotherapy in a tertiary referral center in South India: A pharmacoepidemiologic and pharmaco-economic study. *Epilepsia* 1999;40:179-85.
4. Mathur S, Sen S, Ramesh L, M-Kumar S. Utilization pattern of antiepileptic drugs and their adverse effects, in a teaching hospital. *Asian J Pharm Clin Res* 2010;3:55-9.
5. Mockenhaupt M, Viboud C, Dunant A, Naldi L, Halevy S, Bouwes Bavinck JN, *et al.* Stevens-Johnson syndrome and toxic epidermal necrolysis: Assessment of medication risks with emphasis on recently marketed drugs. The EuroSCAR-study. *J Invest Dermatol* 2008;128:35-44.

Source of Support: Nil, **Conflict of Interest:** None declared.