

# A histomorphometric study of the effect of doxycycline and erythromycin on bone formation in dental alveolar socket of rat

Mohammad Shahabooui, Sayed Mohammad Razavi<sup>1</sup>, Mohsen Minaiyan<sup>2</sup>, Reza Birang, Parichehr Behfarnia, Jaber Yaghini, Narges Naghsh, Parichehr Ghalayani<sup>3</sup>, Samira Hajisadeghi<sup>4</sup>

Departments of Periodontology, <sup>1</sup>Oral and Maxillofacial Pathology, Torabinejad Dental Research Center, <sup>3</sup>Oral and Maxillofacial Medicine, School of Dentistry, <sup>2</sup>Department of Pharmacology, School of Pharmacy, Isfahan University of Medical Sciences, Isfahan, <sup>4</sup>Department of Oral and Maxillofacial Medicine, School of Dentistry, Qom University of Medical Sciences, Qom, Iran

## Abstract

**Background:** The aim of the present study was to evaluate whether subantimicrobial doses of doxycycline (DOX) and erythromycin (EM) used for the treatment of peri-implant osteolysis due to their anti-osteoclastogenesis can interfere with the osseous wound healing process in rat alveolar socket.

**Materials and Methods:** Forty-five male Wistar rats had their first maxillary right molar extracted and were divided into three groups. DOX and EM at the doses of 5 mg/kg/day orally (p.o.) and 2 mg/kg/day intraperitoneally (i.p.) were administered respectively to two separate groups for 7 days after operation. In the control group the animals received normal saline (5 ml/kg). Five rats were sacrificed at 7, 14 and 21 days post-extraction in each study group. A histomorphometric analysis was used to evaluate new bone formation inside the alveolar socket. Significant level was set at 0.05.

**Results:** The findings showed that the percentage of new bone formation (NBF) enhanced significantly on days 7 and 14. There was no significant difference in the NBF between DOX and EM groups.

**Conclusion:** Short-term treatment with both DOX and EM enhanced new bone formation without any advances in favor of each drug.

**Key Words:** Doxycycline, erythromycin, histomorphometry, osteogenesis, rats

## Address for correspondence:

Dr. Narges Naghsh, Department of Periodontology, Isfahan University of Medical Sciences, Isfahan, Iran. E-mail: [n\\_naghsh@dnt.mui.ac.ir](mailto:n_naghsh@dnt.mui.ac.ir)

Received: 14.09.2013, Accepted: 01.06.2014

## INTRODUCTION

Following tooth extraction, the healing process of the empty socket begins with the formation of woven bone which ultimately remodels and restores the defect.<sup>[1]</sup> Many factors can influence and enhance or even delay the process of bone healing. These factors include: Type of tissue, location and condition of wound, its vascular supply, microbial condition and local and systemic factors.<sup>[2,3]</sup> Systemic factors such as cytokines, hormones, adhesion molecules and growth factors can

Access this article online	
Quick Response Code:	Website: <a href="http://www.advbiores.net">www.advbiores.net</a>
	DOI: 10.4103/2277-9175.153895

Copyright: © 2015 Shahabooui. This is an open-access article distributed under the terms of the Creative Commons Attribution License, which permits unrestricted use, distribution, and reproduction in any medium, provided the original author and source are credited.

**How to cite this article:** Shahabooui M, Razavi SM, Minaiyan M, Birang R, Behfarnia P, Yaghini J, *et al.* A histomorphometric study of the effect of doxycycline and erythromycin on bone formation in dental alveolar socket of rat. *Adv Biomed Res* 2015;4:71.

regulate the proliferation, differentiation, function and survival of bone cells.<sup>[4]</sup> The formation and remodeling of bone structures result from coupling subsequent deposition of bone matrix by osteoblasts which balances bone resorption by activated osteoclast.<sup>[5]</sup>

Chemically modified tetracyclines (CMTs) are derivatives of tetracycline group of drugs which lack antimicrobial action and have significant effect on bone cells *in vitro* and *in vivo*. Literatures describing the effects of tetracyclines (TCs) in osteoblasts are limited, but recent reports suggest that some TCs may have an anabolic effect in bone.<sup>[6,7]</sup> In a recent study, Williams *et al.* reported that minocycline moderately increased bone mineral density in old ovariectomized (OVX) rats characterized by a two-fold induced bone formation rate. The authors concluded that the overall effect was likely to be due to an increase in bone formation coupled with a decrease in bone resorption.<sup>[8]</sup> Others have reported that TCs can increase bone formation in diabetic and OVX rats.<sup>[9-12]</sup>

Doxycycline (DOX) belongs to CMT family antibiotics. Recently, it has been reported that DOX was able to inhibit *in vitro* osteoclastogenesis and cause apoptosis of mature osteoclasts caused bone resorption. These effects extend beyond the mere inhibition of matrix metalloproteinase (MMP).<sup>[7,13]</sup> Erythromycin (EM), a 14-membered lactone ring macrolide antibiotic, has attracted recently clinical attention because of its anti-inflammatory effects that are independent of its antimicrobial action.<sup>[14-16]</sup> In a previous *in vitro* study, it was demonstrated that EM significantly inhibited mRNA expression of NF- $\kappa$ B, cathepsin k (CPk), IL-1B, and TNF- $\alpha$  in wear debris-activated mouse RAW-264.7 macrophage cell line, associated with the reduction of NF- $\kappa$ B DNA-binding activity.<sup>[17]</sup> In another study in the orthopedic area, it was demonstrated that periprosthetic EM delivery reduced regional inflammation and improved the quality of surrounding bone.<sup>[18]</sup>

As there is no comparative clinical study about bone formation potential of these two antibiotics, the purpose of the present study was to compare the effect of subantimicrobial doses of DOX and EM on the amount of new bone formation by histomorphometric analysis following tooth extraction, a common dental surgical procedure, in rats.

## MATERIALS AND METHODS

Forty-five male Wistar rats (8-10 weeks old at the beginning of the study) with an average body weight of (200  $\pm$  25g) were used in this study. All the procedures were conducted in accordance with ethics protocol of

animal research that was approved by the institute for laboratory animals, Isfahan University of Medical Sciences. The animals were maintained in a collimate-controlled room (12 h light-12 h dark, 22  $\pm$  2°C) with free access to water and rat food pellets.

Rats randomly assigned to one of three following groups:

1. Control group: The rats underwent tooth extraction only and received normal saline (5 ml/kg,  $n = 15$ ) by gavage.
2. Doxycycline group: The rats underwent tooth extraction and treated by DOX (5 mg/kg/day, orally by feeding tube for one week after operation,  $n = 15$ ).<sup>[19]</sup>
3. Erythromycin group: The rats underwent tooth extraction and treated by EM (2 mg/kg/day, intraperitoneally, for one week after operation  $n = 15$ ).<sup>[18]</sup>

The first maxillary right molar of all groups were carefully extracted under general anesthesia with intramuscular injection of a mixture of Ketamine 10% (Alfasan International, Woerden, Holland, 80 mg/kg) and xylazine (Neurotranq, Alfasan, Woerden, Holand, 8 mg/kg). No antibiotic or other medications were used. Treatment with test drugs were started at the day of tooth extraction and continued daily for 1 week.

All the rats were sacrificed at 1, 2 and 3 weeks after the operation (five rats in each interval in each group) with over dose ether inhalation. Then the rats maxillae were removed and dissected sagittally, so that the right sections of each animal was reserved and was stripped of musculature, cut cross-sectionally with a hand-held saw to isolate the region of the body with the extraction site.

## Histomorphometric evaluation

The samples were then fixed in a 4% paraformaldehyde solution, demineralized with 10% EDTA (Merck, Darmstadt, Germany) and embedded with paraffin (Merck, Darmstadt, Germany). The pieces were sectioned perpendicular to the long axis of the alveolar process with a microtom (Accu-Cut SRM, SAKURA, USA) in order to obtain slices with 5  $\mu$ m thicknesses, which were mounted in previously poly-L-lysine slides and stained with hematoxylin and eosin (H&E). For each sample five sections were prepared. The best section for each sample was selected for the histomorphometric analysis of the bone formation in the middle third of the rat alveolus.

The healing process, which in this phase consists of a gradual replacement of connective tissue by bone trabeculae, was estimated by new bone formation. In

fact it is the newly formed bone around the circular environment of the socket.

For this purpose, five fields were analyzed in each histological section and examined by a light microscope (Olympus. CX21FS, Olympus Corporation, Tokyo, Japan) under 10 x objective lenses, then images were obtained with a digital camera (Canon powershot A650 IS; Tokyo, Japan.) and analyzed with Adobe Photoshop 7.0 (San Jose, CA) software. The percentage of newly formed bone rather than studied total area in each field was evaluated and the mean percentage was reported.

### Statistical analysis

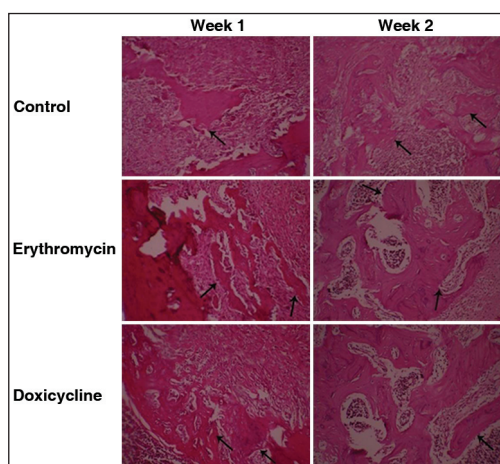
Statistical analysis was done by one-way ANOVA (analysis of variance) test, with the Tukey multiple comparisons test using SPSS version 20. Each value represents the mean  $\pm$  SEM.  $P < 0.05$  was considered as significant difference for all comparisons.

## RESULTS

### Histomorphometric evaluation (New bone formation)

There was significant enhancement in percentage of new bone formation in the first and second weeks [Table 1]. The formation of new bone occurred in all groups.

It has been shown that in the first week new bone formation was significantly higher in EM and DOX groups than the control group without any significant difference between two drug-treated groups, and in the second week DOX had significant increased bone formation than the control group without any difference in EM group than control or DOX groups. In the third week no meaningful difference was observed [Figure 1].



**Figure 1:** Rat alveolar socket one and two weeks after tooth extraction (H and E, magnification  $\times 100$ ). The arrows show the area of new bone formation (NBF) in control, erythromycin and doxycycline groups

## DISCUSSION

Since EM is a safe drug with a less spectrum of action has lower side effects and is more tolerable than DOX,<sup>[20]</sup> we designed this study to first evaluate bone healing effect after administration of these drugs in comparison with control, and secondly compare them to each other. To the best of our knowledge, no animal study has yet been conducted to report the effect of DOX and EM on bone formation after tooth extraction in rats.

Anti-osteoclastogenesis property of EM and DOX is independent of their anti-bacterial action,<sup>[15,16]</sup> so in this study we used subantimicrobial dose of each drug to eliminate the probability of developing resistant by pathologic and opportunistic bacterial species, for example the dosage used for EM is one quarter of that is needed for its anti-microbial effect.<sup>[17]</sup>

In brief, immediately after tooth extraction, the socket is filled with blood clot, which is progressively invaded by fibroblasts originating from periodontal ligament remnants. Then the coagulum is gradually reabsorbed and an immature connective tissue is forming as a result of active proliferation of fibroblasts. So the amount of inflammatory cells and blood vessels decreases and the osteoblasts become evident as a differentiation of the young connective tissue. The osteoblasts are responsible for new bone production during socket healing. The alveolar bone neoformation takes place from the apical and lateral walls toward the center, and the healing process culminates with filling of the dental socket by trabecular bone.<sup>[21,22]</sup>

It has been demonstrated that 14 days after tooth extraction in rats is a time in which maximal bone formation and alveolar volume occurs.<sup>[23]</sup> It has been demonstrated that TCs are effective in preventing excessive angiogenesis and apoptosis and stimulating bone formation.<sup>[24]</sup> In recent several literatures the effect of DOX and EM on RANKL (marker of bone resorption) and OPG (marker of bone formation) gene expression and the osteoclast and osteoblast cells was reported. Lee demonstrated that the presence of DOX in cultures derived from neonatal calvariae, a source of

**Table 1: The mean percentage of new bone formation in dental socket of rats in experimental groups**

Groups	Time points		
	Day 7	Day 14	Day 21
Erythromycin	23.9 $\pm$ 0.63	27.2 $\pm$ 1.6	34.3 $\pm$ 1.5
Doxycycline	24.2 $\pm$ 0.94	29.2 $\pm$ 1.1	33 $\pm$ 1.1
Control	20.1 $\pm$ 1.3	23.9 $\pm$ 2	28.1 $\pm$ 2.1
<i>P</i> -value	0.02	0.048	0.31

Data are mean  $\pm$  SEM, *P*-values calculated by one-way ANOVA and a *P*-value less than 0.05 considered significant

osteoblast precursors, or bone marrow-derived myeloid cells as a source of osteoclast precursors, resulted in increased OPG/RANKL ratio and Ren *et al.* showed that EM suppresses wear debris-induced osteoclastic bone resorption by, at least, down-regulation of the NF-kappa-B signaling pathway.<sup>[17,25]</sup>

In an *in vitro* study with the aim of evaluation of bone physiologic metabolism, both DOX and minocycline increased significantly the proliferation of human bone marrow osteoblastic cells and their long-term use enhanced the number of active osteoblasts, that suggests a potential application in therapeutic approaches aiming to increase bone formation.<sup>[26]</sup>

Ferraz and Mateus used nanohydroxyapatite microspheres as a delivery system for EM, amoxicillin and Augmentin to evaluate their interaction with osteoblasts. They concluded that EM induced osteoblastic cells proliferation higher than others, and also suggested the use of microsphere and EM as a good alternative carrier to enhance bone regeneration while treating periodontal defects.<sup>[27]</sup>

On the other hand, Alakn *et al.* in a pilot study did not find any difference in newly formed bone in the tibial bone defects by administration of DOX in control rats that were injected with an equivalent volume of the vehicle (Citrate buffer) only.<sup>[28]</sup> Olmarker *et al.* showed that 1 week administration of DOX (i.p., 3.0 mg/kg) after laminectomy in rats resulted in better bone healing.<sup>[29]</sup> In another investigations by use of DOX after reflection of full thickness flap surgeries or following applying orthodontic forces bone loss reduced significantly.<sup>[30,31]</sup>

However, it seems to be possible that long-term administration of subantimicrobial doses of DOX and EM may delay healing due to lack of a resorption phase, for example prolonged use of both nonselective and selective NSAIDs (non-selective anti-inflammatory drugs) as anti-inflammatory and anti-osteoclastogenesis drugs can hinder reparational long bone formation in the orthopedic area.<sup>[32]</sup>

The mechanisms for the observed findings have not been studied in detail. Since inflammation is critical for bone healing, the anti-inflammatory properties of DOX and EM may reduce the inflammatory response. Maybe this controversy is due to the balance between growth factors and inflammatory cytokines. It is known that there is a balance between these two groups of substances in the way that they counteract each other's activity.<sup>[33,34]</sup> So the activation of growth factors theoretically may result in increased rate of bone formation.

Further studies are needed to detect the biological mechanisms of action of DOX and EM. Evaluation of the bone healing during tooth extraction somewhat mimics that of occurs during osteointegration after implant insertion. Since accelerating bone formation in early stages of bone healing is of great importance specially in the field of implant dentistry, if confirmed in humans, these drugs seems to be useful in oral surgeries involving the bone tissue, such as dental implants, also due to growing interest in the development of dental implant coating drug delivery systems, examining these drugs locally in the implant dentistry in further studies is suggested.

## CONCLUSION

Due to these findings, it seems that DOX and EM increase new bone formation similarly, and there is no difference between them in induction of bone formation phase in tooth extraction wound. More prolonged researches are needed.

## ACKNOWLEDGEMENTS

This study was also supported by the Dental Research Center, Isfahan University of Medical Sciences. The authors would express their gratitude to Dr. M. Manshaei for animal testing and Mrs. F. Mahmoodi for histotechnical aids.

## REFERENCES

1. Amler MH, Johnson PL, Salman I. Histological and histochemical investigation of human alveolar socket healing in undisturbed extraction wounds. *J Am Dent Assoc* 1960;61:32-44.
2. Devlin H, Sloan P. Early bone healing events in the human extraction socket. *Int J Oral Maxillofac Surg* 2002;31:641-5.
3. Bassetti C, Kallenberger A. Influence of chlorhexidine rinsing on the healing of oral mucosa and osseous lesions. *J Clin Periodontol* 1980;7:443-56.
4. Manolagas SC. Birth and death of bone cells: Basic regulatory mechanisms and implications for the pathogenesis and treatment of osteoporosis. *Endocr Rev* 2000;21:115-37.
5. Liu C, Wu Z, Sun HC. The effect of simvastatin on mRNA expression of transforming growth factor-beta 1, bone morphogenetic protein-2 and vascular endothelial growth factor in tooth extraction socket. *Int J Oral Sci* 2009;1:90-8.
6. Agnihotri R, Gaur S. Chemically modified tetracyclines: Novel therapeutic agents in the management of chronic periodontitis. *Indian J Pharmacol* 2012;44:161-7.
7. Holmes SG, Still K, Buttle DJ, Bishop NJ, Grabowski PS. Chemically modified tetracyclines act through multiple mechanisms directly on osteoclast precursors. *Bone* 2004;35:471-8.
8. Williams S, Wakisaka A, Zeng QQ, Barnes J, Martin G, Wechter WJ, *et al.* Minocycline prevents the decrease in bone mineral density and trabecular bone in ovariectomized aged rats. *Bone* 1996;19:637-44.
9. Golub LM, Ramamurthy NS, Kaneko H, Sasaki T, Rifkin B, McNamara TF. Tetracycline administration prevents diabetes-induced osteopenia in the rat: Initial observations. *Res Commun Chem Pathol Pharmacol* 1990;68:27-40.
10. Bain S, Ramamurthy NS, Impeduglia T, Scolman S, Golub LM, Rubin C. Tetracycline prevents cancellous bone loss and maintains near-normal rates of bone formation in streptozotocin diabetic rats. *Bone* 1997;21:147-53.

11. Aoyagi M, Sasaki T, Ramamurthy NS, Golub LM. Tetracycline/ flurbiprofen combination therapy modulates bone remodeling in ovariectomized rats: Preliminary observations. *Bone* 1996;19:629-35.
12. Sasaki T, Ramamurthy N, Golub LM. Long-term therapy with a new chemically modified tetracycline (CMT-8) inhibits bone loss in femurs of ovariectomized rats. *Adv Dent Res* 1998;12:76-81.
13. Bettany JT, Peet NM, Wolowacz RG, Skerry TM, Grabowski PS. Tetracyclines induce apoptosis in osteoclasts. *Bone* 2000;27:75-80.
14. Shinkai M, Henke MO, Rubin BK. Macrolide antibiotics as immunomodulatory medications: Proposed mechanisms of action. *Pharmacol Ther* 2008;117:393-405.
15. Giamarellos-Bourboulis EJ. Macrolides beyond the conventional antimicrobials: A class of potent immunomodulators. *Int J Antimicrob Agents* 2008;31:12-20.
16. Cervin A. The anti-inflammatory effect of erythromycin and its derivatives, with special reference to nasal polyposis and chronic sinusitis. *Acta Otolaryngol* 2001;121:83-92.
17. Ren W, Li XH, Chen BD, Wooley PH. Erythromycin inhibits wear debris-induced osteoclastogenesis by modulation of murine macrophage NF-kappaB activity. *J Orthop Res* 2004;22:21-9.
18. Ren W, Zhang R, Hawkins M, Shi T, Markel DC. Efficacy of periprosthetic erythromycin delivery for wear debris-induced inflammation and osteolysis. *Inflamm Res* 2010;59:1091-7.
19. Buduneli E, Vardar S, Buduneli N, Berdeli AH, Türko lu O, Ba kesen A, *et al.* Effects of combined systemic administration of low-dose doxycycline and alendronate on endotoxin-induced periodontitis in rats. *J Periodontol* 2004;75:1516-23.
20. Joos AA. Pharmacologic interactions of antibiotics and psychotropic drugs. *Psychiatr Prax* 1998;25:57-60.
21. Carvalho TL, Bombonato KF, Brentegani LG. Histometric analysis of rat alveolar wound healing. *Braz Dent J* 1997;8:9-12.
22. Elsubeihi ES, Heersche JN. Quantitative assessment of post-extraction healing and alveolar ridge remodelling of the mandible in female rats. *Arch Oral Biol* 2004;49:401-12.
23. Iizuka T, Miller SC, Marks SC Jr. Alveolar bone remodeling after tooth extraction in normal and osteopetrotic (ia) rats. *J Oral Pathol Med* 1992;21:150-5.
24. Soory M. A role for non-antimicrobial actions of tetracyclines in combating oxidative stress in periodontal and metabolic diseases: A literature review. *Open Dent J* 2008;2:5-12.
25. Lee L, Liu J, Manuel J, Gorczynski RM. A role for the immunomodulatory molecules CD200 and CD200R in regulating bone formation. *Immunol Lett* 2006;105:150-8.
26. Gomes PS, Fernandes MH. Effect of therapeutic levels of doxycycline and minocycline in the proliferation and differentiation of human bone marrow osteoblastic cells. *Arch Oral Biol* 2007;52:251-9.
27. Ferraz MP, Mateus AY, Sousa JC, Monteiro FJ. Nanohydroxyapatite microspheres as delivery system for antibiotics: Release kinetics, antimicrobial activity, and interaction with osteoblasts. *J Biomed Mater Res A* 2007;81:994-1004.
28. Alkan A, Erdem E, Günhan O, Karasu C. Histomorphometric evaluation of the effect of doxycycline on the healing of bone defects in experimental diabetes mellitus: A pilot study. *J Oral Maxillofac Surg* 2002;60:898-904.
29. Olmarker K. Reduction of adhesion formation and promotion of wound healing after laminectomy by pharmacological inhibition of pro-inflammatory cytokines: An experimental study in the rat. *Eur Spine J* 2010;19:2117-21.
30. Cummings GR, Torabinejad M. Effect of systemic doxycycline on alveolar bone loss after periradicular surgery. *J Endod* 2000;26:325-7.
31. Mavragani M, Brudvik P, Selvig KA. Orthodontically induced root and alveolar bone resorption: Inhibitory effect of systemic doxycycline administration in rats. *Eur J Orthod* 2005;27:215-25.
32. Lamano-Carvalho TL. Effect of conventional and COX-2 selective non-steroidal anti-inflammatory drugs on bone healing. *Acta Ortop Bras* 2007;15:166-8.
33. Sugarman BJ, Lewis GD, Eessalu TE, Aggarwal BB, Shepard HM. Effects of growth factors on the antiproliferative activity of tumor necrosis factors. *Cancer Res* 1987;47:780-6.
34. Waetzig GH, Rosenstiel P, Arlt A, Till A, Bräutigam K, Schäfer H, *et al.* Soluble tumor necrosis factor (TNF) receptor-1 induces apoptosis via reverse TNF signaling and autocrine transforming growth factor-beta1. *FASEB J* 2005;19:91-3.

**Source of Support:** Nil, **Conflict of Interest:** None declared.