

# Study of C-MYC amplification and expression in Iranian gastric cancer samples using CISH and IHC methods

Malihea Khaleghian, Issa Jahanzad<sup>1</sup>, Abbas Shakoory, Farid Azmoudeh Ardalan<sup>1</sup>, Cyrus Azimi

Departments of Medical Genetics and <sup>1</sup>Pathology, Cancer Institute of Iran, Tehran University of Medical Sciences, Tehran, Iran

## Abstract

**Background:** Gastric cancer is the fourth most frequent malignancy and the second cause of cancer-related mortality worldwide. It has been suggested that in gastric carcinogenesis, the C-MYC gene has an important function. The objective of this study is to establish the preference of Chromogenic *in situ* hybridization (CISH) and Immunohistochemistry (IHC) in the diagnosis and prognosis of gastric cancer.

**Materials and Methods:** Samples comprised of 50 randomly selected patients of whom 40 were male and 10 female. To evaluate the MYC copy number and its protein expression, CISH and IHC analyses were performed for 50 gastric adenocarcinomas, in Iran.

**Results:** The location of the tumor in 64% of the patients was the fundus, and in 72% of patients, the tumors were of a diffuse type; 22 samples showed no amplification, and 28 samples were with amplification. MYC immunoreactivity was observed in 13 samples. Twelve samples showed both MYC amplification and MYC immunoreactivity. In addition, among the 28 CISH+ samples, 12 samples had positive signals for IHC and 16 samples had negative signals for IHC. A majority of the IHC-negative patients had no amplification, but only one patient with IHC positive had no amplification.

**Conclusion:** Our conclusion was that for the management and treatment of gastric cancer, and for special attention of clinicians, for prognosis and tumor progression, the CISH was a better and more feasible test than IHC, in regard to the sensitivity and specificity.

**Key Words:** Cancer, Chromogenic *in situ* hybridization, gastric adenocarcinoma, gene amplification, Immunohistochemistry, MYC gene, MYC oncogene, MYC protein

## Address for correspondences:

Dr. Cyrus Azimi, Department of Medical Genetics, Cancer Institute of Iran, Tehran University of Medical Sciences, Keshavarz Blvd., Tehran - 1419733141, Iran. E-mail: [azimicyrus@sina.tums.ac.ir](mailto:azimicyrus@sina.tums.ac.ir)

Received: 26.06.2014, Accepted: 03.09.2014

## INTRODUCTION

Stomach cancer ranks as the fourth most frequent malignancy and the second cause of cancer-related

mortality worldwide. However, it has been seen that the incidence of this cancer has decreased during the past half-a-century.<sup>[1]</sup> The reason for the notable decline in stomach cancer occurrence is unknown, but the application of better sanitation may play an important role. The other factors may be improvement in the quality of nutrition worldwide as well as public knowledge about *Helicobacter pylori* infection.<sup>[2]</sup>

Some studies from various provinces of Iran showed high, intermediate, and low incidence of gastric cancer from different parts of Iran.<sup>[3,4]</sup> Unfortunately, patients with gastric cancers have either no symptoms or

Access this article online	
Quick Response Code:	Website: <a href="http://www.advbiores.net">www.advbiores.net</a>
	DOI: 10.4103/2277-9175.157841

Copyright: © 2015 Khaleghian. This is an open-access article distributed under the terms of the Creative Commons Attribution License, which permits unrestricted use, distribution, and reproduction in any medium, provided the original author and source are credited.

**How to cite this article:** Khaleghian M, Jahanzad I, Shakoory A, Ardalan FA, Azimi C. Study of C-MYC amplification and expression in Iranian gastric cancer samples using CISH and IHC methods. *Adv Biomed Res* 2015;4:116.

nonspecific symptoms, at early stages of the disease, and by the time the symptoms occur, the cancer has often reached an advanced stage. Therefore, the outcomes of gastric cancers are often poor, with a five-year survival rate of less than 10%, largely because of the late surgical resection in most of the patients. For this reason, cancer causes over 700,000 deaths worldwide per year.<sup>[5,6]</sup>

Gastric carcinogenesis is a big dilemma, because it has a multifactorial and multistage complex.<sup>[7]</sup> It has been suggested that in gastric carcinogenesis, the *C-MYC* gene has an important function. *C-MYC* is a well-known proto-oncogene that is connected with the etiology of 20% of the cancers in humans.<sup>[8]</sup> The function of the *C-MYC* gene in the causation of all cancers, particularly gastric cancer, is still obscure. However, a few decades ago, it was discovered that this gene is the cellular homolog of the retroviral *v-myc* oncogene.<sup>[9]</sup> The *C-MYC* gene is on the long arm of chromosome 8 (8q24.1), with three exons, which encode nuclear phosphoproteins, called p64 and p67. The proportion of p67 is more when compared to p64. They are also recognized as MYC-1 and MYC-2.<sup>[10]</sup> *C-MYC* is a regulator gene that codes for a transcription factor. The C-MYC protein belongs to the MYC family of transcription factors, which also includes N-MYC and L-MYC proteins; their function lies in cell proliferation, differentiation, and apoptosis, as well as in the causation of cancers.<sup>[11]</sup> One of the functions of the C-MYC protein is to control some of the downstream genes.<sup>[12]</sup> The relationship between deregulation and overexpression of the *C-MYC* gene and stomach cancer has been discussed by some authors.<sup>[13]</sup> Some researchers from Brazil compared *C-MYC* gene amplification between two groups of patients with gastric adenocarcinoma, one in early stage and another in the late stage, with metastases, and showed that the level of amplification was higher in the latter group.<sup>[14]</sup> They confirmed the suggestion of two other previous reports as well.<sup>[15]</sup> The results of a study from Brazil show that the expression of the C-MYC protein would exist in both types of intestinal and diffuse gastric adenocarcinoma.<sup>[16]</sup> On the contrary, some *investigations on the C-MYC* protein and mRNA in gastric cancer showed overexpression, more in patients in the early stages than in the late stages and metastasis.<sup>[17]</sup> However, many researchers believed that there would be a relationship between C-MYC protein overexpression and tumor invasion, and patients with a high expression would have poor prognosis.<sup>[18]</sup> This expression would gradually increase in the different stages of stomach lesions, from chronic active gastritis, gastric ulcer, and non-classic proliferation to progressive stomach cancer.<sup>[19]</sup>

In this study, evaluation of the *MYC* copy number and its protein expression was performed using Chromogenic *In Situ* hybridization (CISH) and Immunohistochemistry (IHC) analyses, among 50 randomly selected Iranian patients with gastric adenocarcinomas. The objective of this study was to establish the preference of CISH and IHC in the diagnosis and prognosis of gastric cancer.

## MATERIALS AND METHODS

### Clinical samples

This study included 50 gastric adenocarcinoma paraffin-embedded blocks and 25 corresponding non-neoplastic adjacent gastric tissues as the control samples. All patients had undergone primary surgical resection at the Cancer Institute Hospital, Tehran University of Medical Sciences. None of these patients had received new adjuvant therapy (neither chemotherapy nor radiotherapy). Patients' approval for conducting any laboratory/research tests was secured according to local arrangements by the Ethics Committee, DNA Bank, Cancer Institute of Iran. This investigation was performed with the patients' consent, which allowed molecular cytogenetic research to be carried out on specimens obtained during surgical resection. Gastric tumors were classified according to Lauren<sup>[20]</sup> and tumors were staged using the standard criteria of tumor, nodes, and metastasis (TNM) staging.<sup>[21]</sup> The clinicopathological features are shown in Table 1.

### MYC immunohistochemistry

Immunohistochemistry (IHC) staining was performed according to Calcagno, *et al.*<sup>[22]</sup> There were two steps in this protocol. A citrate buffer (MERCK-Germany) was prepared before the test, for performing the Antigen Retrieval Protocol, and phosphate buffered saline (PBS) buffer (MERCK-Germany) for slide washing. Tissue sections were de-paraffinized, rehydrated, incubated in hydrogen peroxide, and Antigen Retrieval was performed by microwave heating (Botan-Iran). The tissue was incubated in a digestive enzyme (pepsin enzyme-Invitrogen, USA), for five minutes and then Super Block (Scy Tek-USA) was applied. Primary rabbit monoclonal antibody against MYC (dilution 1:100-1:200 ready to use PME 415 AA Biocare Medical, USA) was applied on the slides and incubated overnight in a 4°C humidity chamber. Ultra Tek Anti-polyvalent as a secondary antibody was applied for detection, and Ultra Tek HRP was used (ScyTek Laboratories, UltraTek HRP, USA). Diaminobenzidine (DAB) (Scy Tek, USA) was treated as the chromogen and hematoxylin as the counterstain. Regardless of the strength of stain, any color of the nucleus (with/without staining of the

**Table 1: Clinicopathological features of patients according to the type of gastric cancers (diffuse and intestinal)**

Variable	Type of gastric cancer			
	Diffuse		Intestinal	
	N (%)	P	N (%)	P
Age (in years)				
<60	18 (50)	1.000	5 (35.7)	0.285
60	18 (50)	0.001	9 (64.3)	0.109
Sex				
Male	30 (83.3)		10 (71.4)	
Female	6 (16.7)		4 (28.6)	
Location of tumor		0.001		0.008
Fundus	22 (61.1)		10 (71.4)	
Pylorus	3 (8.3)		0 (0)	
Esophagus	2 (5.6)		3 (21.4)	
Cardia	2 (5.6)		0 (0)	
Lesser curvature	3 (8.3)		0 (0)	
Corpus-body	1 (2.8)		0 (0)	
Antrum	2 (5.6)		1 (7.1)	
Missing	1 (2.8)		-	
Grade		0.337		0.257
Well-differentiated	11 (30.6)		2 (14.3)	
Moderately differentiated	8 (22.2)		7 (50)	
Poorly differentiated	15 (41.7)		5 (35.7)	
Missing	2 (5.6)		-	
Necrosis		0.007		0.472
Yes	7 (19.4)		3 (21.4)	
No	4 (11.1)		3 (21.4)	
N/A	17 (47.2)		6 (42.9)	
Missing	8 (22.2)		2 (14.3)	
Stage		0.499		0.294
I	11 (30.4)		1 (7.1)	
II	11 (30.6)		6 (42.9)	
III	7 (19.4)		3 (21.4)	
IV	1 (2.8)		4 (28.6)	
Missing	0 (0)		0 (0)	
CISH amplification		0.023		0.607
<2 Signals	16 (44.4)		6 (42.9)	
2-4 Signals	9 (25)		3 (21.4)	
4-6 Signals	3 (8.3)		0 (0)	
>6 Signals	8 (22.2)		5 (35.7)	
IHC		0.003		0.109
Positive	9 (25)		4 (28.6)	
Negative	27 (75)		10 (71.4)	

CISH: Chromogenic *in situ* hybridization, IHC: Immunohistochemistry

cytoplasm) was assumed as positive. If 10% or more of the tumor cells were positive for MYC protein, the patient was considered as MYC+.

### MYC amplification

Chromogenic *In Situ* hybridization (CISH) was performed on 3- $\mu$ m-thick archival formalin-fixed paraffin-embedded tissue sections. In brief, these sections were de-paraffinized and incubated in a pretreatment buffer, in a water bath (Memmert-Germany) to at least 85°C for 30 minutes, with a ZytoDot CISH

Implementation Kit (Germany). Enzymatic digestion was conducted by application of one drop of the digestion enzyme to the slides (10 minutes at room temperature). The CISH probe *C-MYC* was applied to the slides that were covered with 22  $\times$  22 mm coverslips (10  $\mu$ l probe mixture/slide). The slides were denatured with a hotplate (95°C) for five minutes, and hybridization was conducted overnight at 37°C. After hybridization, the slides were washed with 0.5  $\times$  standard saline citrate for five minutes, at 75°C, followed by three additional washes with PBS/0.2% Tween 20, at room temperature. The *C-MYC* was detected with sequential incubations, with anti-digoxigenin and DAB, according to the manufacturer's instructions. The tissue sections were then lightly counterstained with hematoxylin and embedded. CISH were evaluated with a Leitz microscope (Germany) equipped with  $\times$  40 and  $\times$  100 objectives and by using 10  $\times$  22 wide-field oculars. The unaltered gene copy number was defined as one to two signals per nucleus. Low-level and moderate amplification was defined as two-to-four and two-to-six signals per nucleus, respectively, in >50% of the cancer cells and was also indicated in cases in which a small gene copy cluster was detected. *C-MYC* high amplification was defined when a large gene copy cluster in >50% of the carcinoma cells or numerous (>6) separate gene copies were observed.<sup>[18]</sup> Images were captured with a digital Nikon camera (Japan). All the slides of patients were confirmed for diagnosis and were checked for CISH and IHC by one senior pathologist (I.J.).

### Statistical analysis

The statistical analysis was conducted using the SPSS statistical software package for Windows (version 18-Amazon K UK). To assess the degree of agreement between the CISH and IHC tests, the Kappa statistic was used. The data were categorized into two Tables. The categorical data in Table 1 was analyzed using the Chi-square test. Variables in Table 2, with two rows were tested using the Mann-Whitney test, and variables with more than two rows were tested using the Kruskal-Wallis. For determining the association between CISH and IHC, the Kappa test and the Spearman correlation coefficient were used. Interpretation of the Kappa test was as follows: Poor agreement (<0.20), Fair agreement (0.20 to 0.40), Moderate agreement (0.40 to 0.60), Good agreement (0.60 to 0.80), and Very good agreement (0.80 to 1.00). A  $P < 0.05$  was considered as significant in all tests.<sup>[23]</sup>

### RESULTS

This study comprised of 50 Iranian patients with gastric adenocarcinomas. Forty patients (80%) were

**Table 2: Clinicopathological features of patients according to C-MYC amplification (CISH) and C-MYC expression (IHC)**

Variable	IHC			CISH				
	Positive (n=13) N (%)	Negative (n=37) N (%)	sig	No (n=22) N (%)	Low (n=12) N (%)	Moderate (n=3) N (%)	High (n=13)	
							N (%)	sig
Age								
<60	6 (46.2)	17 (45.9)	0.771	10 (45.5)	7 (58.3)	0 (0)	3 (23.1)	0.508
>60	7 (53.8)	20 (54.1)		12 (54.5)	5 (41.7)	3 (100)	10 (76.9)	
Sex								
Male	12 (92.3)	28 (75.7)		17 (77.3)	9 (75)	3 (100)	11 (84.6)	
Female	1 (7.7)	9 (24.3)		5 (22.7)	3 (25)	0 (0)	2 (15.4)	
Location of tumor			0.134					0.883
Fundus	7 (53.8)	25 (67.6)		12 (54.5)	11 (91.7)	3 (100)	6 (46.2)	
Pylorus	1 (7.7)	2 (5.4)		2 (9.1)	0	0 (0)	1 (7.7)	
Esophagus	1 (7.7)	4 (10.8)		3 (13.6)	0	0 (0)	2 (15.4)	
Cardia	0 (0)	2 (5.4)		1 (4.5)	0	0 (0)	1 (7.7)	
Lesser Curvature	1 (7.7)	2 (5.4)		1 (4.5)	1 (8.3)	0 (0)	1 (7.7)	
Corpus-body	0 (0)	1 (2.7)		1 (4.5)	0 (0)	0 (0)	0 (0)	
Antrum	3 (23.1)	0 (0)		1 (4.5)	0 (0)	0 (0)	2 (15.4)	
Missing	-	1 (100)		1 (4.5)	0	0 (0)	0	
Grade			0.011					0.008
Well-differentiated	1 (7.7)	12 (32.4)		9 (40.9)	2 (16.7)	0 (0)	2 (15.4)	
Moderately differentiated	2 (15.4)	13 (35.1)		9 (40.9)	3 (25)	0 (0)	3 (23.1)	
Poorly differentiated	10 (76.9)	10 (27)		3 (13.6)	7 (58.3)	3 (100)	7 (53.8)	
Missing	-	2 (5.4)		1 (4.5)	0	0 (0)	1 (7.7)	
Necrose			0.221					0.025
Yes	2 (15.4)	8 (21.6)		7 (31.8)	10 (83.3)	0 (0)	1 (7.7)	
No	4 (30.8)	3 (8.1)		1 (4.5)	1 (8.3)	1 (33.3)	4 (30.8)	
N/A	6 (46.2)	17 (45.9)		10 (45.5)	0 (0)	2 (66.7)	4 (30.8)	
Missing	1 (7.7)	9 (24.3)		4 (18.2)	1 (8.3)	0 (0)	4 (30.8)	
Stage								
I	3 (23.1)	4 (10.8)	0.139	3 (13.6)	2 (16.7)	0 (0)	2 (15.4)	0.958
II	5 (38.5)	12 (32.4)		8 (36.4)	3 (25)	1 (33.3)	5 (38.5)	
III	5 (38.5)	9 (24.3)		6 (27.3)	2 (16.7)	2 (66.7)	4 (30.8)	
IV	0 (0)	11 (29.7)		5 (22.7)	4 (33.3)	0 (0)	2 (15.4)	
Missing	0 (0)	1 (2.7)		0 (0)	1 (8.3)	0 (0)	0 (0)	
Type of gastric cancer			0.798					0.687
Diffuse	9 (69.2)	27 (73)		16 (72.7)	9 (75)	2 (66.7)	8 (61.5)	
Intestinal	4 (30.8)	10 (27)		6 (27.3)	3 (25)	1 (33.3)	5 (38.5)	

males and 10 cases (20%) were females, with an average age of 59.26 years. Evaluation of the MYC copy number and its protein expression, CISH, and IHC analyses were performed among them.

### Clinical results

The clinicopathological features are shown in Table 1. The location of the tumor in 64% of the patients was the fundus [Figure 1]. Thirty-six patients (72%) had diffuse gastric cancer and 14 cases (28%) had the intestinal type [Table 1]. The average tumor size was 5.99 cm, in the patients. According to Table 1, the tumor location, necrosis, vascular invasion, perineural invasion, CISH, and IHC tests among the diffuse type, and tumor location and vascular invasion in the intestinal type, showed a significant difference. Our investigation revealed that there was no significant relation between the age, grade, and type of gastric

cancer. Diffuse gastric cancer occurred significantly more in men than women, but not in the intestinal type.

### Chromogenic *in situ* hybridization results

Table 2 shows the comparison between CISH and IHC. This result revealed that there was a significant difference between grades and also presence/absence of necrosis in the CISH test. Our study revealed no correlation between the ages, gender, stages, and type of gastric cancer and the CISH test. Our data also showed that CISH + patients were more frequent when compared to IHC + patients [Figure 2]. Table 3 shows the correlation between CISH and IHC. Different amplifications of the CISH test are shown in Figure 3. According to our the CISH data, 22 samples were with no amplification and 13 samples were with low amplification. Two samples were with

moderate amplification and 13 samples were with high amplification. Among 28 samples with CISH+, 13 samples were observed with low amplification, two samples with moderate amplification, and 13 samples with high amplification [Table 3].

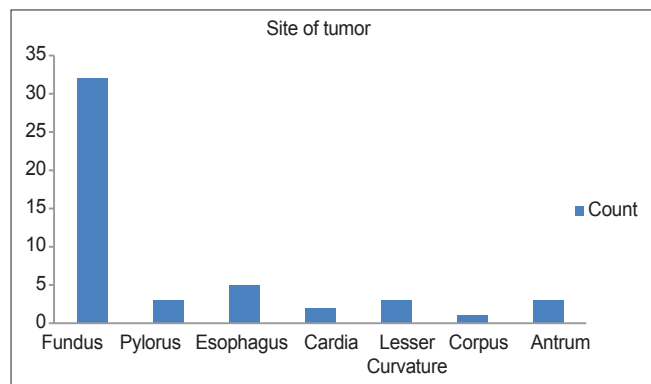
### Immunohistochemistry results

Table 2 shows a significant difference between grades in IHC, but with no difference between the stages. IHC positive and negative results are shown in Figure 4. MYC immunoreactivity was observed in 13 samples.

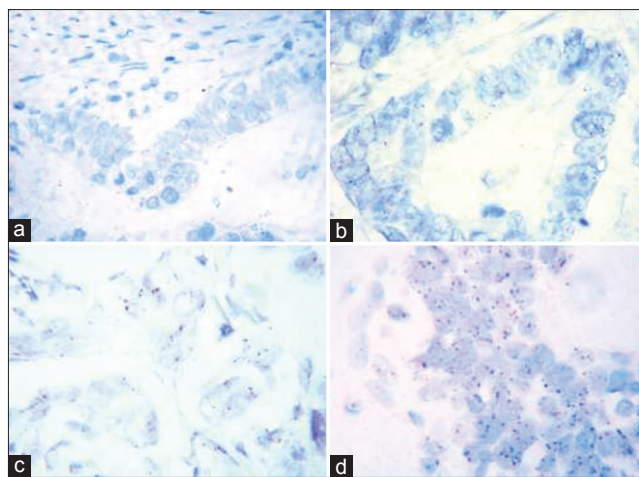
**Table 3: Comparison between CISH and IHC in the detection of C-MYC amplification in fifty gastric cancers**

CISH IHC	Positive	Negative	Total
Positive	12	1	13
Negative	16	21	37
Total	28	22	50

Kappa: Measure of agreement=0.357, Percent=35.7%, P=0.002, statistically significant difference from zero



**Figure 1:** Site of tumors among patients

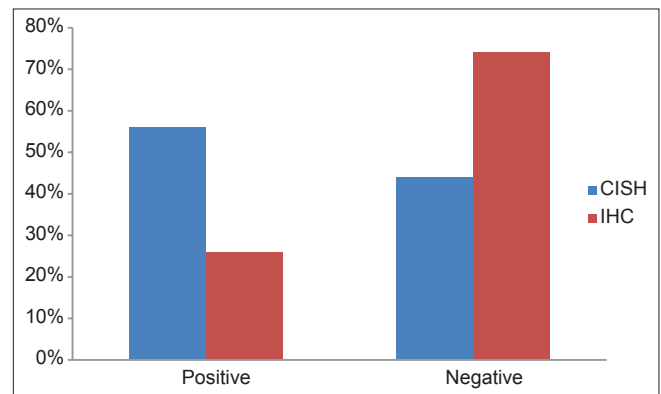


**Figure 3:** Chromogenic *in situ* hybridization (CISH) of C-MYC amplification. (a) Non-amplified gastric tumor (No amplification) (b and c) A typical C-MYC amplification appears as a positive cluster of gene copies in gastric cancer (low and moderate amplification) (d) Amplification of C-MYC appears as large copy gene clusters in the majority of the nuclei of gastric cancer cells (original magnification, ×500)

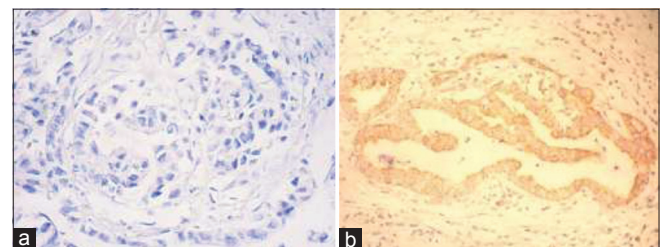
In 12 samples, both MYC amplification and MYC immunoreactivity were observed. Twenty-one samples had no amplification and were negative for IHC. Also, among 28 samples, 12 samples had positive signals for IHC and 16 samples had negative signals for IHC. The majority of patients with IHC negative had no amplification, but only one patient with IHC positive had no amplification. Normal cells also were IHC negative [Table 3]. There were four groups in our patients. The first group revealed both CISH+ and IHC+ (24%). The second revealed CISH+ and IHC- (32%). The third revealed CISH- and IHC+ (2%). The fourth group showed CISH- and IHC- (42%). In these four groups, kappa was 0.357, which showed that the agreement between CISH and IHC was fair [Table 3].

### DISCUSSION

Fifty patients with gastric cancer consisting of 40 males and 10 females were studied. This data revealed a male: female ratio of 4:1, with an average age of 59.26 years. This ratio was reported as 2:1 in another research and the majority of the patients were older than 55 years, which was in agreement with our data.<sup>[24]</sup> In our study, with seven subgroups for location of the tumor — in the majority of our patients the tumors were found in the fundi. However, de Souza *et al.*,<sup>[24]</sup> who studied gastric cancer among 125 samples,



**Figure 2:** Comparison of positive and negative CISH and IHC among patients



**Figure 4:** Immunohistochemical staining for C-MYC. (a) Gastric adenocarcinoma shows IHC Negative (b) Gastric adenocarcinoma shows IHC Positive

with only cardia and noncardia as the two subgroups, found 58.4% in the noncardia, which was in agreement with our result. Also most of our patients (72%) were of the diffuse type, but some authors<sup>[16,24,25]</sup> reported the intestinal type more than the diffuse type. The best explanation that could be given for this difference was that samples in the de Souza *et al.* study were from Brazil, which was a high-risk area, but our samples were from Tehran, which was in the low-risk area. It had already been shown that intestinal type of gastric adenocarcinoma was more frequent than the diffuse type in high-risk countries.<sup>[26]</sup>

The MYC changes were usually because of gene amplification.<sup>[27]</sup> In the present investigation, low amplification with two-to-four signals, moderate amplification with four-to-six signals, and high amplification with more than six signals were detected. In our study, only 56% of the samples were with amplification. However, in the previous studies, all the samples had amplification. Therefore, our study did not confirm the results of the previous studies.<sup>[16,22]</sup> The probable reason could be that all of our samples were collected from different stages, mostly the late stage, but in the previous two studies, the cases were gathered only from the early stage. In addition, our study showed that *C-MYC* amplification in the diffuse type was more frequent than in the intestinal type, which did not agree with some previous studies.<sup>[16,22]</sup> It was suggested that MYC overexpression had a range from 15.6 to 100% in the early stage of gastric cancer.<sup>[28]</sup> In our investigation, only 26% showed MYC immunoreactivity (IHC+) in both types, and 74% had no expression. This was less than in the previous studies.<sup>[24]</sup> The probable reason could be that all our samples were randomly selected from different stages.

The results of CISH were varied in different grades, but were similar in different stages. The results of CISH were also similar in the two types of stomach cancer. A study from China revealed that any relation between *MYC* amplification and the clinicopathological characteristics (grade, stage, lymph node metastasis, tumor location) in gastric cancer was related to ethnicity.<sup>[29]</sup> Our results showed that the ethnicity of the afflicted population could lead to clinicopathological features in the stomach cancer subsets.<sup>[30]</sup> To determine the association between CISH and IHC testing, the Spearman correlation coefficient was applied. The correlation coefficient was -0.434 with the level of  $P = 0.002$ , indicating that these two tests were related. In this investigation, 56% of samples were positive for CISH, but only 26% of them were positive for IHC. Therefore, it might be concluded that CISH is a better test than IHC. The probable reasons would be as follows:

### Causes of methodology

In comparison to CISH, IHC is less expensive, requires minimal equipment, and is a quicker and easier test. Nevertheless, the IHC test can be influenced by a group of variables, including tissue fixation, processing, methods of antigen retrieval, kind of primary antibodies, and detection systems.<sup>[31]</sup> Therefore, the scoring system for IHC depends on observers and their interpretations. CISH is another alternative for Fluorescence *In Situ* Hybridization (FISH). Tissue preparation and probe hybridization protocols in both FISH and CISH are the same. CISH is a new method, and the correlation of CISH and FISH has not yet been fully proved in the clinical setting.<sup>[32]</sup>

### Causes of low expression in IHC

Onoda *et al.*<sup>[17]</sup> showed that the C-MYC protein and *C-MYC* mRNA were overexpressed even at the the primary stages of stomach cancer. As *C-MYC* DNA were not always amplified in gastric cancer, they suggested that the overexpression may be originating from the abnormal genetic signal, from mRNA to protein. In this direction, we also observed a case with CISH - and IHC+ and numerous samples that were CISH- and no expression. The C-MYC protein was functionally active in the early stages of the gastric cancer process.<sup>[18]</sup>

Twenty-four percent of our samples revealed both positive CISH and IHC. Although we observed *C-MYC* amplification (CISH-) and IHC+ in only one patient, it seemed that it could be an artifact. Thirty-two percent of our patients showed *C-MYC* amplification (CISH+), but the protein was not expressed (IHC-) [Table 3]. The possible explanation would be that a mechanism could be degrading the protein or probably the mRNA.<sup>[33]</sup>

Some researchers suggested that MYC inactivation could suppress tumors in animals, indicating that MYC could be a molecular target in the treatment of cancers.<sup>[34]</sup> Overall, the C-MYC status was not related to the time of relapse or death, but low levels of *C-MYC* amplification indicated a subset of patients who significantly manifested an increase in disease-free survival, and also they would have a longer survival in response to adjuvant therapy with 5-fluorouracil plus levamisole.<sup>[35]</sup>

### CONCLUSION

Our conclusion was that for the management and treatment of gastric cancer, and for the special attention of clinicians for prognosis and tumor progression, the CISH technique was a better and more feasible test for *CMYC* than IHC, with regard to sensitivity and specificity.

## REFERENCES

1. Ferlay J, Soerjomataram I, Ervik M, Dikshit R, Eser S, Mathers C, *et al.* GLOBOCAN 2012 v1.0. Cancer Incidence and Mortality Worldwide: IARC Cancer Base No. 11. Lyon, France: International Agency for Research on Cancer; 2014.
2. Matsuzaka M, Fukuda S, Takahashi I, Shimaya S, Oyama T, Yaegaki M, *et al.* The decreasing burden of gastric cancer in Japan. *Tohoku J Exp Med* 2007;212:207-19.
3. Mohagheghi MA, Mosavi-Jarrahi A, Malekzadeh R, Parkin M. Cancer incidence in Tehran metropolis: The first report from the Tehran population-based cancer registry, 1998-2001. *Arch Iran Med* 2009;12:15-23.
4. Somi MH, Farhang S, Mirinezhad SK, Naghashi S, Seif-Farshad M, Golzari M. Cancer in East Azerbaijan, Iran: Results of a population-based cancer registry. *Asian Pac J Cancer Prev* 2008;9:327-30.
5. Nardone G. Review article: Molecular basis of gastric carcinogenesis. *Aliment Pharmacol Ther* 2003;17(Suppl 2):75-81.
6. Orditura M, Galizia G, Sforza V, Gambardella V, Fabozzi A, Laterza MM, *et al.* Treatment of gastric cancer. *World J Gastroenterol* 2014;20:1635-49.
7. González CA, Sala N, Capellá G. Genetic susceptibility and gastric cancer risk. *Int J Cancer* 2002;100:249-60.
8. Dang CV. c-Myc target genes involved in cell growth, apoptosis, and metabolism. *Mol Cell Biol* 1999;19:1-11.
9. Sheiness D, Fanshier L, Bishop JM. Identification of nucleotide sequences which may encode the oncogenic capacity of avian retrovirus MC29. *J Virol* 1978;28:600-10.
10. Battey J, Moulding C, Taub R, Murphy W, Stewart T, Potter H, *et al.* The human c-myc oncogene: Structural consequences of translocation into the IgH locus in Burkitt lymphoma. *Cell* 1983;34:779-87.
11. Cole MD, McMahon SB. The Myc oncoprotein: A critical evaluation of transactivation and target gene regulation. *Oncogene* 1999;18:2916-24.
12. Dang CV, Resar LM, Emison E, Kim S, Li Q, Prescott JE, *et al.* Function of the c-Myc oncogenic transcription factor. *Exp Cell Res* 1999;253:63-77.
13. Milne AN, Sitarz R, Carvalho R, Carneiro F, Offerhaus GJ. Early onset gastric cancer: On the road to unraveling gastric carcinogenesis. *Curr Mol Med* 2007;7:15-28.
14. Calcagno DQ, Leal MF, Taken SS, Assumpção PP, Demachki S, Smith Mde A, *et al.* Aneuploidy of chromosome 8 and C-MYC amplification in individuals from northern Brazil with gastric adenocarcinoma. *Anticancer Res* 2005;25:4069-74.
15. Yang GF, Deng CS, Xiong YY, Gong LL, Wang BC, Luo J. Expression of nuclear factor-kappa B and target genes in gastric precancerous lesions and adenocarcinoma: Association with *Helicobacter pylori* cagA(+) infection. *World J Gastroenterol* 2004;10:491-6.
16. Calcagno DQ, Leal MF, Seabra AD, Khayat AS, Chen ES, Demachki S, *et al.* Interrelationship between chromosome 8 aneuploidy, C-MYC amplification and increased expression in individuals from northern Brazil with gastric adenocarcinoma. *World J Gastroenterol* 2006;12:6207-11.
17. Onoda N, Maeda K, Chung YS, Yano Y, Matsui-Yuasa I, Otani S, *et al.* Overexpression of c-myc messenger RNA in primary and metastatic lesions of carcinoma of the stomach. *J Am Coll Surg* 1996;182:55-9.
18. Costa Raiol LC, Figueira Silva EC, Mendes da Fonseca D, Leal MF, Guimarães AC, Calcagno DQ, *et al.* Interrelationship between MYC gene numerical aberrations and protein expression in individuals from northern Brazil with early gastric adenocarcinoma. *Cancer Genet Cytogenet* 2008;181:31-5.
19. Xu AG, Li SG, Liu JH, Gan AH. Function of apoptosis and expression of the proteins Bcl-2, p53 and C-myc in the development of gastric cancer. *Apoptosis* 2001;17:6.
20. Lauren P. The two histological main types of gastric carcinoma: Diffuse and so-called intestinal-type carcinoma. An attempt at a histo-clinical classification. *Acta Pathol Microbiol Scand* 1965;64:31-49.
21. Sobin LH, Gospodarowicz MK, Wittekind C, editors. TNM Classification of Malignant Tumours. New York: John Wiley and Sons; 2011.
22. Calcagno DQ, Guimarães AC, Leal MF, Seabra AD, Khayat AS, Pontes TB, *et al.* MYC insertions in diffuse-type gastric adenocarcinoma. *Anticancer Res* 2009;29:2479-83.
23. Altman DG. Practical statistics for medical research. London: CRC Press; 1990.
24. de Souza CR, Leal MF, Calcagno DQ, Costa Sozinho EK, Borges Bdo N, Montenegro RC, *et al.* MYC deregulation in gastric cancer and its clinicopathological implications. *PLoS One* 2013;8:e64420.
25. Chang MS, Uozaki H, Chong JM, Ushiku T, Sakuma K, Ishikawa S, *et al.* CpG island methylation status in gastric carcinoma with and without infection of Epstein-Barr virus. *Clin Cancer Res* 2006;12:2995-3002.
26. The International Agency for Research on Cancer. Organization WH. Hamilton SR, Aaltonen LA, editors. Pathology and Genetics of Tumours of the Digestive System. Lyon: IARC Press; 2000. p.
27. Meyer N, Penn LZ. Reflecting on 25 years with MYC. *Nat Rev Cancer* 2008;8:976-90.
28. Calcagno DQ, Leal MF, Assumpção PP, Smith MA, Burbano RR. MYC and gastric adenocarcinoma carcinogenesis. *World J Gastroenterol* 2008;14:5962-2.
29. Liu X, Cai H, Huang H, Long Z, Shi Y, Wang Y. The prognostic significance of apoptosis-related biological markers in Chinese gastric cancer patients. *PLoS One* 2011;6:e29670.
30. Shah MA, Ajani JA. Gastric cancer-an enigmatic and heterogeneous disease. *JAMA* 2010;303:1753-4.
31. Seidal T, Balaton AJ, Battifora H. Interpretation and quantification of immunostains. *Am J Surg Pathol* 2001;25:1204-7.
32. Park DI, Yun JW, Park JH, Oh SJ, Kim HJ, Cho YK, *et al.* HER-2/neu amplification is an independent prognostic factor in gastric cancer. *Dig Dis Sci* 2006;51:1371-9.
33. Shan Z, Shakoori A, Bodaghi S, Goldsmith P, Jin J, Wiest JS. TUSC1, a putative tumor suppressor gene, reduces tumor cell growth *in vitro* and tumor growth *in vivo*. *PLoS One* 2013;8:e66114.
34. Calcagno DQ, Freitas VM, Leal MF, de Souza CR, Demachki S, Montenegro R, *et al.* MYC, FBXW7 and TP53 copy number variation and expression in gastric cancer. *BMC Gastroenterol* 2013;13:141.
35. Augenlicht LH, Wadler S, Corner G, Richards C, Ryan L, Multani AS, *et al.* Low-level c-myc amplification in human colonic carcinoma cell lines and tumors: A frequent, p53-independent mutation associated with improved outcome in a randomized multi-institutional trial. *Cancer Res* 1997;57:1769-75.

Source of Support: Nil, Conflict of Interest: None declared.