

## Case Report

# Aorto-pulmonary fistula accompanied by root abscess and destruction of native aortic valve caused by brucellosis

Feridoun Sabzi, Reza Faraji

Department of Cardiovascular Surgery, Imam Ali Heart Center, Kermanshah University of Medical Sciences, Kermanshah, Iran

### Abstract

Brucellosis endocarditis is a zoonosis infection of cardiovascular system with world-wide distribution, which is endemic in many provinces of the Iran. The present report describes an exceptional case of fistulization between the aorta and pulmonary artery by *Brucella melitensis* in a 34-year-old patient. He presented with the complaints of fever and weight loss and congestive heart failure. He was strongly positive for Brucellosis by serological reaction and conventional microbiological cultures from blood and valve tissue were positive. Echocardiography revealed aortic root abscess, cavity formation in aortic ring, large vegetation and native aortic valve destruction with aortic regurgitation and fistula from non-coronary sinus to pulmonary artery and pericarditis. The patient underwent open heart surgery with aortic valve replacement and transpulmonary fistula repair. The patient had uneven full postoperative recovery and with good general condition discharged to home in 16<sup>th</sup> days of hospitalization.

**Key Words:** Aorto-pulmonary fistula, brucellosis endocarditis, cardiovascular

### Address for correspondence:

Dr. Reza Faraji, Imam Ali Hospital, Shahid Beheshti Blvd., Kermanshah University of Medical Sciences, Kermanshah, Iran. E-mail: rezafaraji60@yahoo.com

**Received:** 26.09.2013, **Accepted:** 21.01.2014

### INTRODUCTION

Brucellosis is one of the most important diseases in rural areas of Iran including the Kermanshah province. Any organ can be involved by Brucellosis, that included head and neck, brain, eye, nasopharynx, ear, thorax, plura, mediastinum, pericardium, gastrointestinal tract, spleen, liver skeletal system, skin and urinary system.<sup>[1]</sup> Patients with severe and persistent headache and mixed-type hearing loss following *Brucella* infection is presented in report of Baykal *et al.*<sup>[2]</sup> cardiac involvement is a rare event in the course of Brucellosis, but the rate could be

higher than currently estimated. In endemic regions, Brucellosis should be considered as a causative agent in patients with cardiac symptoms as reported by Uluğ and Can-Uluğ.<sup>[3]</sup> To the best of our knowledge, this patient is the only reported case of aorto pulmonary fistula caused by native aortic valve brucella endocarditis.

### CASE REPORT

The present case report is about a 32-year-old man who was referred to our hospital from rural area with malaise, fatigue, weight loss and fever on examination, the patient was found to be breathless at rest, with pedal edema, tender hepatomegaly, pulsatile precordium, jugular venous pressure raised and murmurs of mitral regurgitation and aortic regurgitation and a 3 month history of rigors. Chest roentgenogram showed bilateral infiltrates consistent with pulmonary edema and bilateral pleural effusions. Over the next few hours rapid deterioration with respiratory failure secondary to pulmonary edema led to him being intubated.

Access this article online	
Quick Response Code:	Website: <a href="http://www.advbiores.net">www.advbiores.net</a>
	DOI: 10.4103/2277-9175.161561

Copyright: © 2015 Sabzi. This is an open-access article distributed under the terms of the Creative Commons Attribution License, which permits unrestricted use, distribution, and reproduction in any medium, provided the original author and source are credited.

**How to cite this article:** Sabzi F, Faraji R. Aorto-pulmonary fistula accompanied by root abscess and destruction of native aortic valve caused by brucellosis. *Adv Biomed Res* 2015;4:146.

Laboratory investigations revealed low hemoglobin 9 g/dL and normal aspartate aminotransferase (19 U/L; upper normal limit [UNL] 40 U/L), alanine aminotransferase (30 U/L; UNL: 40 U/L) and gamma-glutamyl transpeptidase (34 U/L; UNL 37 U/L). Electrocardiography was normal with sinus rhythm, and radiography revealed normal cardiac silhouette. Serum agglutination tests were positive (titer > 1:2000) and enzyme-linked immunosorbent assay tests for anti-*Brucella* immunoglobulin G and immunoglobulin M antibodies were strongly positive (124 U/mL and 35.5 U/mL; UNL 30 U/mL and 20 U/mL, respectively). In addition, *Brucella melitensis* were isolated from two of three consecutive blood cultures. Trans-esophageal echocardiography was performed to investigate for the possible presence of *Brucella*-related complication of endocarditis because of our patient's diastolic and systolic heart murmur, positive blood cultures. The transesophageal echocardiogram also noted a 2 × 1.5 cm posterior aortic root abscess and a 1 mm defect between the main pulmonary artery and the ascending aorta. The echocardiography showed native aortic valve endocarditis, large vegetation; aortic ring cavity and abscess [Figures 1 and 2] also, there was moderate pericardial effusion without signs of cardiac tamponade. Dilatation of left ventricular cavity with a preserved ejection fraction of 55%, three cusped aortic valve, a large mobile vegetation on right and left aortic cusp [Figure 3]. Our patient was given oral doxycycline 100 mg twice daily plus oral Rifampicin 900 mg once daily for 7 days, with intramuscular streptomycin 1 g once daily for the first 3 weeks. On the 10<sup>th</sup> day of treatment surgery was performed with aortic valve replacement (no. 21, Carbomedix). We performed aortic annular skeletonization by dissecting all infectious and necrotic tissue within the abscess cavity and the fistula between the ventriculoarterial junction and the Sino tubular junction. The completely resected annular area was covered with a fresh autologous pericardial patch that was sutured firmly to fibrous tissue, for a secure proximal anastomosis as described by Keleş *et al.*<sup>[4]</sup> Reconstruction performed using a fresh pericardial patch and aortic valve replacement with a Carbomedix 21 prosthetic valve. The antibiotic regimen was continued after the operation and blood cultures after 1 month of operation were sterile. The patient was followed-up for 2 months with oral antibiotics and warfarin. After the procedure warfarin was started. The patient is still being followed-up in a healthy condition after the 3<sup>th</sup> month since diagnosis and treatment with oral antibiotics and warfarin when last seen, 12 months after starting therapy; our patient was well with no sign of relapse. Careful medical literature searching revealed that our case is the only reported case of aorto pulmonary fistula following *Brucella* aortic endocarditis.

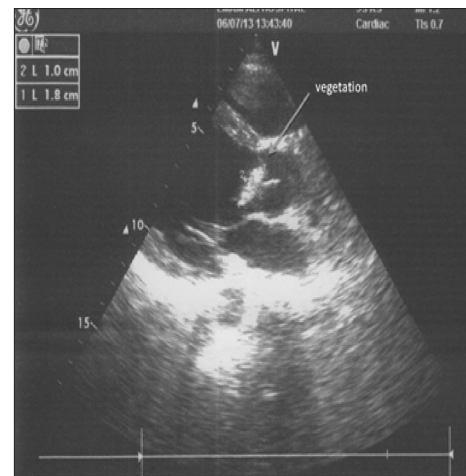

Figure 1: Vegetation and fistula formation

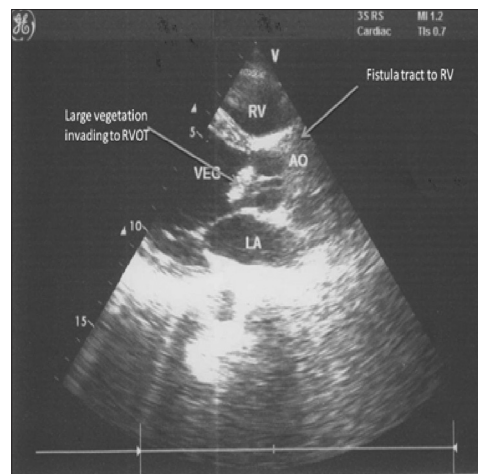


Figure 2: Large vegetation on aortic cusp and ring

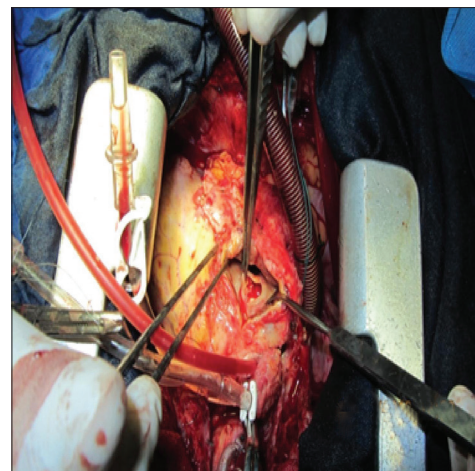


Figure 3: Complete aortic valve destruction caused by *Brucellosis*

## DISCUSSION

The rural people usually keep cattle for milk production and meat and viscera consumption, but intestine and skin exported for tannery manufacture.

Humans are likely to become infected through consumption of raw or non-pasteurized milk or soft cheese made of fresh unboiled milk.<sup>[5]</sup> Brucellosis has generalized and systemic symptoms and almost every organ of the human body can be affected by *Brucella*. Despite this, the incidence of cardiovascular complications in Brucellosis, such as endocarditis, myocarditis or pericarditis, is reported to be as low of 1% of cases with even fewer cases of myocarditis or pericarditis in the absence of concomitant endocarditis being reported.<sup>[6]</sup> Kaya report one case of asymptomatic pericarditis caused by Brucellosis in the absence of concomitant endocarditis. These unusual features of Brucellosis may be underestimated components of the disease. In Inan *et al.* study,<sup>[7]</sup> the aortic valve was involved in 19 patients, mitral valve in 7 patients and both valves in 5 but no case of aorto-pulmonary fistula was reported. After serological confirmation of BE, antibiotic therapy was maintained. Twenty-five of the patients received rifampicine, doxycycline and cotrimoxazole; 2 of them received a combination of rifampicine, streptomycin and doxycycline; and 4 of them received rifampicine, tetracycline and cotrimoxazole. We describe a case of *Brucella* endocarditis involving the aortic valve suspected in front of the clinical data and the results of serology, confirmed by the culture of the native valves. The aortic valve was affected more than the mitral valve. Affected mitral valves had rheumatic disease, whereas only 57% of the aortic valves had underlying pathology. Isolation of *Brucella* spp. was possible in 20% of the patients.<sup>[8]</sup> Mortality rate was 30% in Arslan *et al.* study<sup>[9]</sup> 20% of the patients were on medical follow-up without disease progression and with clinical stability, 60% of patients were on a combination therapy with a tetracycline group, a Rifampicin, and a third-generation cephalosporin. Patients who took this combination and underwent aortic valve replacement had good clinical results with a mortality rate of 20%. The 30% of patients were on a combination therapy with a tetracycline group, rifampicin, and an aminoglycoside group. Mortality rate with this combination was 33%, although the success rate was 67% was reported by Arslan *et al.*<sup>[9]</sup> Five cases of *Brucella* infective endocarditis are described by Raju *et al.*<sup>[10]</sup> that involving a native aortic valve, two native mitral valves, a mitral valve bio prosthesis and a ventricular septal defect patch. The diagnosis of *Brucella* infective endocarditis was established from the clinical features, with a high *Brucella* serologic titre in each case. Blood and tissue cultures were positive in four of five patients. Two-dimensional echocardiograms demonstrated moderately large vegetation's on the three affected native valves and the patch and also revealed the development of vegetation on the mitral bio prosthesis

as the disease progressed. All the patients were successfully treated by combined surgical and medical therapy, the latter consisting of cotrimoxazole, tetracycline, and streptomycin/gentamicin for 6 weeks; the affected valves and the ventricular septal defect patch were all replaced. There were no periannular abscess and there has been no fistula to cardiac cavity. Kaya *et al.*<sup>[11]</sup> have reported four cases of brucellosis, the diagnosis was suspected by the patient's history of systemic Brucellosis in two cases and established by the culture of native valve material in the third. All the patients underwent surgery for non-control of the infections, one patient died in immediately postoperative period by acute cardiac failure. For the other patients, there were no early or late mortality and no recurrence after a follow-up of respectively 6 and 84 months. The diagnostic of *Brucella* endocarditis needed a very high degree of clinical suspicion, it requires an early management valve replacement is in the majority of cases, followed by adequate and prolonged antibiotic treatment. Sempe *et al.*<sup>[12]</sup> in their study have reported a case of *B. melitensis* endocarditis of a bicuspid aortic valve which caused rapid progression of the hemodynamic signs of aortic stenosis and was associated with a para-aortic abscess and a pericardial effusion. Surgery resulted in correction of the hemodynamic abnormalities and cured the infection, however fistula in periaortic area was not found. Careful medical literature did not revealed any such complication caused by native aortic valve endocarditis.

## CONCLUSION

*Brucella* endocarditis complicated by aorto-pulmonary fistula is a rare form of infective aortic endocarditis and its diagnostic rate and surgical therapy practices have increased due to the availability of echocardiography. *Brucella* endocarditis with aorto-pulmonary fistula has a high mortality if not treated. Control of the infection with pre-operative antibiotic therapy and immediate surgery have gratifying outcomes.

## REFERENCES

1. Guven T, Ugurlu K, Ergonul O, Celikbas AK, Gok SE, Comoglu S, *et al.* Neurobrucellosis: Clinical and diagnostic features. *Clin Infect Dis* 2013;56:1407-12.
2. Baykal T, Baygatalp F, Senel K, Levent A, Erdal A, Ugur M, *et al.* Spastic paraparesis and sensorineural hearing loss in a patient with neurobrucellosis. *J Back Musculoskelet Rehabil* 2012;25:157-9.
3. Uluğ M, Can-Uluğ N. Pulmonary involvement in brucellosis. *Can J Infect Dis Med Microbiol* 2012;23:e13-5.
4. Keleş C, Bozbuğa N, Şişmanoğlu M, Güler M, Erdoğan HB, Akinci E, *et al.* Surgical treatment of *Brucella* endocarditis. *Ann Thorac Surg* 2001;71:1160-3.
5. Havas L. Problems and new developments in the treatment of acute and chronic brucellosis in man. *Acta Trop* 1980;37:281-6.

Sabzi and Faraji: Aorto-pulmonary fistula accompanied by root abscess

6. Mantur BG, Biradar MS, Bidri RC, Mulimani MS, Veerappa, Kariholu P, *et al.* Protean clinical manifestations and diagnostic challenges of human brucellosis in adults: 16 years' experience in an endemic area. *J Med Microbiol* 2006;55:897-903.
7. Inan MB, Eyileten ZB, Ozcinar E, Yazicioglu L, Sirlak M, Eryilmaz S, *et al.* Native valve *Brucella* endocarditis. *Clin Cardiol* 2010;33:E20-6.
8. Ruiz J, Lorente I, Pérez J, Simarro E, Martínez-Campos L. Diagnosis of brucellosis by using blood cultures. *J Clin Microbiol* 1997;35:2417-8.
9. Arslan H, Korkmaz ME, Kart H, Gül C. Management of *Brucella* endocarditis of a prosthetic valve. *J Infect* 1998;37:70-1.
10. Raju IT, Solanki R, Patnaik AN, Barik RC, Kumari NR, Gulati AS. *Brucella* endocarditis: A series of five case reports. *Indian Heart J* 2013;65:72-7.
11. Kaya S, Eskazan AE, Elaldi N. *Brucellar* pericarditis: A report of four cases and review of the literature. *Int J Infect Dis* 2013;17:e428-32.
12. Sempe S, Koch M, Douard H, Fontan F, Clerc M, Broustet JP. *Brucella* endocarditis of bicuspid aortic valve. Surgical treatment with successful result. *Arch Mal Coeur Vaiss* 1991;84:587-91.

**Source of Support:** Nil, **Conflict of Interest:** None declared.