

Case Report

Nocardial brain abscess in a patient with pulmonary alveolar proteinosis

Kiana Shirani, Asger Nyborg Poulsen¹, Atousa Hakamifard²

Department of Infectious Diseases, Acquired Immunodeficiency Research Center, ²Department of Infectious Diseases, Nosocomial Infection Research Center, Isfahan University of Medical Sciences, Isfahan, Iran, ¹Faculty of Health and Medical Sciences, University of Copenhagen, Copenhagen, Denmark

Abstract

Brain abscesses caused by *Nocardia* are rare but have a very high mortality and specific requirements of antibiotic treatment. Nocardial brain abscesses are mainly found in patients with predisposing conditions such as pulmonary alveolar proteinosis (PAP), a disease associated with chronic exposure to silica dust. We present a case of multiple nocardial brain abscesses in a man with PAP probably due to long-term occupational exposure to silica dust. Conclusively, in patients presenting brain abscesses and a history of chronic exposure to silica dust, PAP and opportunistic nocardial infection should always be considered as possible diagnoses.

Key Words: Brain abscess, immunosuppression, *Nocardia*, pulmonary alveolar proteinosis, silica dust

Address for correspondence:

Dr. Kiana Shirani, P.O. Box - 791, Al-Zahra Hospital, Softe Avenue, Isfahan, Iran. E-mail: kianashirani@med.mui.ac.ir

Received: 20.09.2014, Accepted: 19.10.2014

INTRODUCTION

The *Nocardia* bacteria are a branching, filamentous, gram-positive, and weakly acid-fast bacteria classified as aerobic actinomycetes. They are ubiquitous in the environment, but are mostly found in dry and warm climates, and can cause a wide variety of diseases.^[1,2]

Nocardial brain abscesses are a rare clinical finding accounting for only around 2% of the total number of brain abscesses found and usually occurring in patients with predisposing underlying conditions. These brain abscesses mostly originate from a primary

focus such as the lungs, skin, abdomen, urinary tract, or elsewhere in the body.^[1] A significantly higher-mortality rate of 66% has been found in multiple nocardial brain abscesses compared to the mortality rate of 10% seen in other bacterial brain abscesses.^[3,4]

Although there is an increasing number of reports of nocardial infections in immunocompetent patients, it mainly occurs in immunocompromised patients. This includes patients suffering from malignancies, acquired immune deficiency syndrome (AIDS), uremia, malnutrition, diabetes mellitus, or patients receiving immunosuppressive drugs. Due to the recent increase in the number of immunocompromised patients, nocardial infections have become a significant opportunistic infection in the last two decades.^[5]

There has, furthermore, been found an association between nocardial infections and pulmonary alveolar proteinosis (PAP).^[1,5,6] PAP is a rare lung disease caused by an accumulation of pulmonary surfactant

Access this article online	
Quick Response Code:	Website: www.advbiores.net
	DOI: 10.4103/2277-9175.164004

Copyright: © 2015 Shirani. This is an open-access article distributed under the terms of the Creative Commons Attribution License, which permits unrestricted use, distribution, and reproduction in any medium, provided the original author and source are credited.

How to cite this article: Shirani K, Poulsen AN, Hakamifard A. Nocardial brain abscess in a patient with pulmonary alveolar proteinosis. *Adv Biomed Res* 2015;4:185.

due to a decrease in the macrophage-mediated catabolism. This decrease may be the result of an incomplete differentiation in macrophages, which increases susceptibility to infections such as nocardial infections.^[7,8] Among the numerous suggested etiologies for PAP, such as lung infections and hematologic malignancies, studies have shown a correlation between PAP and a chronic exposure to silica dust.^[9]

We report a case of multiple nocardial brain abscesses in an immunocompetent patient with PAP probably due to chronic occupational exposure to silica dust.

CASE REPORT

A 42-year-old man without any previously known medical history contacted his general physician due to complaints of cough and dyspnea. He was predisposed toward pulmonary illness through daily smoking of tobacco and inhaled illicit drugs of poor quality. Furthermore, the patient had a chronic occupational exposure to concrete and limestone, two known sources of silica dust.

He was prescribed general antibiotics, but was admitted at Shariati Hospital, Isfahan 3 months later due to the persistence of his symptoms. During admission, x-ray and computerized tomography (CT)-scan of the thorax were performed, which were suggestive of pneumonia; then the patient was represcribed antibiotics and discharged.

One month later the patient's condition worsened, now presenting with fever (39.8°C), daily headache, and vomiting. Brain magnetic resonance imaging (MRI)-scan with contrast was performed, which revealed multiple bilateral brain abscesses [Figure 1a]

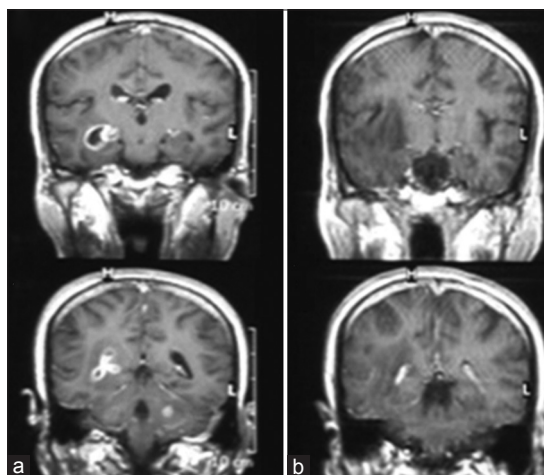


Figure 1: (a) Brain MRI before starting treatment: Multiple bilateral round lesions in both hemispheres with ring enhancement (b) Brain MRI after 6 months of treatment: A few hypersignal areas in right parietotemporal and left frontal lobes without central necrosis

causing his immediate transfer to Arad Hospital, Tehran for stereotactic brain biopsy. The biopsy material was cultivated and examined by smear microscopy, which indicated long 1 μm -wide, branching, filamentous, gram-positive elements suggestive of *Nocardia*, or less likely fungi, which at that point could not be confirmed by culture. The patient was referred to Alzahra Hospital, Isfahan and the treatment was expanded to consist of vancomycin, meropenem, trimetoprim/sulfamethoxazol (TMP/SMX), amphotericin B, and dexamethasone.

In the search for a primary focus of infection, and with cancer as the differential diagnose, the patient was systematically examined. At first an echocardiogram following blood cultivation of three independent blood samples was performed in order to rule out endocarditis, all of which turned out negative. The chest CT-scan was inconclusive showing diffuse alveolar infiltrations [Figure 2]. Further smear microscopy and culture were performed on sputum and bronchoalveolar lavage (BAL) but they showed negative for *Actinomyces*, *Nocardia*, *Mycobacterium Tuberculosis*, and other bacteria and fungi. Cytopathology analysis for malignancy was also performed but turned out negative. The abdomen and pelvic were assessed using CT-scan with contrast and ultrasonography but revealed no abnormalities. Neither did the urine analysis nor did the culture show any sign of infection. When assessing the patient's immunocompetence the patient was tested negative three times for HIV type 1 and 2, and a complete blood and bone marrow analysis was performed including CD8+ and CD4+ T-cell count, which revealed no immunodeficiency, malignancy, or sign of tuberculosis. Finally, an open lung biopsy was performed. This revealed PAP, but was negative for malignancies, *Actinomyces*, *Nocardia*, *Mycobacterium Tuberculosis*

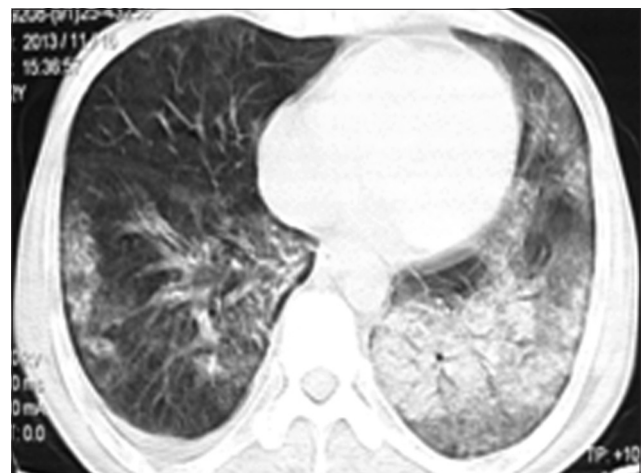


Figure 2: Diffuse alveolar infiltration in left lung. Right lung shows necrotic lesion in peripheral area and mild-pleural effusion

and other bacteria, confirming the negative results of sputum and BAL analysis.

3 weeks after the brain biopsy the result of the brain abscess culture was completed and turned out positive for *Nocardia Asteroides*, confirming the results of the smear. Based on these results, a 2 months intravenous drug regime was started consisting of TMP/SMX, meropenem, and amikacine. Neurosurgical intervention was also considered due to the large size of the abscesses, but was not found to be possible because of the high number of abscesses and the profound location. Dexamethasone was also prescribed and it showed a beneficial effect on the headache but its tapering was complicated due to the return of headaches. After 3 weeks of treatment the fever began to diminish, and after 2 months the patient was discharged with a body temperature of 37.2°C and a reduction in the frequency of vomiting and headaches from a daily basis to a weekly basis. The treatment was continued with oral TMP/SMX antibiotics.

Four months after discharge the patient returned to the hospital with newly-emerged neurological and psychological symptoms such as diplopia, headaches, and breakdowns despite continuous oral antibiotic treatment and brain MRI-scan with contrast that on the contrary was showing diminished cerebral abscesses [Figure 1b]. Because of the worsening condition and the increasing neurological character of the symptoms, the patient was discontinued treatment at the infectious disease department and transferred to the neurology department for further treatment.

DISCUSSION

The low number of cases with nocardial brain abscesses, the silent progression of symptoms, and the paucity of laboratory findings make nocardial infections a continuing challenge to physicians worldwide.^[10]

The *Nocardia* bacteria enter the body by either direct inoculation of contaminated soil into skin lesions or inhalation of *Nocardia*-containing dust particles causing lung diseases such as pneumonia and lung abscesses. From the skin and, more often, the lungs the nocardial infection can disseminate hematogenously throughout the body, with a predilection for the central nervous system (CNS) accounting for around 45% of all cases of disseminated nocardiosis. The initial pulmonary infection is later able to clear spontaneously obscuring its primary location.^[6,10] In our case we suspected the brain abscesses to originate from a primary lung infection due to the original lung symptoms and predisposing factors described. The

results of our cultivation and smear microscopy from the lungs were both negative, indicating a spontaneous recovery of the lungs.

The symptoms of nocardial brain abscesses vary greatly and may present themselves as classic brain abscesses, mimic tumors, or in other cases develop over months or even years gradually presenting neurological symptoms but without any systemic sign of infection. The neurological symptoms seen vary from subtle focal neurological impairments to severe changes in behavior and personality.^[3,6] We report neurological symptoms such as vomiting and headaches and psychological symptoms such as depression and breakdowns.

Nocardial infection is often seen in immuno compromised patients or patients with other predisposing factors including locally impaired pulmonary defenses, like seen in PAP. PAP has been shown to be a predisposing factor for nocardial infections by Punatar *et al.* in a review of 75 cases of PAP.^[11] Furthermore, a chronic exposure to silica dust was shown by Bonella *et al.* in a cohort of 70 patients to be a strong inducing factor of PAP, and that tobacco smoking complicates the condition significantly.^[9] Silica is mostly found in nature as quartz, but is also used in construction materials such as limestone and concrete.^[12,13] The patient in the present study was a tobacco smoker with an occupational chronic exposure to silica dust through his work with concrete and limestone. This we suspect to be the cause of the patient's PAP and the predisposing factor for his nocardial infection.

In MRI scans, nocardial brain abscesses are usually shown as characteristic hyperenhanced ring lesions and may be surrounded by edematous changes. As seen in Figure 1a, both these characteristics were present. Further, a diagnostic biopsy should always be performed in order to make smear microscopy and culture, which in our case showed the bacteria *Nocardia asteroides*.^[3,7]

The medical gold standard treatment for nocardial infections is sulfonamide drugs, with a TMP/SMX combination being the preferred choice among most physicians. For disseminated nocardial infections, such as the CNS infection seen in our case, an empirical three-drug combination therapy should be started including a sulfonamide, amikacin, and either carbapenem or cephalosporin. Because of a high relapse rate and the resistant nature of *Nocardia* brain abscesses, antibiotic treatment was done aggressively and continued for 12 months.^[3,10] A 30% mortality rate has been shown after medical treatment by Mamelak *et al.*^[4] A combination with surgical intervention is

possible but was in our case avoided because of the profound and multiple locations of the abscesses.

Conclusively, in patients presenting brain abscesses and a history of chronic exposure to silica dust, PAP and opportunistic nocardial infection should always be considered as possible diagnoses.

REFERENCES

1. Menkü A, Kurtsoy A, Tucer B, Yildiz O, Akdemir H. Nocardia brain abscess mimicking brain tumour in immunocompetent patients: Report of two cases and review of the literature. *Acta Neurochir (Wien)* 2004;146:411-4.
2. Kennedy KJ, Chung KH, Bowden FJ, Mews PJ, Pik JH, Fuller JW, *et al.* A cluster of nocardial brain abscesses. *Surg Neurol* 2007;68:43-9.
3. Lin YJ, Yang KY, Ho JT, Lee TC, Wang HC, Su FW. Nocardial brain abscess. *J Clin Neurosci* 2010;17:250-3.
4. Mamelak AN, Obana WG, Flaherty JF, Rosenblum ML. Nocardial brain abscess: Treatment strategies and factors influencing outcome. *Neurosurgery* 1994;35:622-31.
5. Kilincer C, Hamamcioglu MK, Simsek O, Hicdonmez T, Aydoslu B, Tansel O, *et al.* Nocardial brain abscess: Review of clinical management. *J Clin Neurosci* 2006;13:481-5.
6. Lerner PI. Nocardiosis. *Clin Infect Dis* 1996;22:891-905.
7. Alavi Darazam I, Shamaei M, Mobarhan M, Ghasemi S, Tabarsi P, Motavasseli M, *et al.* Nocardiosis: Risk factors, clinical characteristics and outcome. *Iran Red Crescent Med J* 2013;15:436-9.
8. Lerner PI. Nocardiosis, STATE-OF-THE-ART. *Oxford Journals* 1996;22:891-905.
9. Bonella F, Bauer PC, Griesse M, Ohshimo S, Guzman J, Costabel U. Pulmonary alveolar proteinosis: New insights from a single-center cohort of 70 patients. *Respir Med* 2011;105:1908-16.
10. Sorerell TC, Mitchell DH, Iredell JR, Chen SC. Nocardia species. In: Mandell GL, Bennett JE, Dolin R, editors. *Mandell, Douglas, and Bennett's Principles and practice of infectious disease*. 7th ed. Philadelphia: Churchill Livingstone; 2010. p. 3199-207.
11. Punatar AD, Kusne S, Blair JE, Seville MT, Vikram HR. Opportunistic infections in patients with pulmonary alveolar proteinosis. *J Infect* 2012;65:173-9.
12. Healy CB, Coggins MA, Van Tongeren M, MacCalman L, McGowan P. Determinants of respirable crystalline silica exposure among stoneworkers involved in stone restoration work. *Ann Occup Hyg* 2014;58:6-18.
13. Meijer E, Kromhout H, Heederik D. Respiratory effects of exposure to low levels of concrete dust containing crystalline silica. *Am J Ind Med* 2001;40:133-40.

Source of Support: Nil, Conflict of Interest: None declared.