

Neurovascular Structures at Risk During Surgical Access to Trigeminal Ganglion and Meckel's Cave – An Anatomical Study

Prashant Chaware¹, Venkatasurya Kumar¹, Ankit Srivastava¹, Sumit Raj², Bertha A. D. Rathinam¹

¹Department of Anatomy, All India Institute of Medical Sciences, Bhopal, Madhya Pradesh, India, ²Department of Neurosurgery, All India Institute of Medical Sciences, Bhopal, Madhya Pradesh, India

Abstract

Background: It is difficult to approach the Trigeminal Ganglion (TG) and Meckel's cave (MC) during surgeries. Therefore, the exact knowledge of the relationship of surgical landmarks to related anatomical structures is vital to reduce the associated postoperative morbidity. The aim of the present study was to enhance the knowledge of the surgical anatomy of structures that are present in the conduit of all surgical approaches to TG and MC, their distances from surrounding neurovascular structures, and their variations.

Material and Methods: The study was carried out on 40 embalmed cadavers (Eight Female) of the anatomy department of a teaching hospital in Central India. Meticulous dissection of cranial fossae was done to locate TG, MC, and related anatomical structures. All distances from TG and MC were measured using an electronic digital calliper.

Results: Length, width, and thickness of TG were 15.39 mm, 4.39 mm, and 2.54 mm, respectively. The distance from zygomatic arch, the lateral end of the petrous ridge, arcuate eminence, foramen ovale, and foramen spinosum to MC was 26.10 mm and 37.94 mm, 16.46 mm, 4.54 mm, and 11.23 mm, respectively. The sixth, fourth, and third cranial nerves were 6.26 mm, 4.94 mm, and 2.53 mm from MC, respectively. The MC was 42.72 mm and 33.87 mm anteromedial from posterior and anterior limits of the sigmoid sinus.

Conclusion: Findings of the present study will aid surgical planning and decide the approach to TG and MC and avoid surgical complications.

Keywords: Anatomic landmarks, neurosurgical procedures, trigeminal ganglion

Address for correspondence: Dr. Bertha A. D. Rathinam, Department of Anatomy, All India Institute of Medical Sciences, Bhopal, Madhya Pradesh, India.

E-mail: bertharathinam@gmail.com

Submitted: 19-Oct-2020; **Revised:** 11-Apr-2021; **Accepted:** 14-Feb-2022; **Published:** 21-Mar-2023

INTRODUCTION

The trigeminal Ganglion (TG) is a sensory ganglion of the trigeminal nerve and is situated in an impression above the apex of the petrous part of the temporal bone just outside the posterior part of the lateral wall of the cavernous sinus. It is semilunar in shape with convexity directed forwards and laterally. The ganglion and initial portion of its branches are located within a dural pouch known as Meckel's cave (MC) which extends forward as ballooning of meningeal layer of dura mater from posterior cranial to middle cranial fossae below the lateral attached margin of tentorium cerebelli. The ophthalmic, maxillary, and sensory parts of mandibular nerves are the branches arising from the convex

margin of the ganglion.^[1,2] The paired trigeminal ganglion (TG), also called the semilunar or Gasserian ganglion, is distinctive among primary afferent ganglia structurally and functionally.^[3] The trigeminal nerve thus formed by the afferents of the ganglion enter the brain at the level of the pons.^[4]

Trigeminal neuralgia is characterized by episodic severe facial pain along with the distribution of the trigeminal nerve and its branches.^[5] The prevalence of trigeminal neuralgia is 0.015%.^[6] The estimated annual incidence of this condition in India is 12.6/100,000 persons/year, increases with age and is higher in women than men.^[7]

This is an open access journal, and articles are distributed under the terms of the Creative Commons Attribution-NonCommercial-ShareAlike 4.0 License, which allows others to remix, tweak, and build upon the work non-commercially, as long as appropriate credit is given and the new creations are licensed under the identical terms.

For reprints contact: WKHLRPMedknow_reprints@wolterskluwer.com

How to cite this article: Chaware P, Kumar V, Srivastava A, Raj S, Rathinam BA. Neurovascular structures at risk during surgical access to trigeminal ganglion and meckel's cave – An anatomical study. *Adv Biomed Res* 2023;12:62.

Access this article online	
Quick Response Code: 	Website: www.advbiores.net
	DOI: 10.4103/abr.abr_261_20

In relation with TG, trigeminal neuromas and meningiomas are most common,^[8,9] whereas tumors arising from MC are rare and represent not more than 0.5% of all intracranial tumors.^[10] Surgical access to TG and MC is challenging as they are surrounded by important anatomical structures including internal carotid and middle meningeal blood vessels, oculomotor, trochlear, and abducent nerves.^[1,2] There are different surgical pathways to reach MC and TG like anterolateral, lateral, posterolateral and along such pathways, various approaches such as subtemporal, transtemporal, infralabyrinthine, translabyrinthine, infracochlear, anterior petrosectomy and retrosigmoid suprameatal, etc., are used by surgeons.^[8-12] The preference of approach varies from case to case depending on the location of tumor and the expertise of the surgeon.

TG and MC have been extensively studied radiologically,^[10,13-16] but there are very few anatomical studies.^[17-20] Most of the radiological as well as anatomical studies included few parameters related to some surgical corridors. The primary objective of the current study was to add to the knowledge of the neurovascular structures that exist along the routes of the surgical pathways and the distances from surgical landmarks. Results of the study will alert the clinicians to avoid injuries of important neurovascular structures in the path of various approaches.

MATERIALS AND METHODS

The study was carried out in the Department of Anatomy in a teaching hospital in Central India after due institutional ethical clearance (LOP/2015/IM 0020, dated 10 August 2015). Forty cadaveric heads fixed in 10% formaldehyde were included in the study. Out of the total 80 trigeminal ganglia studied, 40 belonged to the right side, and 16 were from female cadavers. The ages ranged from 55 to 85 years. Meticulous dissection of cranial fossae was done to preserve all the neurovascular structures and MC as per the instructions given in Cunningham's manual of practical anatomy.^[21] The anatomical relationship of the TG, MC, and relevant structures were noted. The dimensions of TG: Maximum antero posterior length of the TG (A), Thickness of the TG (B), and Maximum mediolateral width of the TG (C) were recorded. The distances of the following anatomical landmarks from TG and MC were measured: Distance from Medial surface of the posterior root of the zygoma to MC (D), Distance from Lateral end of the petrous ridge along its superior border to MC (E), Distance from Arcuate eminence to MC (F), Distance from Superior orbital fissure (SOF) to MC (G), Distance from Foramen ovale (FO) to MC (H), Distance from Foramen rotundum (FR) to MC (I), Distance from Foramen spinosum (FS) to MC (J), Distance from MC to the trochlear nerve (K), Distance from MC to oculomotor nerve (L), Distance from MC to abducens nerve (M), Distance from the middle point of the anterior lip of the facial nerve hiatus to MC (N), Distance from posterior limit of the sigmoid sinus to MC (O), distance from anterior limit of the sigmoid sinus to MC (P) [Figures 1 and 2].

An electronic digital calliper with a measuring range of 0–150 mm, resolution of 0.01 mm, accuracy ± 0.02 mm of linear capacity measuring system was used for all measurements. All the measurements were carried out by two observers to minimize errors.

Statistical analysis

R software (R Core Team (2019) was used for the statistical analysis. (R: A language and environment for statistical computing. R Foundation for Statistical Computing, Vienna, Austria. R package version. 3.3. [https://CRAN.R-project.org/package = gtsu](https://CRAN.R-project.org/package=gtsu)). Numerical variables were compared by using an unpaired t-test, and *P*-value less than 0.05 was considered statistically significant.

RESULTS

The TG covered by MC was found to lie in a shallow depression at the apex of the petrous temporal bone. The parameters A to P were measured in all 80 specimens. Most parameters of both sexes and right and left sides did not show any significant variation [Table 1]. except, the intracranial length of the ophthalmic nerve which was significantly shorter in the females (*P*-value 0.038, Table 2).

The structure that was closest to MC inferiorly was the internal carotid artery, often being separated by only the endosteal layer of the dura mater. Rarely, a thin bony lamina separated the two [Figure 2]. The other structures related to TG and MC were cavernous sinus anteriorly, superior petrosal sinus superiorly, the apex of petrous temporal bone posteriorly, endosteal dura of middle cranial fossa inferiorly.

The TG was 15.39 mm long, 2.54 mm thick, and 4.39 mm wide. MC was at a distance of 26.10 mm from the medial surface of the posterior root of the zygoma and 37.94 mm from the lateral end of the petrous ridge along its superior border. The mean distance of arcuate eminence to MC was 16.46 mm. Foramen spinosum, Foramen ovale, Foramen rotundum, and superior orbital fissure were 6.43 mm, 4.54 mm, 11.23 mm, and 27.38 mm, respectively from MC. The distances of other neurovascular structures from MC are mentioned in Table 1.

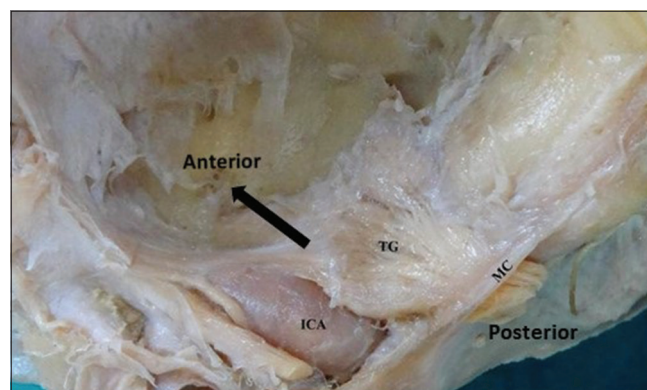


Figure 1: TG - Trigeminal ganglion, MC – Meckel's cave, ICA - Internal Carotid Artery

Table 1: Distances (in mm) of various anatomical structures from Trigeminal Ganglion and Meckel's cave

Landmarks	Left side (n=40)		Right side (n=40)		P	Both sides/Common (n=80)			
	Mean	SD	Mean	SD		Mean	SD	Min	Max
A	15.39	0.78	15.39	0.77	0.999	15.39	0.77	13.87	17.13
B	2.54	0.18	2.54	0.19	0.999	2.54	0.19	2.2	3.12
C	4.40	0.31	4.39	0.31	0.885	4.39	0.30	3.27	5.1
D	26.11	1.6	26.10	1.62	0.977	26.10	1.61	22.1	29.19
E	37.97	1.11	37.93	1.12	0.873	37.94	1.11	34.58	40.16
F	16.45	1.05	16.46	1.05	0.966	16.46	1.04	13.97	18.71
G	27.38	1.66	27.39	1.66	0.978	27.38	1.65	24.18	31.13
H	4.55	0.43	4.53	0.43	0.835	4.54	0.43	3.98	5.67
I	11.23	0.63	11.22	0.64	0.944	11.23	0.63	9.77	12.39
J	6.43	0.40	6.43	0.41	0.999	6.43	0.40	5.96	7.77
K	4.94	0.41	4.94	0.42	0.999	4.94	0.41	4.18	5.91
L	6.26	0.54	6.26	0.54	0.999	6.26	0.53	4.77	7.34
M	2.53	0.31	2.52	0.31	0.885	2.53	0.31	2	3.14
N	6.64	0.43	6.64	0.43	0.999	6.64	0.43	5.89	7.96
O	42.88	1.07	42.82	1.02	0.798	42.85	1.12	40.12	45.77
P	33.69	1.28	33.69	1.29	0.999	33.69	1.28	31.49	37.11

A-Length of the TG, B-Thickness of the TG, Width of the TG (C), Distance from Medial surface of the posterior root of the zygoma to MC (D), Distance from Lateral end of the petrous ridge to MC (E), Distance from Arcuate eminence to MC (F), Distance from Superior orbital fissure (SOF) to MC (G), Distance from Foramen ovale (FO) to MC (H), Distance from Foramen rotundum (FR) to MC (I), Distance from Foramen spinosum (FS) to MC (J), Distance from MC to trochlear nerve (K), Distance from MC to oculomotor nerve (L), Distance from MC to abducens nerve (M), Distance from Middle point of the anterior lip of the Facial nerve hiatus to MC (N), Distance from Posterior limit of the sigmoid sinus (SS) to MC (O), Distance from Anterior limit of the SS to MC (P)

Table 2: Comparison of distances (in mm) of various parameters from TG and MC in male and female

Landmark	Left side				P	Right side				P
	Female (n=8)		Male (n=32)			Female (n=8)		Male (n=32)		
	Mean	SD	Mean	SD		Mean	SD	Mean	SD	
A	15.22	0.80	15.44	0.8	0.498	15.21	0.76	15.44	0.78	0.481
B	2.55	0.20	2.54	0.19	0.883	2.57	0.24	2.54	0.19	0.735
C	4.33	0.22	4.42	0.33	0.350	4.31	0.23	4.42	0.33	0.288
D	26.24	1.15	26.08	1.74	0.752	26.25	1.14	26.07	1.74	0.736
E	37.72	1.26	38.00	1.09	0.588	37.73	1.28	37.99	1.10	0.605
F	16.75	1.46	16.39	0.94	0.525	16.74	1.47	16.39	0.94	0.543
G	26.23	1.54	27.68	1.59	0.038	26.24	1.53	27.68	1.59	0.038
H	4.72	0.59	4.52	0.39	0.378	4.66	0.57	4.51	0.40	0.490
I	11.32	0.86	11.21	0.59	0.737	11.31	0.85	11.21	0.59	0.750
J	6.43	0.43	6.44	0.41	0.973	6.44	0.42	6.44	0.42	0.999
K	4.79	0.47	4.98	0.42	0.274	4.80	0.41	4.98	0.42	0.296
L	6.29	0.51	6.26	0.51	0.888	6.29	0.70	6.26	0.51	0.889
M	2.45	0.43	2.55	0.28	0.537	2.44	0.42	2.55	0.29	0.489
N	6.50	0.43	6.68	0.44	0.323	6.50	0.43	6.68	0.44	0.308
O	42.72	1.19	42.93	1.06	0.661	42.71	1.18	42.92	1.06	0.646
P	33.87	1.39	33.65	1.28	0.702	33.88	1.39	33.65	1.28	0.685

A-Length of the TG, B-Thickness of the TG, Width of the TG (C), Distance from Medial surface of the posterior root of the zygoma to MC (D), Distance from Lateral end of the petrous ridge to MC (E), Distance from Arcuate eminence to MC (F), Distance from Superior orbital fissure (SOF) to MC (G), Distance from Foramen ovale (FO) to MC (H), Distance from Foramen rotundum (FR) to MC (I), Distance from Foramen spinosum (FS) to MC (J), Distance from MC to the trochlear nerve (K), Distance from MC to oculomotor nerve (L), Distance from MC to abducens nerve (M), Distance from Middle point of the anterior lip of the Facial nerve hiatus to MC (N), Distance from Posterior limit of the sigmoid sinus (SS) to MC (O), Distance from Anterior limit of the SS to MC (P)

DISCUSSION

An understanding of the anatomy of the MC and TG is clinically important in the evaluation and management of

patients having trigeminal neuralgia and tumors related with MC and TG. Most previous studies have measured only a few parameters. The present study focused on an extensive list of all parameters [Table 3] of various surgical approaches

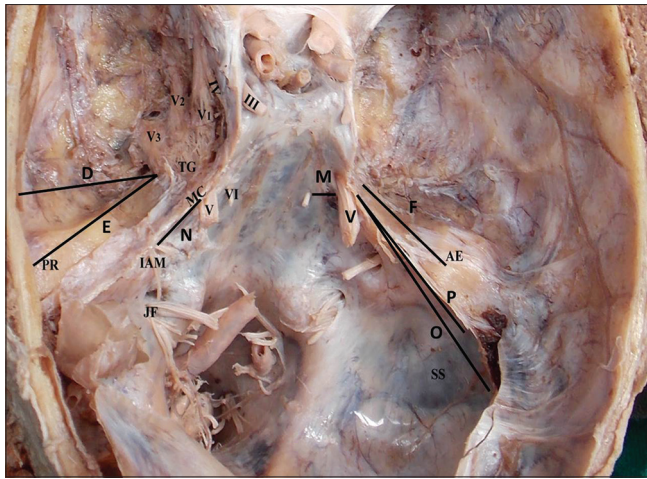


Figure 2: Anatomical landmarks and various parameters measured. AE – Arcuate eminence, PR – petrous ridge, IAM – Internal Acoustic Meatus, JF – Jugular Foramen, SS – Sigmoid Sinus, V1- Ophthalmic N, V2- Maxillary N, V3- Mandibular N, III – Oculomotor N, IV – Trochlear N, VI – Abducens N, D- Distance (Dt) from Medial surface of posterior root of zygoma to MC, E - Dt from Lateral end of petrous ridge to MC, F - Dt from Arcuate eminence to MC, M - Dt from MC to VI, N- Dt from Facial nerve hiatus to MC, O - Dt from Posterior limit of SS to MC, P - Dt from Anterior limit of the SS to MC

to TG and MC and also studied the differences in males and females [Table 2]. Early anthropologists have classified skulls as Caucasoid, Negroid, Mongoloid, and Australoid based on their geographical origins and physical traits. (1) The present study involved cadaveric heads from the Indian population, whereas most of the references for this study are from the European and American populations.

Morphometry of TG

The length and width of the TG in the present study ranged 13.87–17.13 mm (mean 15.39 mm) and 3.27–5.1 mm (mean 4.39 mm), respectively [Table 1]. Our findings are in accordance with the findings of Arslan *et al.*^[17] (mean length 16.1 mm, mean width 3.78 mm) and Henderson^[19] (mean length 14.2 mm, mean width 4.4 mm) but differed from Ajayi *et al.*^[18] (mean length 18.3 mm, mean width 7.9 mm). TG varied in thickness from 2.22 mm to 3.12 mm (mean 2.54 mm) in the present study which was comparable with findings of Arslan *et al.*^[17] (mean 2.52 mm) and Henderson^[19] (mean 2.64 mm).

Intracranial length of branches of TG

TG gave three branches namely, Ophthalmic nerve (V1), Maxillary nerve (V2), and Mandibular nerve (V3). Intracranial length of V1, from the convex margin of TG to SOF, was 27.38 mm in the present study which was in accordance with Ajayi *et al.*^[18] (28 mm) and Soeira *et al.*^[20] (27.4 mm) but differed from Januja *et al.*^[22] (19.4 mm). In the present study, the intracranial length of the ophthalmic nerve in both right and left sides in the males was longer, and the difference in the length was statistically significant. Intracranial length of V2, from the convex margin of TG to FR, was

11.23 mm in the present study which was in accordance with Henderson^[19]. (11.22 mm), Ajayi *et al.*^[18] (12.7 mm), Januja *et al.*^[22] (12.3 mm), and Soeira *et al.*^[20] (12.47 mm). V3 was 4.54 mm in length, from the convex margin of TG to FO, which was similar to the finding of Henderson^[19]. (4.89 mm) Arslan *et al.*^[17] (5.81 mm), Ajayi *et al.*^[18] (3.6 mm), and Soeira *et al.*^[20] (6.0 mm) but differed from the finding of Januja *et al.*^[22] (7.4 mm).

Distances of MC to adjacent bony landmarks and neurovascular structures

Arslan *et al.*^[17] measured distances of anatomical landmarks from TG and MC. They found the distance from the Medial surface of the posterior root of the zygoma to MC was 26.5 mm which was 26.10 mm in the present study.

For transtemporal approaches such as infralabyrinthine, translabyrinthine, and infracochlear approaches,^[24,25] lateral end of the petrous temporal bone is the reference point. The mean distance between MC and the lateral end of the petrous ridge along its superior border was 37.94 mm which is in accordance with Arslan *et al.*^[17] (38.4 mm).

When the anterior petrosectomy approach is used, the arcuate eminence can serve as an anatomical landmark.^[23,26] It was found at 16.46 mm from MC in the present study which was in accordance with Arslan *et al.*^[17] (16.60 mm) but differed from the finding of Day *et al.*^[23] (22.2 mm).

Using an anterolateral approach, the middle meningeal artery (MMA) passing through FS and the FO with the mandibular branch arising from TG serve as important landmarks for the identification of MC.^[8,14] In the treatment of Trigeminal Neuralgia, TG is approached via FO during neurosurgical interventions.^[3] In the present study, FS was located anterolaterally at a distance of 6.43 mm from MC similar to the findings of Henderson^[19]. (mean 6.59 mm) and Arslan *et al.*^[17] (mean 7.46 mm) but different from Samii *et al.*^[11] (mean 15 mm). FO was anterior to MC in the present study, and it was 4.54 mm from MC which was comparable to Henderson^[19]. (mean 4.89 mm) while it varied from distances of Arslan *et al.*^[17], Ajayi *et al.*^[18], Januja *et al.*^[22], and Soeira *et al.*^[20], at 5.81 mm, 3.6 mm, 7.4 mm, and 6.0 mm, respectively.

While using retrosigmoid–suprameatal approach, SS is the reference point. In the present study, the distance of MC from SS was measured at the level where it is in continuation with the transverse sinus. MC was 42.85 mm from the posterior limit and 33.69 mm from the anterior limit of SS and was in accordance with the findings of Arslan *et al.*^[17] which were 43.6 mm and 33.1 mm, respectively.

Intracranial portions of oculomotor, trochlear, abducent, and facial nerves were very nearby and were at the distance of 6.26 mm, 4.94 mm, 2.53 mm, and 6.64 mm, respectively from the MC, and the findings of the present study are comparable with that of Arslan *et al.*^[17] which are 6.57 mm, 5.53 mm, 1.87 mm, and 7.19 mm, respectively.

Table 3: Comparison with previous studies (Distances are in mm)

Landmark	Present study	Arslan <i>et al.</i> ^[17]	Henderson <i>et al.</i> ^[19]	Ajayi <i>et al.</i> ^[18]	Janjua <i>et al.</i> ^[22]	Soeira <i>et al.</i> ^[20]	Day <i>et al.</i> ^[23]	Samii <i>et al.</i> ^[11]
A	15.39 (13.87-17.13)	16.1 (14.8-17.6)	14.2 (13-15)	18.3 (12.3-23.3)				
B	2.54 (2.2-3.12)	2.52 (2.16-2.87)	2.64 (2.0-3.5)					
C	4.39 (3.27-5.1)	3.78 (3.49-4.13)	4.4 (4-5)	7.9 (4.6-9.3)				
D	26.10 (22.1-29.19)	26.5 (22.9-30.8)						
E	37.94 (34.58-40.16)	38.4 (34.8-43.1)						
F	16.46 (13.97-18.71)	16.6 (14.0-19.3)					22.2 (18.0-27.4)	
G	27.38 (24.18-31.13)			28 (19.7-36.6)	19.4 (16-24)	27.4 (22.4-32.4)		
H	4.54 (3.98-5.67)	5.81 (4.98-6.61)	4.89 (0-10)	3.6 (2.5-6.0)	7.4 (3-13)	6.0 (4.06-7.94)		
I	11 (9.77-12.39)		11.22	12.7 (8.8-17.5)	12.3 (8-19)	12.47 (9.62-15.32)		
J	6.43 (5.96-7.77)	7.46 (6.01-8.97)	6.59					15
K	4.94 (4.18-5.91)	5.53 (4.95-6.13)						
L	6.26 (4.77-7.34)	6.57 (5.75-7.45)						
M	2.53 (2.0-3.14)	1.87 (1.21-2.62)						
N	6.64 (5.89-7.96)	7.19 (6.02-8.42)						
O	42.85 (40.12-45.77)	43.6 (40.2-47.5)						
P	33.69 (31.49-37.11)	33.1 (30.2-36.5)						

A-Length of the TG, B-Thickness of the TG, Width of the TG (C), Distance from Medial surface of the posterior root of the zygoma to MC (D), Distance from Lateral end of the petrous ridge to MC (E), Distance from Arcuate eminence to MC (F), Distance from Superior orbital fissure (SOF) to MC (G), Distance from Foramen ovale (FO) to MC (H), Distance from Foramen rotundum (FR) to MC (I), Distance from Foramen spinosum (FS) to MC (J), Distance from MC to trochlear nerve (K), Distance from MC to oculomotor nerve (L), Distance from MC to abducens nerve (M), Distance from Middle point of the anterior lip of the Facial nerve hiatus to MC (N), Distance from Posterior limit of the sigmoid sinus (SS) to MC (O), Distance from Anterior limit of the SS to MC (P)

There are minimal differences in various distances between right and left sides [Table 1] in most individuals in the present study, and this should be borne in mind by the operating surgeons.

CONCLUSION

The knowledge of MC, TG, and its anatomical relations to various neurovascular structures are indispensable in planning surgical procedures of TG, MC, and neural blocks involving TN. This detailed anatomical knowledge will help in averting intraoperative surgical complications.

Limitations

Radiological correlation and study on the relations of various anatomical structures following cadaveric surgical procedures as in the live would have been informative and relevant.

Acknowledgements

The authors express their sincere thanks to those who donated their bodies for furthering medical education and research. The statistical analysis by Dr. Abhijit Pakhare and Dr. Anirban Chatterjee, Department of Community and Family Medicine, are acknowledged with gratitude.

Financial support and sponsorship

Nil.

Conflicts of interest

There are no conflicts of interest.

REFERENCES

1. Standring S. Cranial cavity. In: Gray's Anatomy; The Anatomical Basis of Clinical Practice. 42nd ed. Edinburg: Elsevier Churchill Livingstone; 2020. p. 435-54.
2. Datta AK. Interior of the cranium. In: Essentials of Human Anatomy,

- Head and Neck. 6th ed. Kolkata: Current Books International; 2017. p. 182-4.
3. Messlinger K, Russo A. Current understanding of trigeminal ganglion structure and function in headache. *Cephalalgia* 2019;39:1661-74.
 4. Messlinger K, Balczak L, Russo A. Cross-talk signaling in the trigeminal ganglion: Role of neuropeptides and other mediators. *J Neural Transm (Vienna)* 2020;127:431-44.
 5. Kontzialis M, Kocak M. Imaging evaluation of trigeminal neuralgia. *J Istanbul Univ Fac Dent* 2017;51 (3 Suppl 1):S62-8.
 6. Montano N, Conforti G, Di Bonaventura R, Meglio M, Fernandez E, Papacci F. Advances in diagnosis and treatment of trigeminal neuralgia. *Ther Clin Risk Manag* 2015;11:289-99.
 7. Katheriya G, Chaurasia A, Khan N, Iqbal J. Prevalence of trigeminal neuralgia in Indian population visiting a higher dental care center in North India. *Natl J Maxillofac Surg* 2019;10:195-9.
 8. Goel A, Nadkarni T. Basal lateral subtemporal approach for trigeminal neurinomas: Report of an experience with 18 cases. *Acta Neurochir (Wien)* 1999;141:711-9.
 9. Taha JM, Tew JM, van Loveren HR, Keller JT, El-Kalliny M. Comparison of conventional and skull base surgical approaches for the excision of trigeminal neurinomas. *J Neurosurg* 1995;82:719-25.
 10. Chui M, Tucker W, Hudson A, Bayer N. High resolution CT of Meckel's cave. *Neuroradiology* 1985;27:403-9.
 11. Samii M, Carvalho GA, Tatagiba M, Matthies C. Surgical management of meningiomas originating in Meckel's cave. *Neurosurgery* 1997;41:767-75.
 12. Goel A. Middle fossa sub-Gasserian ganglion approach to clivus chordomas. *Acta Neurochir (Wien)* 1995;136:212-6.
 13. Daniels DL, Pech P, Pojunas KW, Kilgore DP, Williams AL, Haughton VM. Trigeminal nerve: Anatomic correlation with MR imaging. *Radiology* 1986;159:577-83.
 14. Kapila A, Chakeres DW, Blanco E. The Meckel cave: Computed tomographic study. Part I: Normal anatomy; Part II: Pathology. *Radiology* 1984;152:425-33.
 15. Rubinstein D, Stears RL, Stears JC. Trigeminal nerve and ganglion in the Meckel cave: Appearance at CT and MR imaging. *Radiology* 1994;193:155-9.
 16. Yousry I, Camelio S, Wiesmann M, Schmid UD, Moriggl B, Brückmann H, *et al.* Detailed magnetic resonance imaging anatomy of the cisternal segment of the abducent nerve: Dorello's canal and neurovascular relationships and landmarks. *J Neurosurg* 1999;91:276-83.
 17. Arslan M, Deda H, Avci E, Elhan A, Tekdemir I, Tubbs RS, *et al.* Anatomy of Meckel's cave and the trigeminal ganglion: Anatomical landmarks for a safer approach to them. *Turk Neurosurg* 2012;22:317-23.
 18. Ajayi NO, Lazarus L, Satyapal KS. Trigeminal cave and ganglion: An anatomical review. *Int J Morphol* 2013;31:1444-8.
 19. Henderson WR. The anatomy of the gasserian ganglion and the distribution of pain in relation to injections and operations for trigeminal neuralgia. *Ann R Coll Surg Engl* 1965;37:346-73.
 20. Soeira G, Abd El-Bary TH, Dujovny M, Siavin KV, Ausman JI. Microsurgical anatomy of the trigeminal nerve. *Neurol Res* 1994;16:273-83.
 21. Koshi R. The cranial cavity. In: Cunningham's Manual of Practical Anatomy, Head, Neck and Brain. 16th ed. Oxford United Kingdom: Oxford University Press; 2018. p. 73-91.
 22. Janjua RM, Al-Mefty O, Densler DW, Shields CB. Dural relationships of Meckel cave and lateral wall of the cavernous sinus. *Neurosurg Focus* 2008;25:E2.
 23. Day JD, Fukushima T, Giannotta SL. Microanatomical study of the extradural middle fossa approach to the petroclival and posterior cavernous sinus region: Description of the rhomboid construct. *Neurosurgery* 1994;34:1009-16; discussion 1016.
 24. Giddings NA, Brackmann DE, Kwartler JA. Transcanal infracochlear approach to the petrous apex. *Otolaryngol Neck Surg* 1991;104:29-36.
 25. Haberkamp TJ. Surgical anatomy of the transtemporal approaches to the petrous apex. *Otol Neurotol* 1997;18:501-6.
 26. Miller CG, Van Loveren HR, Keller JT, Pensak M, El-Kalliny M, Tew Jr JM. Transpetrosal approach: Surgical anatomy and technique. *Neurosurgery* 1993;33:461-9.