

Evaluation of Tenascin Expression in Ameloblastoma, Odontogenic Keratocyst, and Dentigerous Cyst by Immunohistochemistry

Narges Ghazi¹, Nasrollah Saghravani¹, Majid Mirhashemi¹, Abolfazl Abedini Ardakani²

¹Department of Oral and Maxillofacial Pathology, School of Dentistry, Mashhad University of Medical Sciences, Mashhad, Iran, ²School of Dentistry, Mashhad University of Medical Sciences, Mashhad, Iran

Abstract

Background: The aim of this study was to evaluate the expression pattern of tenascin in ameloblastoma, odontogenic keratocyst, and dentigerous cyst.

Materials and Methods: The expression of tenascin was evaluated in microscopic slides of 42 paraffin blocks including 12 ameloblastomas, 15 odontogenic keratocysts, and 15 dentigerous cysts by immunohistochemistry. The expression of tenascin was examined in stroma, epithelium-connective tissue interface, and epithelium of the lesions by two pathologists semiquantitatively.

Results: Stromal expression of tenascin was higher in ameloblastomas than other groups. All the paired groups showed significant differences except comparison of odontogenic keratocysts and dentigerous cysts. Epithelial-mesenchymal interface expression of tenascin was significantly higher in ameloblastomas and odontogenic keratocysts than dentigerous cysts. All the paired groups showed significant differences except comparison of odontogenic keratocysts and ameloblastomas. Expression of tenascin in epithelial cells of ameloblastomas was focal whereas in odontogenic keratocysts and dentigerous cysts negative immunoreactivity was reported.

Conclusions: Expression of tenascin in these lesions suggests that it could play a role in epithelial-mesenchymal interaction. Higher expression of tenascin in ameloblastoma, can explain immaturity of its stroma and aggressive nature of this lesion compared with other studied groups. Moreover, higher expression of tenascin in epithelial-mesenchymal interface of odontogenic keratocyst compared with dentigerous cyst reveals its more immature and aggressive nature and high rate of recurrence.

Keywords: Ameloblastoma, dentigerous cyst, immunohistochemistry, odontogenic keratocyst, tenascin

Address for correspondence: Dr. Majid Mirhashemi, Department of Oral and Maxillofacial Pathology, School of Dentistry, Mashhad University of Medical Sciences, Mashhad, Iran.

E-mail: mirhashemim@mums.ac.ir, s.m.mirhashemi@gmail.com

Submitted: 24-May-2021; **Revised:** 09-May-2022; **Accepted:** 10-May-2022; **Published:** 21-Mar-2023

INTRODUCTION

Ameloblastoma is the most common clinically important odontogenic tumor. The recurrence rate of 50-90% after curettage for solid type has been reported in various studies.^[1] Dentigerous cyst (DC) or follicular cyst is the second most common odontogenic cyst and the most frequent developmental cyst in the jaw.^[2-4] Untreated DCs have potential for neoplastic

transformation and carcinomatous changes. In these cases, lining epithelium can transform into ameloblastoma.^[5] Odontogenic keratocyst (OKC) is the third most common cyst of the oral cavity after radicular cyst (RC) and DC.^[6] In final growth stages of this cyst, enzymatic factors and proliferation of epithelial cells play a more prominent role than increasing

This is an open access journal, and articles are distributed under the terms of the Creative Commons Attribution-NonCommercial-ShareAlike 4.0 License, which allows others to remix, tweak, and build upon the work non-commercially, as long as appropriate credit is given and the new creations are licensed under the identical terms.

For reprints contact: WKHLRPMedknow_reprints@wolterskluwer.com

How to cite this article: Ghazi N, Saghravani N, Mirhashemi M, Abedini Ardakani A. Evaluation of tenascin expression in ameloblastoma, odontogenic keratocyst, and dentigerous cyst by immunohistochemistry. *Adv Biomed Res* 2023;12:66.

Access this article online	
Quick Response Code: 	Website: www.advbiores.net
	DOI: 10.4103/abr.abr_131_21

osmotic and hydrostatic pressure.^[7,8] Unlike other odontogenic cysts, OKC usually recurs after treatment.^[9]

Tenascin is a large glycoprotein of the extracellular matrix with a molecular weight of 190-250 KDa. It is involved in cell-cell and cell-matrix interactions and temporarily appears in fetal and neonatal development and wound healing. It has been reported in the epithelial-mesenchymal junction during the process of tumorigenesis, and varying amounts of tenascin have been reported in different lesions that may affect cell proliferation, differentiation, and migration.^[10,11] In vertebrates, tenascin has four types C, X, R, and W with different expression patterns, and despite their structural similarity, each has distinct functions.^[12] Tenascin-c increases tumor cell proliferation compared to normal conditions and reduces binding, also known as a vasodilator.^[13]

As studies evaluating the expression of extracellular matrix markers in odontogenic lesions are limited, in this study, we attempted to investigate the role of tenascin in ameloblastoma, as the most common odontogenic tumor, OKC, and DC, as two cystic lesions with different biological behavior to provide a basis for further studies about tenascin as a therapeutic target in aggressive and recurrent odontogenic lesions.

MATERIALS AND METHODS

Forty-two paraffin blocks including 12 ameloblastomas, 15 DCs, and 15 OKCs of the oral cavity along with clinical information of patients including age and sex were extracted from the archive of the pathology department of Mashhad School of Dentistry after morphological examination by two pathologists and marking the appropriate focus in slides. These blocks had the largest tissue volume and were suitable for immunohistochemical techniques. Whenever two pathologists did not agree, the third pathologist was consulted. To perform immunohistochemical staining, 3 μ m sections were sliced from each tissue paraffin block. Tissue sections were then de-paraffinized with xylene and hydrated with graded alcohols. To recover the antigen, sections were placed in a buffer solution (Tris) and heated in microwave oven for 7 min at 700 watts and 15 min at 350 watts. To inhibit the activity of endogenous peroxidase, sections were incubated for 5 min in 5% methanol and H₂O₂ solution. Tissue sections were then washed with phosphate buffered saline (PBS) at pH = 7.3 and then were exposed to 10% non-immune serum for 10 min. Primary antibody indicator of tenascin was applied to the slides at room temperature for 60 min according to the manufacturer's instructions (Novocastra, NCL-TENAS-C, clone TENAS 49, NEWCASTLE, UK dilution 1:50). The slices were incubated with secondary antibody at room temperature for 30 min after washing with PBS. Sections were then rinsed again with PBS and incubated for 5 min in a solution containing 3 diaminobenzidine and 3-amino-9-ethyl carbazole. After that sections were counterstained with hematoxylin and cover slipped with asynthetic mounting media. Stroma, epithelial-mesenchymal

interface and epithelium immunoreactivity of the tissues were examined by pathologists for pattern and distribution of marker with magnification of $\times 100$, $\times 200$, and $\times 400$ by light microscopy (LABOMED). The distribution pattern of tenascin in stroma was examined based on focal or diffuse staining.^[14] The expression pattern of tenascin in stroma, connective tissue interface and epithelium was divided into three categories: fibrillar (F), fibroreticular (FR), and reticular (R).^[15,16] The expression pattern of tenascin in the interface of connective tissue and epithelium based on continuous and discontinuous was also investigated.^[14] The rate of tenascin expression in stroma, connective tissue interface, and epithelium was measured semiquantitatively and recorded as follows: 0 (absence of staining), +1 (weak staining greater than background staining), +2 (moderate staining) and +3 (intense staining).^[14,15] Tenascin expression in epithelium was classified as positivity, focal positivity, and no staining.^[15] SPSS V.16 software and Fisher, Kruskal-Wallis and Chi-square statistical tests were used to compare the immunoreactivity of stroma, epithelial-mesenchymal interface, and epithelium of the studied tissues in terms of marker pattern and distribution.

RESULTS

In this study, 42 samples from 20 (47.6%) women and 22 (52.4%) men with a mean age of 25 ± 12 and an age range of 5 to 62 years in terms of variables of staining pattern, distribution pattern and expression intensity were examined. There was no significant difference between the groups for mean age and gender distribution ($P = 0.943$ and $P = 0.075$, respectively).

Comparing the distribution of tenascin immunostaining pattern in lesions, stroma of the studied groups showed significant statistical difference for fibrillar (F) staining pattern [Table 1 and Figure 1]. There was no significant difference between OKC and DC groups, but both were significantly higher than ameloblastoma group. There was no statistically significant difference between the groups regarding

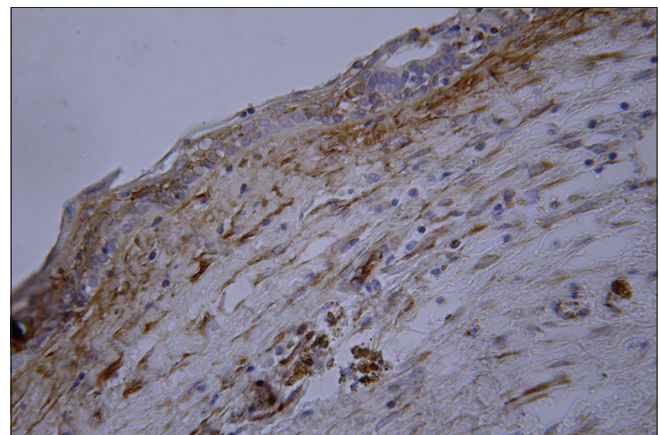


Figure 1: Expression of tenascin in DC. Fibrillar pattern, focal, and moderate staining in the stroma, focal expression in the epithelium, $\times 400$ magnification

reticular (R) and fibro-reticular (FR) patterns. In general, the frequency distribution of the staining pattern was significantly different in all groups ($P = 0.034$). Tenascin expression intensity in lesions stroma was measured as +1 (weak), +2 (moderate), +3 (intense/strong) and 0 (no staining). In this regard, a significant difference was observed between all groups ($P < 0.001$). Paired groups comparison showed that mean staining score in ameloblastoma group was significantly higher than OKC and DC groups, but no significant difference was observed between OKC and DC groups ($P < 0.001$ and $P = 1.00$, respectively).

According to Table 2, expression of tenascin in epithelial-mesenchymal interface of the studied lesions [Figures 2 and 3], showed statistically significant difference for fibrillar staining pattern in different groups. It was also found that groups of ameloblastoma and DC were not significantly different from each other, but both were significantly lower than OKC group. Comparing fibroreticular pattern, there was no significant difference between the studied groups, but the differences were significant for R pattern. Comparing in paired groups, it was found that DC group was significantly higher than the other groups and there was no significant difference between the other two groups. In general, staining pattern was significantly different in all groups ($P = 0.013$). The pattern of tenascin expression in the interface was both continuous and non-continuous and it was significantly different in all groups ($P = 0.002$). Tenascin expression intensity in epithelial-mesenchymal interface was also classified as in stroma. According to Table 2, there was no unstained sample in any of the groups and no weak staining was observed in ameloblastoma and OKC groups. Overall, there was a statistically significant difference between three groups in terms of staining intensity ($P < 0.001$). Comparing in paired groups, it was found that the mean staining score in DC group was significantly lower than OKC and ameloblastoma groups, but no significant difference was observed between OKC and ameloblastoma groups ($P < 0.001$ and $P = 1.00$, respectively).

Tenascin expression in epithelial cells of the lesions was investigated as positive immunoreactivity, focal staining and lack of staining [Table 3 and Figures 1-3]. In total, a statistically significant difference was observed between three groups ($P = 0.001$).

DISCUSSION

Results of the present study showed higher immunostaining of ameloblastoma than OKC and DC. Some degree of staining was observed in all samples of ameloblastoma, but there was no significant difference between OKC and DC. Also, expression of tenascin in ameloblastoma was more seen close to nests. Similar results were obtained in the study of de Medeiros *et al.*^[15] In their study, the expression of extracellular matrix (ECM) proteins, including tenascin, was examined in 20 samples of ameloblastoma and 10 samples of adenomatoid odontogenic tumor (AOT). Stroma of the studied lesions showed presence of tenascin, especially in the areas close to epithelial-mesenchymal interface. These results suggest a possible role for tenascin in the interactions between tumor cells and adjacent stroma. In the present study, immunoreactivity in the stroma of ameloblastoma was higher. As higher expression of tenascin is reported in embryonic and immature tissues, our result may indicate the immaturity of stroma and justify aggressive behavior of the lesion.

Regarding the distribution pattern in the stroma of ameloblastoma, 9 diffuse expressions and 3 focal expressions were reported. In contrast, the study of Carnelio *et al.*,^[14] on 10 ameloblastoma and 10 ameloblastic fibroma specimens showed focal expression in 80% of ameloblastomas stroma. This decrease in tenascin expression may be due to specific enzymes such as MMP's or tenascin inhibitory factors. Frequent discontinuation of tenascin can also be associated with MMP's deficiency in stroma. Considering that in the present study, the expression in ameloblastoma stroma is significantly higher than the other two lesions, indicating that ameloblastoma is more immature than OKC and DC and its

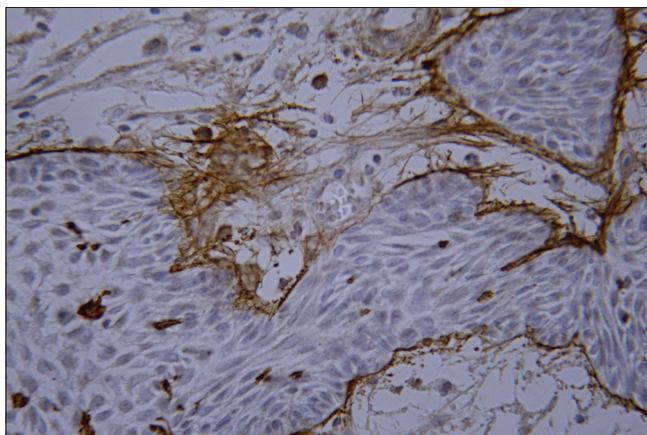


Figure 2: Expression of tenascin in ameloblastoma. Reticular pattern, discontinuous distribution at the epithelial-mesenchymal interface, focal, and intense staining in the epithelium, $\times 400$ magnification

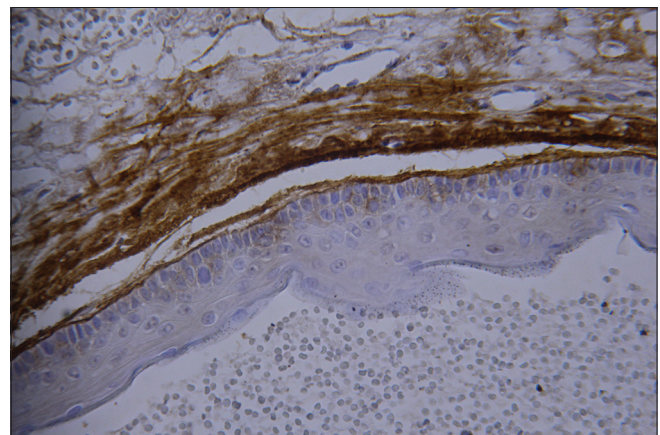


Figure 3: Expression of tenascin in OKC. Fibrillar pattern, continuous distribution, intense staining at the epithelial-mesenchymal interface, lack of expression in the epithelium, $\times 400$ magnification

Table 1: Staining pattern, distribution, and intensity of tenascin expression in stroma of the studied groups

	Staining pattern						Intensity						Distribution		
	F	FR	R	Total	+3	+2	+1	0	Total	Focal	Diffuse	Total			
Ameloblastoma	0 (0%)	7 (58.3%)	5 (41.7%)	12 (100%)	1 (8.3%)	10 (83.4%)	1 (8.3%)	0 (0%)	12 (100%)	3 (25%)	9 (75%)	12 (100%)			
OKC	7 (46.7%)	3 (20%)	5 (33.3%)	15 (100%)	0 (0%)	0 (0%)	7 (46.7%)	8 (53.3%)	15 (100%)	10 (66.7%)	5 (33.3%)	15 (100%)			
DC	6 (40%)	6 (40%)	3 (20%)	15 (100%)	0 (0%)	0 (0%)	6 (40%)	9 (60%)	15 (100%)	3 (20%)	12 (80%)	15 (100%)			
Total	13 (31%)	16 (38.1%)	13 (31%)	42 (100%)	1 (2.4%)	10 (23.8%)	14 (33.3%)	17 (40.5%)	42 (100%)	16 (38%)	26 (61.9%)	42 (100%)			
Test	P=0.034						P<0.001						P=0.062		

Table 2: Staining pattern, distribution, and intensity of tenascin expression in epithelial-mesenchymal interface of the studied groups

	Staining pattern				Intensity				Distribution			
	F	FR	R	Total	+3	+2	+1	0	Total	Continuous	Non-continuous	Total
Ameloblastoma	2 (16.7%)	5 (41.7%)	5 (41.7%)	12 (100%)	10 (83.3%)	2 (16.7%)	0 (0%)	0 (0%)	12 (100%)	2 (16.7%)	10 (83.3%)	12 (100%)
OKC	8 (53.3%)	2 (13.3%)	5 (33.3%)	15 (100%)	12 (80%)	3 (20%)	0 (0%)	0 (0%)	15 (100%)	12 (80%)	3 (20%)	15 (100%)
DC	1 (6.7%)	2 (13.3%)	12 (80%)	15 (100%)	1 (6.7%)	4 (26.7%)	10 (66.7%)	0 (0%)	15 (100%)	11 (73.3%)	4 (26.7%)	15 (100%)
Total	11 (26.2%)	9 (21.4%)	22 (52.4%)	42 (100%)	23 (54.8%)	9 (21.4%)	10 (23.8%)	0 (0%)	42 (100%)	25 (59.5%)	17 (40.5%)	42 (100%)
Test	P=0.013				P<0.001				P=0.002			

behavior is more aggressive. Also, the expression of tenascin in stroma was seen as diffuse, which, contrary to the above study, shows immaturity of the lesion stroma.

Regarding the expression pattern of tenascin in stroma, it was observed that fibrillar pattern is significantly higher in OKC and DC than in ameloblastoma. No fibrillar pattern was observed in ameloblastoma and all ameloblastomas showed reticular pattern or fibroreticular. Fibroreticular pattern was less in OKC and DC than in ameloblastoma, which was not statistically significant. There was no significant difference between the lesions in expression of reticular pattern. Discontinuous distribution pattern was higher in epithelial-mesenchymal interface of ameloblastoma while continuous pattern was higher in OKC and DC. Similar to our results, in the study of de Medeiros *et al.*^[15] on AOT and ameloblastoma, tenascin showed linear and discontinuous expression in basement membrane, which was more evident in solid and desmoplastic ameloblastoma. Carnelio *et al.*^[14] observed a heterogeneous pattern of tenascin in ameloblastoma from a range of reactive to non-reactive regions in one section. In most follicles, a discontinuous linear band with frequent clefts was observed at the epithelial-mesenchymal interface with differences in intensity. These results are consistent with articles suggest that extracellular matrix glycoproteins, as an integral part of stromal connective tissue, play an important role in tissue morphological characteristics and tumor behavior. Frequent gaps in expression of tenascin (discontinuous pattern) in ameloblastoma indicate its aggressive nature. In the study of de Oliveira *et al.*,^[16] immunoreactivity of tenascin in basement membrane and capsule of OKC was shown to be higher than RC and DC, and also, basement membrane region of OKC showed a more continuous distribution pattern than DC and RC. However, this result was not obtained in the present study and distribution continuity in OKC and DC was equal. In the present study, discontinuous expression was reported in ameloblastoma and in most OKC and DC specimens, which indicated a more aggressive behavior of ameloblastoma than the other two lesions. Also, there is no significant difference between OKC and DC. Therefore, the aggressive behavior and recurrence of OKC compared with DC could not be related to these observations.

Evaluation of epithelial-mesenchymal interface showed fibrillar pattern was almost equal in ameloblastoma and DC, but was significantly higher in OKC than in the other two lesions. Reticular pattern was almost equal in ameloblastoma and OKC and significantly higher in DC. The pattern of fibroreticular staining in ameloblastoma was higher than OKC and DC, which was not statistically significant. These results indicate the ability of all three lesions to express a mixed (fibroreticular) pattern is not significantly different.

DC showed less immunoreactivity in epithelial-mesenchymal interface than ameloblastoma and OKC. The difference between ameloblastoma and OKC was not significant. In the study of de Medeiros *et al.*,^[15] as in the present study, it was observed that

Table 3: The expression of tenascin in epithelial cells of the studied groups

	Positivity	Focal	No staining	Total
Ameloblastoma	1 (8.3%)	9 (75%)	2 (16.7%)	12 (100%)
OKC	1 (6.7%)	3 (20%)	11 (73.3%)	15 (100%)
DC	0 (0%)	2 (13.3%)	13 (86.7%)	15 (100%)
Total	2 (4.8%)	14 (33.3%)	26 (61.9%)	42 (100%)
Test	<i>P</i> =0.001			

tenascin is highly expressed in epithelial-mesenchymal interface of AOT and ameloblastoma. Intense expression of tenascin in ameloblastoma, especially at epithelial-mesenchymal interface, may indicate strong parenchymal-stromal interactions to create an acceptable microenvironment for high proliferative activity and invasive capacity of tumor cells. This hypothesis is based on the proven role of tenascin in epithelial-mesenchymal interactions in embryonic period and several pathological processes. In the study of de Oliveira *et al.*,^[16] immunoreactivity of tenascin in OKC basement membrane was shown to be higher than RC and DC. In the studied DCs, a thin band of poorly expressed tenascin with a reticular pattern was seen at epithelial-mesenchymal interface, while in half of OKC cases a thick band with a reticular, fibrillar pattern, or both with deep penetration into the epithelium and intense expression was observed. de Oliveira *et al.*^[16] attributed one of the reasons for more pronounced expression of tenascin in OKC to severity of epithelial-mesenchymal interactions during embryonic development and formation of OKC from more primary odontogenic epithelium with more severe and profound epithelial-mesenchymal interactions. In a study by da Silva *et al.*,^[17] tenascin staining was used to compare OKC and orthokeratinized odontogenic cyst (OOC). The result was negative in OOC and positive in OKC. Tenascin was observed in basement membrane region and adjacent extracellular matrix of OKCs and was not associated with inflammation. These results indicate an important difference between these two cysts because tenascin is an adhesion-regulating molecule expressed in unstable environments such as neoplasms and healing areas. These results are consistent with the limited growth potential of OOC than OKC. Low expression of tenascin in stroma and epithelial-mesenchymal interface of DC may suggest maturity of stroma and low interaction between epithelium and mesenchyme, thus justifying benign behavior of the lesion. Also disintegration of tenascin by MMPs can also be a reason for these observations. On the other hand, intense expression of tenascin in ameloblastoma and OKC shows more aggressive and immature nature of these two lesions as well as high recurrence of OKC. Also, due to the proven role of tenascin in loosening cell attachment and its association with cystic space formation, there may be a relevance between looseness and fragility of OKC epithelium, which is the main cause of frequent recurrences, and tenascin expression.^[11,18]

In the past, tenascin was thought to be made by mesenchymal cells, but more recent studies have shown that epithelial cells

also play an important role in its production.^[19,20] Comparing the staining of epithelial cells of the studied lesions, it was observed that most of the ameloblastomas were focally stained and their staining was significantly higher compared to the other two lesions, while most cases of DCs and OKCs showed no expression. According to Becker *et al.*,^[21] morphogenesis and cell differentiation in evolving teeth are controlled by a series of interactions between epithelial and mesenchymal tissues. Therefore, development of odontogenic tumors and cysts that consist of odontogenic tissue remnants also depend on these interactions. Carnelio *et al.*^[14] examined expression of tenascin in ameloblastoma and ameloblastic fibroma and found that expression of tenascin in peripheral and central cells of follicles in these tumors is weak but a strong reaction was observed in areas with squamous cell metaplasia. According to the results obtained in the present study, expression of tenascin in epithelium of ameloblastoma can be associated with its more aggressive nature than the other two lesions.

CONCLUSIONS

In the present study, expression of tenascin in stroma of ameloblastoma was significantly higher than other studied groups. Also, severe immunoreactivity in epithelial-mesenchymal interface and focal positivity in epithelial cells of ameloblastoma were reported. As tenascin is less expressed in adult tissues, so higher expression in ameloblastoma can explain its immaturity and more aggressive behavior. The expression of tenascin in epithelial-mesenchymal interface of OKC was severe, continuous and deep, indicating high epithelial-mesenchymal interactions and immaturity of the lesion, and proves the invasive and tumoral behavior of this cyst. Expression of tenascin in DC was poor, which is consistent with benign features of this cyst.

Ethics approval

The study protocol was approved by the Research Ethics Committees of Vice-Chancellor in Research, Mashhad University of Medical Sciences (Approval ID: IR.MUMS.SD.REC.1394.208).

Financial support and sponsorship

This research was done with the support of Research and Technology Vice-Chancellor of Mashhad University of Medical Sciences.

Conflicts of interest

There are no conflicts of interest.

REFERENCES

- Pappalardo M, Tsao C-K, Tsang ML, Zheng J, Chang Y-M, Tsai C-Y. Long-term outcome of patients with or without osseointegrated implants after resection of mandibular ameloblastoma and reconstruction with vascularized bone graft: Functional assessment and quality of life. *J Plast Reconstr Aesthet Surg* 2018;71:1076-85.
- AlKhudair B, AlKhatib A, AlAzzeh G, AlMomen A. Bilateral dentigerous cysts and ectopic teeth in the maxillary sinuses: A case

- report and literature review. *Int J Surg Case Rep* 2019;55:117-20.
3. Cawson RA, Odell EW. *Cawson's Essentials of Oral Pathology and Oral Medicine E-Book*. Elsevier Health Sciences. China; 2017.
 4. Regezi J, Sciubba J, Jordan R. *Oral Pathology: Clinical Pathologic Correlations*. In: Dolan J, editor. Elsevier. China; 2016.
 5. Bilodeau EA, Collins BM. Odontogenic cysts and neoplasms. *Surg Pathol Clin* 2017;10:177-222.
 6. Jaeger F, de Noronha MS, Silva MLV, Amaral MBF, Grossmann SdMC, Horta MCR, *et al.* Prevalence profile of odontogenic cysts and tumors on Brazilian sample after the reclassification of odontogenic keratocyst. *J Craniomaxillofac Surg* 2017;45:267-70.
 7. Deshmukh SB, Sonawane K. Odontogenic keratocysts to keratocystic odontogenic tumor. *IJADS* 2019;5:09-15.
 8. Lam EW. Inflammatory conditions of the jaws. *White and Pharoah's Oral Radiology: Principles and Interpretation*. Elsevier. China; 2018. p. 363.
 9. Neville BW, Damm DD, Allen CM, Chi AC. *Oral and Maxillofacial Pathology*. Elsevier Health Sciences; 2015.
 10. Gnepp DR, Bishop JA. *Gnepp's Diagnostic Surgical Pathology of the Head and Neck E-Book*. Elsevier Health Sciences. Canada; 2020.
 11. Nanci A. *Ten Cate's Oral Histology-E-Book: Development, Structure, and Function*. Elsevier Health Sciences. China; 2017.
 12. Roll L, Faissner A. Tenascins in CNS lesions. In *Seminars in cell & developmental biology* 2019 May 1 (Vol. 89, pp. 118-124). Academic Press.
 13. Okada T, Suzuki H. The role of tenascin-C in tissue injury and repair after stroke. *Front Immunol* 2021;11:607587.
 14. Carnelio S, Vij H. Expression of tenascin and nucleolar organizer region in ameloblastoma and ameloblastic fibroma. *J Oral Pathol Med* 2010;39:223-9.
 15. de Medeiros AMC, Nonaka CFW, Galvão HC, de Souza LB, de Almeida Freitas R. Expression of extracellular matrix proteins in ameloblastomas and adenomatoid odontogenic tumors. *Eur Arch Otorhinolaryngol* 2010;267:303-10.
 16. de Oliveira MDC, De Miranda JL, De Amorim RFB, De Souza LB, de Almeida Freitas R. Tenascin and fibronectin expression in odontogenic cysts. *J Oral Pathol Med* 2004;33:354-9.
 17. da Silva MJA, de Sousa SOM, Corrêa L, Carvalhosa AA, de Araáaujo VC. Immunohistochemical study of the orthokeratinized odontogenic cyst: A comparison with the odontogenic keratocyst. *Oral Surg Oral Med Oral Pathol Oral Radiol Endod* 2002;94:732-7.
 18. Brellier F, Chiquet-Ehrismann R. How do tenascins influence the birth and life of a malignant cell? *J Cell Mol Med* 2012;16:32-40.
 19. Howeedy A, Virtanen I, Laitinen L, Gould N, Koukoulis G, Gould V. Differential distribution of tenascin in the normal, hyperplastic, and neoplastic breast. *Lab Invest* 1990;63:798-806.
 20. Kawakatsu H, Shiurba R, Obara M, Hiraiwa H, Kusakabe M, Sakakura T. Human carcinoma cells synthesize and secrete tenascin in vitro. *Jpn J Cancer Res* 1992;83:1073-80.
 21. Becker J, Reichart P, Schuppan D, Philipsen H. Ectomesenchyme of ameloblastic fibroma reveals a characteristic distribution of extracellular matrix proteins. *J Oral Pathol Med* 1992;21:156-9.