

Comparison of the accuracy of cardiac computed tomography angiography and transthoracic echocardiography in the diagnosis of mitral valve prolapse

Maryam Moradi, Masoud Nazari, Amir Sajjadih Khajouei, Morteza Abdar Esfahani

Department of Radiology, Saint Alzahra Hospital, Isfahan University of Medical Sciences, Isfahan, Iran

Abstract

Background: Cardiac multidetector computed tomography (MDCT) has been mainly applied in the diagnosis of valvular heart morphology and function along with the assessment of coronary artery disease. This study aimed to evaluate the diagnostic performance of coronary MDCT angiography for the diagnosis of mitral valve prolapse (MVP), as compared to transthoracic echocardiography (TTE).

Materials and Methods: A total of 40 patients who had undergone both TTE and MDCT within a three-month period were included in the study. Two parameters of mitral valve leaflet thickness and leaflet billowing were measured using both techniques. The MDCT results were compared with those of TTE, which was the reference standard.

Results: Implementing the Receiver Operating Characteristic (ROC) test on the data for MDCT-measured leaflet billowing received from MDCT angiography suggests that the area under the ROC curve is 96% for a declared variable, which is absolutely significant ($P < 0.001$), and MDCT-measured leaflet billowing is an appropriate index for the diagnosis of mitral valve prolapse. On the basis of the achieved cut-off point from the ROC analysis (which equals 2.5 mm leaflet billowing) the MDCT-measured leaflet billowing takes a sensitivity and specificity of 68.4 and 95.2%. The false positive and false negative results are 4.8 and 31.6%. The positive and negative predictive values (PPV and NPV) of the revealed test indicate 92.9 and 76.9%, respectively. Finally, the consistency of the MDCT measured leaflet billowing for diagnosing the mitral valve prolapse is 82.5%. Based on the mentioned test, the consistency of the MDCT-measured leaflet thickness test is 47.5%.

Conclusion: Along with the assessment of coronary arteries, the presence or absence of MVP can be reliably evaluated by MDCT angiography.

Key Words: Computed tomography, echocardiography, MDCT angiography, mitral valve prolapse

Address for correspondence:

Dr. Masoud Nazari, Department of Radiology, Saint Alzahra Hospital, Isfahan University of Medical Sciences, Isfahan, Iran. E-mail: masoudnazary@yahoo.com

Received: 28.07.2014, Accepted: 08.10.2014

Access this article online	
Quick Response Code:	Website: www.advbiores.net
	DOI: 10.4103/2277-9175.166644

INTRODUCTION

Mitral valve prolapse (MVP) is the most common valvular abnormality, affecting approximately 2 - 6% of the general population.^[1] MVP is asymptomatic in most patients and they have a natural benign history. However, when large, floppy valves or ruptured chordae tendinea result in severe mitral

Copyright: © 2015 Moradi. This is an open-access article distributed under the terms of the Creative Commons Attribution License, which permits unrestricted use, distribution, and reproduction in any medium, provided the original author and source are credited.

How to cite this article: Moradi M, Nazari M, Khajouei AS, Esfahani MA. Comparison of the accuracy of cardiac computed tomography angiography and transthoracic echocardiography in the diagnosis of mitral valve prolapse. *Adv Biomed Res* 2015;4:221

regurgitation, mitral valve surgery or repair may be necessary, that is, pointing the importance of its screening and correct diagnosis, especially in high-risk patients.^[2-4] In fact, high-risk patients such as those with moderate-to-severe mitral regurgitation should be minutely evaluated with regard to the presence of MVP because of their increased risk of cardiac morbidity and mortality, particularly if reduced left ventricular systolic function is present.^[5,6]

Physical examination is often used for MVP diagnosis; it is appreciated by the classic auscultatory finding of a mid-to-late systolic click and/or murmur. Alternatively, it may be incidentally diagnosed during routine echocardiography or discovered when complications of MVP manifest, and thus, this tool has been accepted as the standard tool for diagnosis of this valvular defect.^[7] Echocardiographically, MVP is defined as mitral valve leaflet displacement (billowing) 2 mm or more toward the left atrium in the long axis parasternal view.^[8] Nonetheless, echocardiography has a few inherent limitations, in that, it is dependent on the operator (interobserver variability), patient's size, patient's heart rate, and instrumental settings.^[8,9] In recent times, cardiac multidetector computed tomography (MDCT) has been mainly applied for the diagnosis of valvular heart morphology and function along with the assessment of coronary artery disease.^[10-15] However, a few studies are available on the diagnostic accuracy for MVP using this tool.^[16-18] Hence, the purpose of our study was to evaluate the diagnostic performance of coronary MDCT angiography for the diagnosis of MVP in comparison with transthoracic echocardiography (TTE).

MATERIALS AND METHODS

We performed a retrospective review of the past medical history and previous TTE examinations of the patients, who consecutively referred for cardiac MDCT angiography from August 2013 through March 2014. Patients with documented TTE examinations performed within three months of MDCT angiography were included in the study. With respect to the patient's medical history, no ischemic or other event that might have caused a change in mitral valve status had occurred between TTE and MDCT angiography. Two cardiologists, who were blinded to MDCT, reviewed the TTE results, for confirming the presence or absence of MVP. Leaflet billowing 2 mm or more, beyond the parasternal long-axis annular plane, was confirmed as MVP.

The patients were examined with a 64 section (2 × 32-detector) CT scanner (GE. lightspeed. VCT, General Electrics, USA). The parameters were as follows: Collimation, 2 × 32 × 0.6 mm; section

acquisition, 64 × 0.6 mm; pitch, 0.2; gantry rotation time, 350 msec; tube voltage, 120 kV; and tube current-time product, 600 mAs.

Beta-blockers were administered orally (25–50 mg metoprolol before the examination if the heart rate was more than 65 to 70 beats per minute).

A bolus of 70–100 ml of nonionic iodinated contrast agent, followed by a 40-ml saline flush, was intravenously injected into an antecubital vein at a flow rate of 4 ml/second. The scan delay was calculated by using the bolus-test technique.

The exclusion criteria were renal failure (serum creatinine >1.5 mg/dl), thyroid disorders, sensitivity to iodine, sensitivity to contrast medium, progressed heart failure (New York Heart Association score III-IV), or pregnancy. The study protocol was approved by the Ethics Committee of the Isfahan University of Medical Sciences. All cardiac MDCT examinations were clinically indicated according to the appropriateness criteria of the American College of Cardiology Foundation Quality Strategic Directions Committee Appropriateness Criteria Working Group and the American College of Radiology.^[19]

After performing the MDCT scan along with the assessment of coronary arteries, two parameters of mitral valve leaflet thickness and leaflet billowing were also measured. The reason for this was, the data of 25 and 30% phases of the R-R interval (the systolic phases during which the largest billowing is observed) were sent to an external workstation. Subsequently, the data were post-processed by using the following multiplanar reformations: The three-chamber (CH) plane was generated in the parasternal longitudinal axis, defined as the plane through the long axis of the left ventricle (LV) and the LV outflow tract, which was equivalent to the left coronal oblique view. The two-CH plane was defined as the vertical long-axis orientation in the geometric center of the LV, defined as the plane through the LV, left atrium, and the center of the mitral valve, and was equivalent to the left sagittal oblique view. The four-CH plane was generated from short-axis reformations of the LV, at the middle-LV level, defined as the plane through the center of the LV and the transition between the diaphragmatic and free wall of the right ventricle.

In the systolic phases (25 and 30% of the R-R interval), the maximum perpendicular distance between the leaflets and annular plane of the mitral valve was measured as leaflet billowing in a three-CH view, which was equivalent to the parasternal long-axis view in TTE [Figure 1]. Leaflet displacement toward the

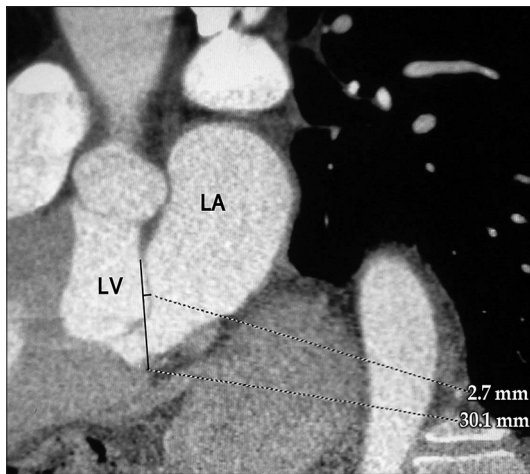


Figure 1: The maximum perpendicular distance between the leaflet and mitral valve annular plane was measured as leaflet billowing

left ventricle was defined as a negative amount and its displacement toward the left atrium was defined as a positive amount.

Leaflet thickness was measured in two-, three-, and four-CH views [Figure 2]. The maximum hypoattenuating thickness of the leaflets was measured with an electronic caliper and calcifications were excluded.

Image interpretation was performed by two independent readers, who were blinded to the results of the TTE.

Transthoracic echocardiography was done using an ultrasonic system (GE Vingmed Ultrasound, VIVID-3, General Electrics, USA).

Transthoracic echocardiography was the reference standard method. MVP was defined as mitral valve leaflet displacement (billowing) 2 mm or more toward the left atrium in the long axis parasternal view. Echocardiographically, mitral valve leaflet thickness was measured in three-CH, four-CH, and two-CH views. The MDCT results were compared with those of TTE, which was the reference standard.

Results were presented as mean \pm standard deviation (SD) for quantitative variables and were summarized by absolute frequencies and percentages for categorical variables. Continuous variables were compared using the *t* test. Categorical variables, on the other hand, were compared using the Chi-square test or Fisher's exact test. The Pearson's correlation test was applied to examine the association between the study measures. Also, the ROC curve analysis was applied for the detection of a cut-off point, and the results of the MDCT angiography for diagnosis of MVP were

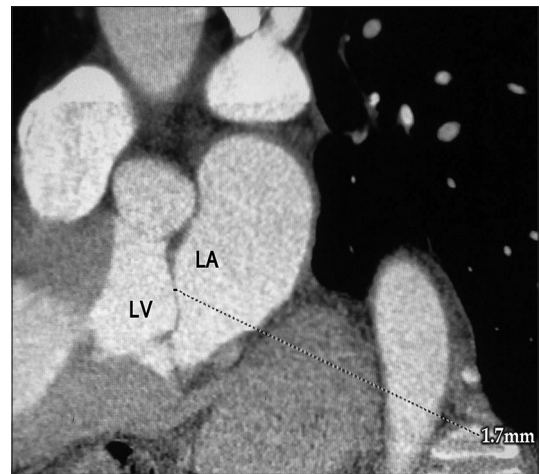


Figure 2: Leaflet thickness was measured with an electronic caliper

compared with those of TTE as the gold standard, and the following values were calculated for each examination: Sensitivity, specificity, false positive, false negative, positive predictive value (PPV), and negative predictive value (NPV). For statistical analysis, the SPSS software (version 20) was used. *P* values of 0.05 or less were considered as statistical significance.

RESULTS

According to the data gathered from the review of the past medical history of the 486 patients, who were referred for and underwent MDCT angiography from August 2013 through March 2014, a total of 312 patients had previously undergone TTE. Thirty-two patients underwent TTE after an MDCT exam. A total of 40 patients who underwent CT and TTE within a three-month period were included in the survey. The MDCT results were compared with those of TTE, which was the reference standard. The results are as follows:

The average age of patients who underwent the survey was 58.75 ± 12.7 (32 to 79) years. Twenty-four individuals (60%) from the mentioned patients were male and 16 (40%) were females. The average ages of the males and females were respectively 54.7 ± 12.8 and 64.9 ± 10.2 years, respectively, and according to the *t*-test, the difference between the ages was significant ($P = 0.011$).

The average of the thickness and billowing of the leaflet measured by TTE were respectively 1.95 ± 0.22 (with 1 to 2 domains) and 1.5 ± 2.28 (with 3 to 7 domains). According to the TTE examination 21 patients (52.5%) had MVP and in 19 patients (47.5%) no MVP were observed. In Table 1, the distribution of demographic characteristics and the amounts achieved from the MDCT examination is seen in two groups of

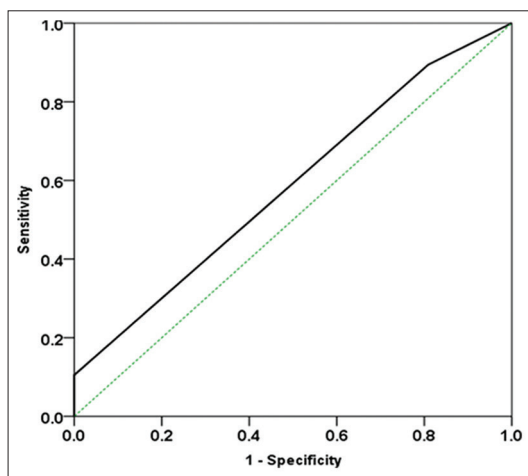
MVP-positive and MVP-negative individuals, based on the results of the TTE test as the reference standard. Performing a *t*-test on the stated data showed that average age and the MDCT-measured leaflet thickness had no significant difference in both the mentioned groups ($P > 0.05$). Also regarding the Chi Square test the gender distribution was not significant in the two groups.

The ROC analysis of the data gathered from MDCT angiography, when compared with the TTE results, indicated that the area under the normal curve for MDCT-measured leaflet thickness equaled 59%, which was not significant ($P = 0.37$). Figure 3 shows the area under the normal curve for MDCT-measured leaflet thickness. Referring to the mentioned test, the best cut point for the MDCT-measured leaflet thickness was 1.5 mm, and based on that, the MDCT-measured leaflet thickness test for diagnosis of prolapse of

Table 1: Demographic variables distribution, and the amounts achieved from MDCT in two groups of MVP positive and MVP negative

TTE result variable	MVP negative	MVP positive	P
Age	58.48±13.5	59.5±12.2	0.89
Sex			
Male	12 (57.1)	12 (63.2)	0.7
Female	9 (42.9)	7 (36.8)	
MDCT measured leaflet thickness (mm)	1.81±0.4	2±0.47	0.18
MDCT measured leaflet billowing (mm)	*-0.43±2.1	3.21±1.9	>0.001

*Leaflet displacement toward the left ventricle was defined as a negative amount and its displacement toward the left atrium was defined as a positive amount. MDCT: Multidetector computed tomography, MVP: Mitral valve prolapse



Area	SE	P	95% CI
0.59	0.09	0.36	0.41-0.76

Figure 3: The area under the ROC curve for MDCT-measured leaflet thickness for diagnosing the mitral valve prolapse

mitral valve had 94.7% sensitivity, 4.8% specificity, 5.3% false positive, 95.2% false negative, 47.4% PPV, and 50% NPV. On the basis of the mentioned test, the consistency of the MDCT-measured leaflet thickness test was 47.5%. Figure 4 shows the diagnostic value amounts for MDCT-measured leaflet thickness, for diagnosing mitral valve prolapse.

Implementing the ROC test on data for MDCT-measured leaflet billowing received from MDCT angiography suggests that the area under the ROC curve is 96% for a declared variable, which is absolutely significant ($P < 0.001$). Figure 5 shows the area under ROC curve for the above-mentioned variable. On the basis of the declared test, MDCT-measured leaflet billowing is an appropriate index for the diagnosis of mitral valve prolapse and based on the achieved cut point from the ROC analysis (which equals 2.5 mm leaflet billowing) the MDCT-measured leaflet billowing takes a sensitivity and specificity of 68.4 and 95.2%. The false positive and false negative are 4.8% and 31.6%, as well. The PPV and NPV of the revealed test are 92.9 and 76.9%, respectively. Finally, the consistency of MDCT-measured leaflet billowing for diagnosing mitral valve prolapse is 82.5%. Figure 6 shows the diagnostic values for MDCT-measured leaflet billowing for diagnosing mitral valve prolapse.

On the basis of the gathered data, a 68% direct correlation is observed between leaflet thickness measured by TTE and MDCT angiography, which according to the Pearson test is significant. With regard to the mentioned test, the correlation between leaflet billowing measured by TTE and MDCT angiography is 94%, which is significant ($P < 0.001$).

DISCUSSION

In our study, the diagnostic performance of MDCT

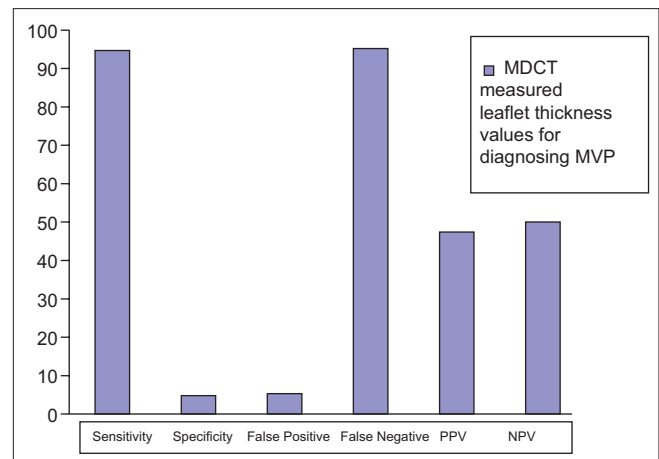
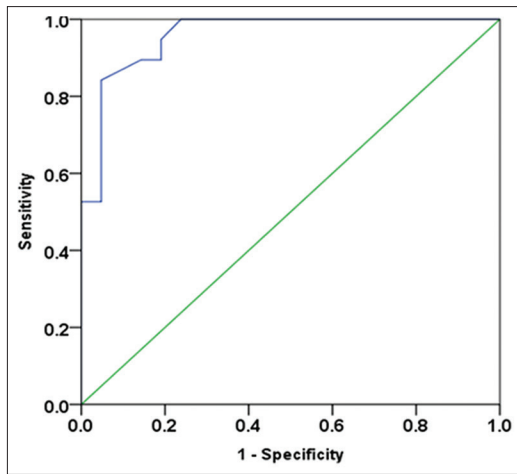


Figure 4: Diagnostic value amounts for MDCT-measured leaflet thickness for diagnosing mitral valve prolapse



Area	SE	P	95% CI
0.96	0.028	>0.001	0.9-1

Figure 5: The area under the ROC curve for MDCT-measured leaflet billowing, for diagnosing the mitral valve prolapse

angiography in comparison with transthoracic echocardiography, for detecting MVP, was assessed. In fact, two statistical analyses were employed for this aim. First, the linear correlation of the measures of two valvular parameters including leaflet thickness and leaflet billowing, which were measured by two diagnostic methods, were assessed by the Pearson's correlation test. This statistical test showed a strong positive association in the parameters pointed out, between the two procedures. Furthermore, the diagnostic value of MDCT angiography in comparison with transthoracic echocardiography was also assessed by the statistical cross-tabulation method, indicating a high specificity and also an acceptable sensitivity of MDCT angiography for detecting MVP, which was consistent with the previous reports.

On the basis of the results of our study, the MDCT angiography sensitivity in diagnosing MVP was 68.4%. In the Shah *et al.* study in US, which included 20 patients, this value was reported to be 69.2%.^[18]

Ghosh *et al.* had conducted a study in Canada. Sixty-seven patients participated in that research to identify the MDCT sensitivity for diagnosing MVP, which was found to be 92%.^[16] In Feuchtner *et al.*'s study in Austria, 112 individuals participated and the sensitivity of the test was 96%.^[17]

On the whole, it seems that the more patients in the study (larger sample volume) the more the sensitivity that has been observed.

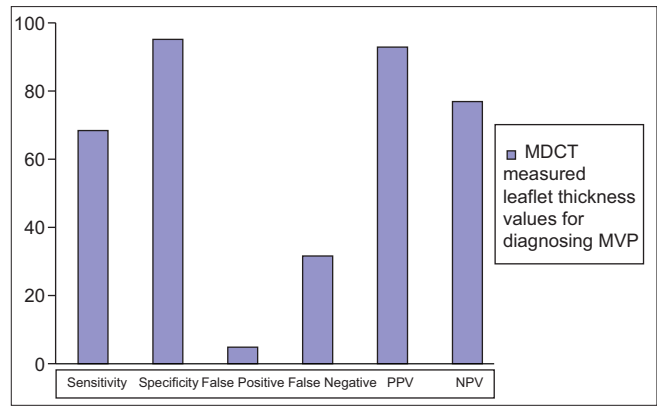


Figure 6: Diagnostic value amounts for MDCT-measured leaflet billowing for diagnosis of mitral valve prolapse

Compared with the previous studies, an almost reasonable sensitivity was achieved in our study for diagnosing MVP.

A high sensitivity value is required for tests used for screening common diseases with high morbidity and mortality, such as, diabetes, hypertension, breast cancer, and the like. MVP does not seem to need to be screened, although, larger researches with more samples are suggested.

The achieved specificity for MDCT angiography in diagnosing MVP, in our study, was 95.2%. In the studies by Shah, Ghosh, and Feuchtner *et al.* this was found to be 100%, 97.1%, and 93%, respectively.^[16-18] This amount in our study was consistent with the previous studies, and overall, showed a high capability of this method in the diagnosis of MVP. This indicated that this diagnostic method was reliable for detecting MVP and faced little false-positive cases.

Even as this method's PPV is high (92.9% in present study), in case of detecting billowing of the mitral valve in MDCT angiography (more than 2.5 mm according to our study), a diagnosis of MVP may be proposed.

In the previous studies PPV has been estimated to be 87, 80, and 93%.^[16-18]

In our study NPV was achieved at 76.9%, which is consistent with the previous studies, which have shown 80, 83, and 91%.^[16-18]

A more or less high correlation between the measured valve thicknesses by the two methods of MDCT angiography and TTE was observed (64%) that indicated the reliability of this test in the diagnosis of mitral valve thickness.

The overall accuracy of MDCT angiography in diagnosing MVP in the present study was 82.5%, which pointed to the reliability of this test in diagnosing MVP.

It has to be mentioned that in comparison to TTE, MDCT has some disadvantages, such as, radiation exposure, side effects of contrast media administration, and high costs; therefore, it is not reasonable to perform it just to evaluate MVP, and it is not recommended either. Yet, for patients who are referred for MDCT angiography along with assessment of coronary arteries, the presence or absence of MVP can be reliably evaluated too, which may provide useful information to clinicians, to manage the patients.

REFERENCES

1. American College of Cardiology/American Heart Association. ACC/AHA 2006 guidelines for the management of patients with valvular heart disease. A report of the American College of Cardiology/American Heart Association Task Force on Practice Guidelines (writing committee to revise the 1998 guidelines for the Manag. J Am Coll Cardiol 2006;48:1-148.
2. Perloff JK, Child JS, Edwards JE. New guidelines for the clinical diagnosis of mitral valve prolapse. Am J Cardiol 1986;57:1124-9.
3. Freed LA, Levy D, Levine RA, Larson MG, Evans JC, Fuller DL, *et al.* Prevalence and clinical outcome of mitral-valve prolapse. N Engl J Med 1999;341:1-7.
4. Izumo M, Shiota M, Kar S, Gurudevan SV, Tolstrup K, Siegel RJ, *et al.* Comparison of real-time three-dimensional transesophageal echocardiography to two-dimensional transesophageal echocardiography for quantification of mitral valve prolapse in patients with severe mitral regurgitation. Am J Cardiol 2013;111:588-94.
5. Avierinos JF, Gersh BJ, Melton LJ 3rd, Bailey KR, Shub C, Nishimura RA, *et al.* Natural history of asymptomatic mitral valve prolapse in the community. Circulation 2002;106:1355-61.
6. Ciancamerla F, Paglia I, Catuzzo B, Morello M, Mangiardi L. Sudden death in mitral valve prolapse and severe mitral regurgitation. Is chordal rupture an indication to early surgery? J Cardiovasc Surg (Torino) 2003;44:283-6.
7. Devereux RB. Recent developments in the diagnosis and management of mitral valve prolapse. Curr Opin Cardiol 1995;10:107-16.
8. Freed LA, Benjamin EJ, Levy D, Larson MG, Evans JC, Fuller DL, *et al.* Mitral valve prolapse in the general population: The benign nature of echocardiographic features in the Framingham Heart Study. J Am Coll Cardiol 2002;40:1298-304.
9. Devereux RB, Kramer-Fox R, Brown WT, Shear MK, Hartman N, Kligfield P, *et al.* Relation between clinical features of the mitral prolapse syndrome and echocardiographically documented mitral valve prolapse. J Am Coll Cardiol 1986;8:763-72.
10. Levine RA, Stathogiannis E, Newell JB, Harrigan P, Weyman AE. Reconsideration of echocardiographic standards for mitral valve prolapse: Lack of association between leaflet displacement isolated to the apical four chamber view and independent echocardiographic evidence of abnormality. J Am Coll Cardiol 1988;11:1010-9.
11. Janne d'Othée B, Siebert U, Cury R, Jadvar H, Dunn EJ, Hoffmann U. A systematic review on diagnostic accuracy of CT-based detection of significant coronary artery disease. Eur J Radiol 2008;65:449-61.
12. Raff GL, Gallagher MJ, O'Neill WW, Goldstein JA. Diagnostic accuracy of noninvasive coronary angiography using 64-slice spiral computed tomography. J Am Coll Cardiol 2005;46:552-7.
13. Alkadhi H, Wildermuth S, Bettex DA, Plass A, Baumert B, Leschka S, *et al.* Mitral regurgitation: Quantification with 16-detector row CT – Initial experience. Radiology 2006;238:454-63.
14. Messika-Zeitoun D, Serfaty JM, Laissy JP, Berhili M, Brochet E, Lung B, *et al.* Assessment of the mitral valve area in patients with mitral stenosis by multislice computed tomography. J Am Coll Cardiol 2006;48:411-3.
15. Wheatley GH 3rd, Opie SR, Maas D, Sutherland J, Diethrich EB. Detection of unsuspected mitral valve prolapse using 64 multi-slice computed tomography. Ann Thorac Surg 2007;83:1555.
16. Ghosh N, Al-Shehri H, Chan K, Mesana T, Chan V, Chen L, *et al.* Characterization of mitral valve prolapse with cardiac computed tomography: Comparison to echocardiographic and intraoperative findings. Int J Cardiovasc Imaging 2012;28:855-63.
17. Feuchtnner GM, Alkadhi H, Karlo C, Sarwar A, Meier A, Dichtl W, *et al.* Cardiac CT angiography for the diagnosis of mitral valve prolapse: Comparison with echocardiography¹. Radiology 2010;254:374-83.
18. Shah RG, Novaro GM, Blandon RJ, Wilkinson L, Asher CR, Kirsch J. Mitral valve prolapse: Evaluation with ECG-gated cardiac CT angiography. AJR Am J Roentgenol 2010;194:579-84.
19. Hendel RC, Patel MR, Cramer CM, Poon M, Hendel RC, Carr JC, *et al.* American College of Cardiology Foundation Quality Strategic Directions Committee Appropriateness Criteria Working Group; American College of Radiology; Society of Cardiovascular Computed Tomography; Society for Cardiovascular Magnetic Resonance; American Society of Nuclear Cardiology; North American Society for Cardiac Imaging; Society for Cardiovascular Angiography and Interventions; Society of Interventional Radiology. ACCF/ACR/SCCT/SCMR/ASNC/NASCI/SCAI/SIR 2006 appropriateness criteria for cardiac computed tomography and cardiac magnetic resonance imaging: A report of the American College of Cardiology Foundation Quality Strategic Directions Committee Appropriateness Criteria Working Group, American College of Radiology, Society of Cardiovascular Computed Tomography, Society for Cardiovascular Magnetic Resonance, American Society of Nuclear Cardiology, North American Society for Cardiac Imaging, Society for Cardiovascular Angiography and Interventions, and Society of Interventional Radiology. J Am Coll Cardiol 2006;48:1475-97.

Source of Support: Nil, Conflict of Interest: None declared.