

Evaluating Accuracy of Free-hand Pedicle Screw Insertion in Adolescent Idiopathic Scoliosis Using Postoperative Multi-Slice Computed Tomography Scan

Abstract

Background: Pedicle screw instrumentation has many advantages for correction of adolescent idiopathic scoliosis (AIS) deformity including better correction and fewer late complications. On the other hand, screw insertion in AIS is challenging. Intraoperative fluoroscopy or navigation techniques are expensive, time-consuming, and exposed to high radiation. Free-hand technique relies on the surgeon's experience and locating the pedicle entry point with anatomical landmarks. There are few studies that evaluated pedicle screw position accuracy with postoperative multi-slice computed tomography scan. **Materials and Methods:** We prospectively considered 38 consecutive AIS cases, who underwent corrective surgery with all pedicle screw technique. All the screws were inserted with free-hand technique using anatomic landmarks as a guide for an entry site. We divided pedicle penetration in medial, lateral, inferior, superior, and anterior vertebral body as Grades 0–4, that Grade 0 is fully contained within the pedicle, Grade 1 (<2 mm), Grade 2 (2.1–4 mm), Grade 3 (4.1–6 mm), and Grade 4 (>6 mm). **Results:** A total of 720 screws were inserted, of which 623 screws (86.5%) were perfect and 97 screws (13.5%) were misplaced. Of those which were misplaced, 39 screws (40.2%) were medial and 58 (59.8%) were lateral, which shows that the prevalence of lateral misplacement was more in comparison to medial misplacement. However, in all misplaced cases, the deviation of the screw was <2 mm (Grade 1). There was no misplacement in the inferior and superior. **Conclusion:** Pedicle screw insertion in AIS with the free-hand technique is a safe and reliable method.

Keywords: Free-hand technique, pedicle screw, scoliosis

Mohammadreza Etemadifar, Mohammadhossein Jamalaldini

From the Department of Orthopedic and Spine Surgery, Al-Zahra Hospital, Isfahan University of Medical Sciences, Isfahan, Iran

Introduction

Use of pedicle screw as an anchor for spinal fixation has become popular during the last two decades. It was first utilized in the lumbar spine and subsequently, in thoracic spine surgery. Pedicle screw presents many advantages over other spine anchors such as hook or sublaminar wires regarding better purchase and more pull-out strength. Using pedicle screws to surgically correction of the adolescent idiopathic scoliosis (AIS) allows an enhanced three-dimensional deformity correction. It may also preserve more motion segments by reducing the number of levels requiring fusion and may have less correction loss.^[1-3]

Another advantage of the pedicle screw is a lower incidence of pseudarthrosis and less operation time. Although pedicle screws have multiple advantages and have become popular, the proximity of pedicles to the spinal canal and surrounding major

vessels makes the accurate placement of screws within the confines of the pedicle of paramount importance.^[4-6]

Accurate placement of pedicle screws in deformed spine poses unique challenges. The breach rates for thoracic pedicle screw placement vary from 1.5% to 58%.^[7-9] Suk *et al.* reported a breach rate of 1.5% on a total 4604 pedicle screws; however, the vast majority of these were elevated via plain X-rays.^[10] However, using postoperative computed tomography (CT)-scan, Belmont *et al.* reported a breach rate of 58% in patients with coronal deformity.^[8] This large variability probably reflects the radiographic method used to detect a breach, with plain X-ray under-estimating the incidence.

A few other studies have reported breach rates for thoracic pedicle screw placement in scoliosis utilizing postoperative CT-scan.^[11-14] While many studies have

Address for correspondence: Dr. Mohammadhossein Jamalaldini, Department of Orthopedic and Spine Surgery, Al-Zahra Hospital, Isfahan University of Medical Sciences, Isfahan, Iran. E-mail: smjamalaldini@gmail.com

This is an open access article distributed under the terms of the Creative Commons Attribution-NonCommercial-ShareAlike 3.0 License, which allows others to remix, tweak, and build upon the work non-commercially, as long as the author is credited and the new creations are licensed under the identical terms.

For reprints contact: reprints@medknow.com

How to cite this article: Etemadifar M, Jamalaldini M. Evaluating Accuracy of Free-hand Pedicle Screw Insertion in Adolescent Idiopathic Scoliosis Using Postoperative Multi-Slice Computed Tomography Scan. *Adv Biomed Res* 2017;6:19.

Received: July, 2016. **Accepted:** May, 2016.

Access this article online

Website: www.advbiores.net

DOI: 10.4103/2277-9175.201331

Quick Response Code:



revealed that placing pedicle screws in the thoracic and lumbar spine is safe, there are still unique challenges based on the morphometry of the deformed thoracic spine.^[5,6]

As a result, several techniques have been developed to insert pedicle screws, including fluoroscopic or CT guidance and direct visualization with the use of laminotomies to identify key anatomic landmarks.^[3,12] In free-hand technique, the surgeon relies on appreciation of normal and abnormal spinal anatomy, preoperative imaging, and intraoperative anatomical landmarks. The current study is aimed to assess the accuracy of free-hand pedicle screw insertion in AIS via multi-slice CT-scan and record the incidence of misplacement and its related complications.

Materials and Methods

Following the Institutional Review Board and ethical approval, this study was conducted in St. Zahra Hospital, Isfahan University of Medical Sciences. This prospective study included 38 consecutive patients, aged between 10 and 20 years (15.53 ± 2.38), who entailed six (15.8%) males and 32 (84.2%) females. Since the study participants were diagnosed with AIS (inclusive criteria), they underwent transpedicular screw fixation for AIS from January 2013 to June 2015 that all screws were inserted by the senior author (M.E). The patients diagnosed with such other cases as congenital scoliosis, infection, trauma, tumor, and history of spine surgery were excluded from the study. The curves were classified according to the Lenke's classification via applying preoperative radiographs consisting of three foot standings of posterior–anterior, lateral.

Surgical technique

The patients were placed prone on a radiolucent frame with two soft radiolucent posts under their pelvis and chest to facilitate intraoperative imaging, maintain adequate sagittal alignment, and minimize any pressure to anterior thorax and abdomen.

A posterior midline incision was made, and the subperiosteal dissection was carried out to expose posterior elements. With 10 mm osteotome, the distal half of inferior articular process, which overhangs the base of the superior articular process, was removed. Therefore, the superior articular process was exposed from lateral to the medial part. Using the exposed osseous anatomy as a reference, all pedicle screws were inserted using free-hand technique.

The technique popularized by Kim *et al.* requires definition of the posterior element bony landmarks including the lateral border of the pars-interarticularis, transverse process, and superior articular facet rule.^[13] The entry points in thoracic spine were about 2 mm lateral midpoint superior facet and at the superior border of a transverse process for T1–T10 or midline of transverse process at T11–T12 defined the pedicle entrance point. In the lumbar spine, midpoint of the transverse process and its intersection with

the lateral pars-interarticularis was chosen as the entry point.

Following determination of entry point, a high-speed burr is used to penetrate the outer cortex over the pedicle entry point. Afterward, narrow curette or special thoracic pedicle probe was used to determine the pedicle trajectory. We used a straight pedicle probe except in periapical segments with rotated vertebra when we used a curved probe. Normally, after passing the pedicle through the body, there was a more smooth feeling in the surgeon's hands. The resulting pedicle tract was palpated with ball-tipped probe to verify the presence of any cortical breaches as well as to check for appropriate screw length. If a violation of bony cortices was noted at this point, the probe was redirected perpendicular to the plane of the superior articular facet and followed a path of least resistance in variably medial and caudal inclination to assure the safe screw placement.

If the pedicle screw was not self-tapping, the pedicle path was tapped and the tract was palpated again with the ball-tipped probe to detect any bony breaches. Instrumentation consisted of titanium mono- and poly-axial screws and rods. Then, all the screws were applied on one side, intraoperative imaging was taken by C-arm to verify acceptable screw positioning in two planes. We instrumented all of vertebrae on the concave side and all or every other level on the convex sides of thoracic curves and almost all levels in the lumbar spine.

Deformity correction was performed using a lateral cantilever, rod derotation–translation *in situ* bending, as well as minor compression or distraction if necessary. After correction, wake-up test was performed. Finally, decortications of all lamina and facet joints were done and local autologous bone graft mixed with allograft was applied to the decorticated surfaces. Once the patient managed to become stable, postoperative radiographs and a 2 mm multi-slice CT-scan were performed.

A spine fellow (S.M.J) independently reviewed radiographs and CT-scans using the picture archiving and communication system at magnification of 300%. Moreover, any penetration of the cortex was measured in millimeters. Apex rotation was measured with a perdrille torsion meter.

Penetration of the pedicle walls was classified into medial and lateral using a Grade 0–4 classification system [Figure 1]. Grade 0 was fully contained within the pedicle, Grade 1 had <2 mm of penetrations, Grade 2 involved 2.1–4 mm of penetrations, Grade 3 had 4.1–6 mm of penetrations, and a Grade 4 had over 6.1 mm of penetrations. Screw penetration anterior or lateral to the vertebral body was measured in the same manner. In addition, sagittal slices were reviewed to detect superior or inferior breaches.

The presence of radicular pain, neurological deficits, dural tears, and vascular or visceral injury was noted. Revision

surgeries due to screw misplacement were also noted and recorded. To analyze the study data, Chi-square test was utilized.

Results

In this study, 38 idiopathic scoliosis patients with an average age of 15.53 ± 2.38 years (range: 10–20 years old) were studied, among which, six (15.8%) patients were males and 32 (84.2%) were females. Based on the Lenke’s classification, the curve in 17 patients was (44.7%) type 1, in three (7.9%) was type 2 and in the rest which were six (15.8%) were types 3, 4, 5, and 6.

According to the results, the most common locations were in the thoracic region with 12 cases (31.6%), thoracolumbar and lumbar regions with frequency of ten cases (26.3%). Four patients had curves in the thoracolumbar area and four within the upper thoracic and thoracolumbar. Two patients had a deviation of the lumbar region, two patients in the upper thoracic and thoracic, two patients in the upper thoracic and thoracolumbar, and two patients also had curve in thoracic and thoracolumbar region. The frequency of curves is depicted in Figure 2.

The mean Cobb’s angle of the curve in the upper thoracic region was $29 \pm 20.11^\circ$, in the thoracic region was $59.69 \pm 13.77^\circ$, in the thoracolumbar region was $53.25 \pm 10.62^\circ$, and in lumbar region was $47.38 \pm 15.14^\circ$. Figure 3 indicates the average deviation of the spine in patients.

Table 1 shows the mean angle of kyphosis and scoliosis and standard deviation, before and after the intervention. The average of thoracic kyphosis angle and also the amount of thoracic and lumbar scoliosis, after the intervention than before surgery has a significant difference. It is noteworthy that the average of curve size in thoracic bending curves was $33.88 \pm 22.18^\circ$ and in lumbar curves was $25.87 \pm 18.38^\circ$.

The frequency of marked screw characteristics is shown in Table 2. Apex location of the curve in twenty patients (52.6%) was thoracic, in four patients (10.5%) was lumbar and in 14 patients (36.8%) was thoracolumbar. The mean vertebral rotation in patients was $32.44 \pm 12.09^\circ$ in the range of 5–45°. The most common location of the screw was observed at the L1-T2 level [Table 2].

In Figure 4, the frequency of perfect is shown based on their concavity and convexity. Figure 4 demonstrates, in general, accuracy of screw placement on the convexity and concavity revealed no significant difference ($P < 0.001$). Yet in the upper thoracic region, the accuracy of screw placement on the right side was more observed than the left side. In the thoracic region, excluding T7, the accuracy of the screw on the convex curves, was more than the concavity. In the thoracolumbar area, the T11 and T12 vertebrae, the accuracy of screw placement at the left curves

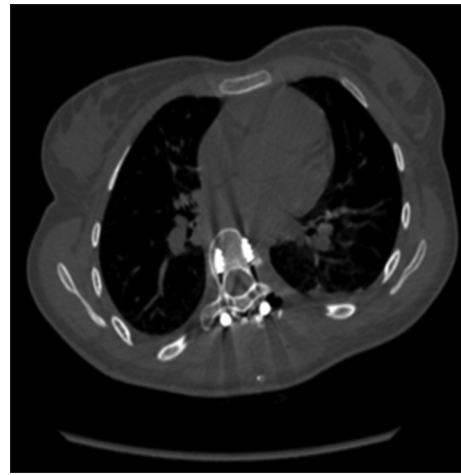

Figure 1: Right perfect screw within the pedicle and body, left screw is Grade 1 lateral misplace

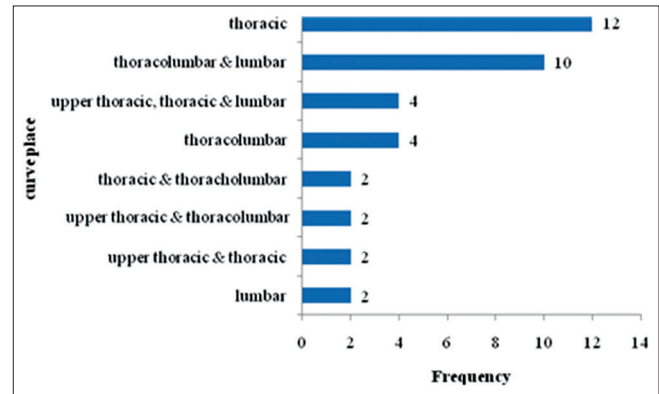


Figure 2: The curves frequency in patients under study

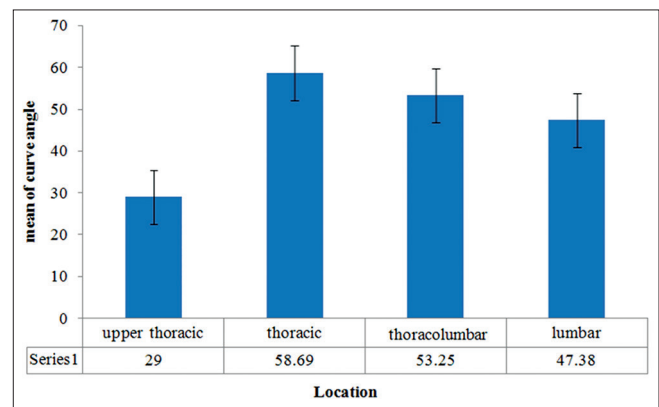


Figure 3: The mean deviation angle of the spine

(convexity) was more, however, in the lumbar region, the accuracy of screw placement at the right curves (concavity) was more. It is worth mentioning that the number of screws placed on the left side of T2 vertebrae was totally 1 including 2 perfect and 2 misplacement.

In this study, a total of 720 screws were placed in terms of surgical treatment of idiopathic scoliosis. The study results indicate that 623 screws (86.52%) were perfect

and 97 (13.5%) had misplacement. Of those which were misplaced, 39 (40.2%) were medial and 58 (59.8%) were lateral which shows that the prevalence of lateral misplacement was more in compared to medial [$P = 0.034$, Table 3].

In all misplaced cases, the screw deviation was <2 mm. Table 3 presents the number of screws in four areas of the spine, the most percentage of misplacement was observed in level I with a frequency of 19.1%. Based on the Chi-square test results, the frequency of misplacement

Table 1: Mean angle and standard deviation of thoracic and lumbar scoliosis and the amount of spinal curvature before and after surgery

Place	Before	After	P
Thoracic scoliosis	59.69±13.77	17.38±8.48	<0.001
Lumbar scoliosis	47.38±15.14	19.13±15.14	<0.001

Table 2: Profile of the marked screw in the under study cases

Variables	Level	n	Percentage
Apex level	Thoracic	20	52.6
	Lumbar	4	10.5
	Thoracolumbar	14	36.8
Rotation degree		32.48	12.09
Pedicular screw level	T2 to L1	8	21.1
	T11 to L3	2	5.3
	T8 to L3	2	5.3
	T6 to L3	4	10.5
	T3 to L3	4	10.5
	T3 to L1	4	10.5
	T2 to L2	4	10.5
	T3 to L4	4	10.5
	T5 to L3	2	5.3
	T1 to L1	2	5.3
	T5 to L2	2	5.3

Table 3: Frequency of misplacement and the grade of misplacement according to the screw level

Level	Total screws	Perfect	Misplacement	Kind of misplacement	
				Medial	lateral
I (upper thoracic)	94	79 (80.9)	15 (19.1)	0 (0)	15 (100)
II (middle thoracic)	224	189 (84.4)	35 (15.6)	15 (42.9)	20 (57.1)
III (lower thoracic)	226	196 (86.7)	30 (13.3)	9 (30)	21 (70)
IV (lumbar)	176	159 (90.3)	17 (9.7)	15 (88.2)	2 (11.8)
Total	720	623 (86.52)	97 (13.48)	39 (40.21)	58 (59.79)
P			0.045		0.034

revealed a statistically significant difference with regard to the areas so as the upper thoracic was proved to be significantly higher ($P = 0.045$). Moreover, a significant difference was observed in misplacement type regarding level ($P = 0.034$). Notably, there was no misplacement in the inferior and superior sides, whereas only one 4 mm anterior misplacement was found to be associated with abdominal pain that the screw was removed and replaced from the site. Since only one case was present, it was not included in the statistical analysis so as to prevent any corruption in the statistical analysis of the study data.

Figure 5 displays the frequency of the screw placement at the apex area, the most abundant apex cases were reported for T8 for thoracic curve and L2 for the lumbar curve. Table 4 demonstrates frequency distribution of the screw placed on each vertebra, the number of screws placed on the apex of each vertebra, as well as the percentage of perfect ones. The results of the Fisher's exact test indicated that the frequency of the perfect cases was not significantly different between apical and nonapical vertebra (despite more rotation on the apical vertebra).

Discussion

Since the introduction of pedicle screws to treat spinal deformities in 1992, they seem to have been the standard of care due to definitive advantages such as improved correction, better fixation, and their capability to perform safe osteotomies.

As a matter of fact, pedicle anatomy is highly variable in spinal deformity in which successful screw placement regarded more challenging.^[1,6,15]

Misplaced screws pose a potential danger to the surrounding vital structures such as the aorta, lung, and neural tissues. In addition, screw misplacement diminishes the pull-out strength of implant and increases the chance of implant failure.^[16,17]

To improve the accuracy of thoracic pedicle screws, various techniques have been proposed such as fluoroscopic and CT guidance surgery, intraoperative electromyography, somatosensory, and motor-evoked potential monitoring.^[5,10,18]

Image-guided techniques are regarded expensive, and time-consuming, which pose the inherent risks of radiation exposure. In contrary, free-hand technique is simple, cost-effective, and accurate in experienced hands.^[5,12,18]

Variable rates of misplacement shown in most studies are due to various postoperative investigations, but CT-scans have been found to be more reliable than radiographs. Hence, the present study intended to benefit from CT-scans.^[19,20]

Studies focused on the accuracy of placing pedicle screws, have shown high variability in misplacement rates (6–41%).

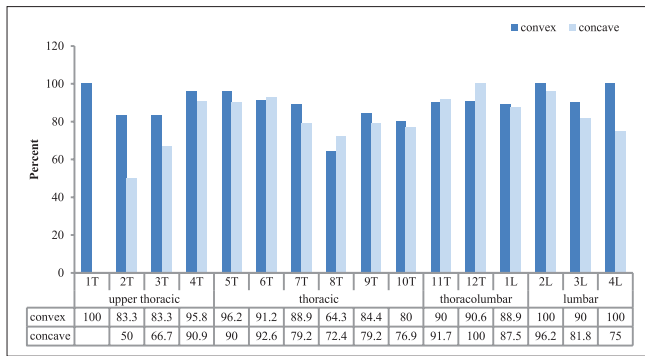


Figure 4: The frequency of the accuracy of screw placement in four areas of the spine

Suk *et al.* reported only 67 screw appositions (1.5%) in 48 patients treated for idiopathic and congenital scoliosis using the postoperative radiographs.^[9,10]

Kim *et al.* reported 93.8% accuracy in thoracic pedicle screw fixation in patients with AIS and Scheuermann’s kyphosis using the free-hand technique which was assessed by the postoperative CT-scan.^[4,5,13]

In another study, Belmont *et al.* reported 99% accuracy in thoracic pedicle screw fixation within the safe zone (perfect or <2 mm displacement).^[8]

The percentages of screw misplacement between the various levels in thoracic spine also did not vary much as it was expected. In our study, the misplacement rates were 19.1%, 15.6%, 13.3%, and 9.7% with perfect rates of 80.9%, 84.4%, 86.7%, and 90.3% in the upper, middle, and lower thoracic and lumbar regions, respectively. Interestingly, our misplacement rate was higher in the upper thoracic region despite literature reporting the mid-thoracic pedicle screws as the narrowest.^[10,21]

Kuklo *et al.* reported that perfect screw or breach of <2 mm in 96.3% of screws were assessed by CT-scan in thoracic spine without any complications.^[21,22]

Gertzbein and Robbins’ study of 71 thoracic screws had a 26% incidence of medial cortical penetration of up to 8 mm with only two minor neurologic injuries. Consequently, they postulated a 4 mm safe zone medial encroachment and 6 mm lateral safe zone.^[17]

Regarding the thoracic spine, the study findings revealed 13.5% of screws with Grade 1 (≤ 2 mm) pedicle wall perforation of which 40.2% were medial and 59.8% were lateral.^[6,13] Therefore, the accuracy rate was 86.52%, however if we consider up to a 2 mm breach on either the medial or lateral side to be safe, then all screws were in the safe zone. We therefore conclude that in experienced hands the free-hand technique can be safely used for accurate placement of pedicle screws in thoracic spine of patients undergoing scoliosis surgery for AIS.

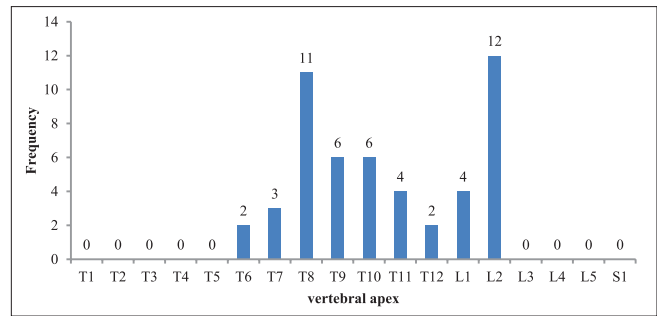


Figure 5: The apex frequency for thoracic and lumbar curves

Table 4: The frequency of screw placement perfect cases based on the curves apex

Vertebra	Total screw	Perfect	Total apex	Perfect	P
T7	60	51 (85)	4	2 (50)	0.08
T8	57	39 (68.4)	22	15 (68.2)	0.45
T9	56	46 (82.1)	16	13 (81.3)	0.78
T10	56	44 (78.6)	7	5 (71.4)	0.53
T11	54	49 (90.7)	2	2 (100)	0.9
T12	60	57 (95)	5	5 (100)	0.87
L1	68	60 (88.2)	4	4 (100)	0.75
L2	50	49 (98)	14	13 (92.9)	0.11

In general, the surgeons rely on numerous modalities intraoperatively, when deciding on the accuracy of the pedicle screw including the harmonious arc of the screws, tactile feedback via pedicle probe and intraoperative C-arm. Apical pedicles are the most deformed and difficult in scoliosis cases. Interestingly, the misplacement rate for these pedicles was similar to overall misplacement rate. However, a higher breach rate with the pedicles was observed on the concavity of deformity. This was mirrored by Smorgick *et al.* who reported a higher breach rate in regard to the concave thoracic pedicle screws.^[1]

Screws with lateral or medial penetration and without neurologic deficit do not need revision provided have good purchase, whereas screws with anterior penetration of vertebral body may need to be revised proximity of the great vessels. Fortunately, this problem has rarely been reported.

In this study, we revised one screw near aorta at the T11 vertebra that was seen in CT-scan. Although the patient had normal hemodynamic circumstances, she was complaining of abdominal discomfort [Figure 6].

Conclusion

Pedicle screw insertion in AIS can be performed via free-hand technique safely and accurately without any time expenses and radiation exposures. In addition, any neurologic, vascular and visceral complication was not reported in the current study which should be taken into consideration by spine surgeons during thoracic pedicle screw fixation.

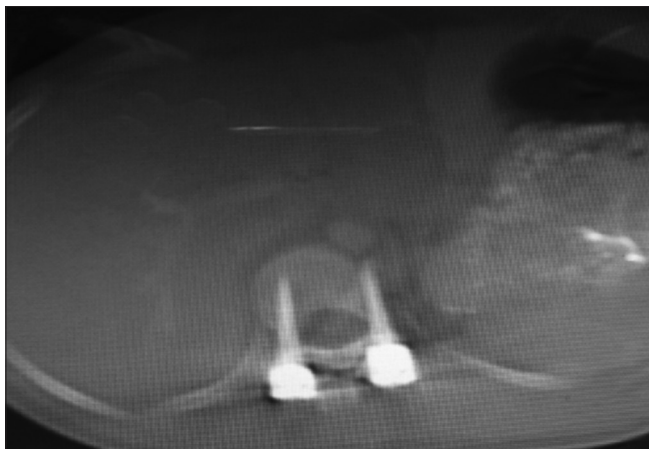

Figure 6: The T11 vertebra screw adjusts aorta was revised

Financial support and sponsorship

Nil.

Conflicts of interest

There are no conflicts of interest.

References

- Smorgick Y, Millgram MA, Anekstein Y, Floman Y, Mirovsky Y. Accuracy and safety of thoracic pedicle screw placement in spinal deformities. *J Spinal Disord Tech* 2005;18:522-6.
- Liljenqvist U, Lepsien U, Hackenberg L, Niemeyer T, Halm H. Comparative analysis of pedicle screw and hook instrumentation in posterior correction and fusion of idiopathic thoracic scoliosis. *Eur Spine J* 2002;11:336-43.
- Kim YJ, Lenke LG, Kim J, Bridwell KH, Cho SK, Cheh G, *et al.* Comparative analysis of pedicle screw versus hybrid instrumentation in posterior spinal fusion of adolescent idiopathic scoliosis. *Spine (Phila Pa 1976)* 2006;31:291-8.
- Lenke LG, Kuklo TR, Ondra S, Polly DW Jr. Rationale behind the current state-of-the-art treatment of scoliosis (in the pedicle screw era). *Spine (Phila Pa 1976)* 2008;33:1051-4.
- Kim YJ, Lenke LG, Bridwell KH, Cho YS, Riew KD. Free hand pedicle screw placement in the thoracic spine: Is it safe? *Spine (Phila Pa 1976)* 2004;29:333-42.
- Esses SI, Sachs BL, Dreyzin V. Complications associated with the technique of pedicle screw fixation. A selected survey of ABS members. *Spine (Phila Pa 1976)* 1993;18:2231-8.
- Hyun SJ, Kim YJ, Cheh G, Yoon SH, Rhim SC. Free hand pedicle screw placement in the thoracic spine without any radiographic guidance: Technical note, a cadaveric study. *J Korean Neurosurg Soc* 2012;51:66-70.
- Belmont PJ Jr., Klemme WR, Robinson M, Polly DW Jr. Accuracy of thoracic pedicle screws in patients with and without coronal plane spinal deformities. *Spine (Phila Pa 1976)* 2002;27:1558-66.
- Suk SI, Kim WJ, Lee SM, Kim JH, Chung ER. Thoracic pedicle screw fixation in spinal deformities: Are they really safe? *Spine (Phila Pa 1976)* 2001;26:2049-57.
- Suk SI, Lee CK, Kim WJ, Chung YJ, Park YB. Segmental pedicle screw fixation in the treatment of thoracic idiopathic scoliosis. *Spine (Phila Pa 1976)* 1995;20:1399-405.
- Wiesner L, Kothe R, Schulitz KP, Rütther W. Clinical evaluation and computed tomography scan analysis of screw tracts after percutaneous insertion of pedicle screws in the lumbar spine. *Spine (Phila Pa 1976)* 2000;25:615-21.
- Schulze CJ, Munzinger E, Weber U. Clinical relevance of accuracy of pedicle screw placement. A computed tomographic-supported analysis. *Spine (Phila Pa 1976)* 1998;23:2215-20.
- Kim YJ, Lenke LG, Cheh G, Riew KD. Evaluation of pedicle screw placement in the deformed spine using intraoperative plain radiographs: A comparison with computerized tomography. *Spine (Phila Pa 1976)* 2005;30:2084-8.
- Choma TJ, Denis F, Lonstein JE, Perra JH, Schwender JD, Garvey TA, *et al.* Stepwise methodology for plain radiographic assessment of pedicle screw placement: A comparison with computed tomography. *J Spinal Disord Tech* 2006;19:547-53.
- Abul-Kasim K, Ohlin A, Strömbeck A, Maly P, Sundgren PC. Radiological and clinical outcome of screw placement in adolescent idiopathic scoliosis: Evaluation with low-dose computed tomography. *Eur Spine J* 2010;19:96-104.
- Belmont PJ Jr., Klemme WR, Dhawan A, Polly DW Jr. *In vivo* accuracy of thoracic pedicle screws. *Spine (Phila Pa 1976)* 2001;26:2340-6.
- Gertzbein SD, Robbins SE. Accuracy of pedicular screw placement *in vivo*. *Spine (Phila Pa 1976)* 1990;15:11-4.
- Farber GL, Place HM, Mazur RA, Jones DE, Damiano TR. Accuracy of pedicle screw placement in lumbar fusions by plain radiographs and computed tomography. *Spine (Phila Pa 1976)* 1995;20:1494-9.
- Vaccaro AR, Rizzolo SJ, Balderston RA, Allardyce TJ, Garfin SR, Dolinskas C, *et al.* Placement of pedicle screws in the thoracic spine. Part II: An anatomical and radiographic assessment. *J Bone Joint Surg Am* 1995;77:1200-6.
- Rajasekaran S, Vidyadhara S, Ramesh P, Shetty AP. Randomized clinical study to compare the accuracy of navigated and non-navigated thoracic pedicle screws in deformity correction surgeries. *Spine (Phila Pa 1976)* 2007;32:E56-64.
- Kuklo TR, Lenke LG, O'Brien MF, Lehman RA Jr., Polly DW Jr., Schroeder TM. Accuracy and efficacy of thoracic pedicle screws in curves more than 90 degrees. *Spine (Phila Pa 1976)* 2005;30:222-6.
- Kuklo TR, Potter BK, Lenke LG, Polly DW Jr., Sides B, Bridwell KH. Surgical revision rates of hooks versus hybrid versus screws versus combined anteroposterior spinal fusion for adolescent idiopathic scoliosis. *Spine (Phila Pa 1976)* 2007;32:2258-64.