

A Comparison of Betamethasone Valerate 0.1% Cream Twice Daily Plus Oral Simvastatin Versus Betamethasone Valerate 0.1% Cream Alone in the Treatment of Vitiligo Patients

Abstract

Background: Vitiligo, a common disorder of depigmentation, is often difficult to treat. Corticosteroids are known to be effective, but with modest results. Although simvastatin has been reported to be effective for immunorelated dermatologic disorders including vitiligo, controlled trials are lacking. This study was conducted to compare the efficacy of topical betamethasone valerate 0.1% cream (as a standard method of treatment for vitiligo) versus a combination of betamethasone valerate plus oral simvastatin in the treatment of vitiligo. **Materials and Methods:** Eighty-eight subjects with symmetric vitiligo who had body surface involvement up to 20% were divided randomly into two groups. Group A were treated with betamethasone valerate 0.1% cream twice daily and Group B with betamethasone valerate 0.1% cream twice daily and oral simvastatin 80 mg daily for 12 weeks. Finally, 46 patients completed treatment after 12 weeks in both groups. The results were evaluated by a blind dermatologist using Vitiligo Area Scoring Index (VASI) score at baseline, 4th, 8th, and 12th week of treatment. In a similar way, subjective assessment performed by patients based on photo evaluation at the end of the study. **Results:** Despite a continuous reduction in VASI score in both groups, according to both physician ($P = 0.13$) and patient ($P = 0.374$) assessment oral simvastatin was not statistically more effective than conventional treatment of vitiligo. **Conclusion:** This study indicates that oral simvastatin is not associated with significant impacts in the treatment of vitiligo as compared to other inflammatory dermatologic conditions such as psoriasis. Indeed, other studies should be initiated regarding exact molecular and cellular effects of statins in the treatment of vitiligo.

Keywords: *Betamethasone valerate, simvastatin, therapy, vitiligo*

Introduction

Vitiligo is an acquired pigmentary disorder, with a world wide distribution.^[1] Although it commonly affects 0.5–2% of the population,^[1] based on the epidemiologic reports from Gujarat, India, prevalence up to 8.8% has also been recorded.^[2] The average age of onset is around 20 years, but any age may be affected.^[1] Although men and women are equally involved,^[3,4] the mean peak of involvement in female patients occurs in younger ages.^[4] In its common form, vitiligo presents as uniformly depigmented macules or patches with convex borders surrounded by normal skin.^[1] The cutaneous macules of vitiligo commonly affect normally hyperpigmented areas of the body, including the face, the dorsal surface of the hands, nipples, axillae, umbilicus, sacrum, and genital regions, but can occur anywhere.^[1] Developing

of lesions in areas of friction indicates koebnerization is common.^[5]

Despite the fact that the exact etiology of vitiligo is unknown, the more accepted idea is that vitiligo represents a group of various pathophysiologic etiologies. Among many speculations attempting to demonstrate the pathogenesis of the disease, the autoimmune hypothesis is the most popular.^[6] The other suggested etiologies include neural, biochemical, and genetic hypotheses.^[7] The common pathway of different etiologic factors end in the reduction of melanocyte survival.^[8]

Due to the fact that cosmetic disfigurement and psychological burden of the disease is noticeable, patients frequently seek medical treatment. Although numerous modalities have been introduced, the treatment of

This is an open access article distributed under the terms of the Creative Commons Attribution-NonCommercial-ShareAlike 3.0 License, which allows others to remix, tweak, and build upon the work non-commercially, as long as the author is credited and the new creations are licensed under the identical terms.

For reprints contact: reprints@medknow.com

How to cite this article: Iraj F, Banihashemi SH, Faghihi G, Shahmoradi Z, Tajmirriahi N, Jazi SB. A Comparison of Betamethasone Valerate 0.1% Cream Twice Daily Plus Oral Simvastatin Versus Betamethasone Valerate 0.1% Cream Alone in the Treatment of Vitiligo Patients. *Adv Biomed Res* 2017;6:34.

Received: March, 2013. **Accepted:** August, 2015.

Fariba Iraj, Seyed Hossain Banihashemi¹, Gita Faghihi, Zabihollah Shahmoradi, Nabet Tajmirriahi, Safoura Bokaie Jazi

From the Skin Diseases and Leishmaniasis Research Center, Department of Dermatology, Isfahan University of Medical Sciences, Isfahan, ¹Skin and Stem cell Research Center, Tehran University of Medical Sciences, Tehran, Iran

Address of correspondence:

Dr. Nabet Tajmirriahi, Skin Diseases and Leishmaniasis Research Center, Department of Dermatology, Isfahan University of Medical Sciences, Isfahan, Iran.

E-mail: tajmirriahinabet@yahoo.com

Access this article online

Website: www.advbiores.net

DOI: 10.4103/2277-9175.203159

Quick Response Code:



vitiligo remains frustrating for dermatologists. Among various options, phototherapy, and topical corticosteroid therapy are the cornerstone of treatment. Following treatment with the latter, a reduction in antibody-mediated cytotoxicity against melanocytes has been detected.^[9]

Regarding the proposed leading immunomodulatory role of statins over the past 2 decades,^[10-14] researches on the potential aspects of the use of these drugs for dermatologic disorders including systemic sclerosis, bullous pemphigoid, alopecia areata, vitiligo, lichen planus, psoriasis, and subacute cutaneous lupus erythematosus has been commenced.^[15,16] Recently, a randomized control trial showed a remarkable benefit of adding oral simvastatin in the treatment of psoriasis.^[17]

Despite the suggested therapeutic potential of statins in the treatment of vitiligo, no clinical trial has still been conducted. This study is the first, to our knowledge, to measure quantitatively the added effect of oral simvastatin to the conventional treatment of vitiligo with topical corticosteroids. Both have no significant adverse effects.

Materials and Methods

This randomized, controlled trial was conducted on patients with vitiligo referring to the outpatient Department of Dermatology of Alzahra Hospital in Isfahan (Iran), during April 2012 to February 2013. Patients included to in this study were subjects of 20–60 years old, with a body surface area involvement of <20%. The study was approved by the ethical committee of Isfahan University of Medical Sciences. Research Project Number was 39127.

The diagnosis was established on the basis of clinical findings. Patients were divided into two different treatment groups, using a table of random numbers. Inclusion criteria included any new case of vitiligo, aged between 20 and 60 years, with a body surface area involvement of <20%. Patients with leucoderma secondary to other causes, segmental or zosteriform vitiligo, lesions unresponsive to treatment after 8th week of treatment, pregnancy and lactation, impaired kidney function, significant liver function abnormalities, hepatitis, cirrhosis, and those on mandatory therapy with medications that inhibit CYP3A4 pathways (erythromycin, clarithromycin, metronidazole, azole antifungals, calcium channel blockers, cimetidine, amiodarone, and selective serotonin reuptake inhibitors) were excluded from the study.

Despite the fact that most vitiligo patients are healthy, detailed history was taken from each patient concerning possible associated situations (Graves' disease, Hashimoto's thyroiditis, Addison's disease, pernicious anemia, autoimmune polyendocrinopathy syndrome, halo nevi, alopecia areata, and lichen sclerosus).

With regard to type I error (α) = 0.05, study power = 80%, and expected difference of 30% in response

rate, the sample size was calculated as 44 subjects in each group. The study was approved by the ethical committee of Isfahan University of Medical Sciences. Research Project Number was 39217.

After an initial screening visit, this double-blind clinical trial was initiated with 88 eligible subjects (aged 20–59 years). The patients were divided into two different treatment groups, using a table of random numbers. Finally, 46 patients with surface area involvement of <20% completed treatment modality. Thirty-nine subjects excluded from the study due to the persistence of lesions after the 8th week of treatment or aggravation of lesions and 3 subjects were not willing to complete the study.

In each group, 44 patients for 12 weeks of treatment were enrolled in the study. The patients in Group A received betamethasone valerate cream 0.1% twice daily; and the patients in Group B received betamethasone valerate cream 0.1% twice daily similarly plus simvastatin at the dose of 40 mg two times daily. The duration of treatment was 12 weeks in both groups [Figure 1].

The severity of vitiligo was evaluated by a physician blinded to treatment identifications before the initiation of the treatment and at the end of 4th, 8th, and 12th week of treatment using Vitiligo Area Scoring Index (VASI). According to this method, VASI is calculated as below:

VASI: $\Sigma(\text{Hand units}) \times (\text{Residual depigmentation } [\%])$

A hand unit is considered the volar hand including fingers.^[18] At 100% depigmentation, no pigment is present; at 90%, specks of pigment are present; at 75%, the depigmented area exceeds the pigmented area; at 50%, the depigmented and pigmented areas are equal; at 25%, the pigmented area exceeds the depigmented area; and at 10%, only depigmentation are present.^[19]

The patients were advised to report the occurrence of any unwilling adverse effects (redness, burning, itching, and erosion) during the 12 weeks of the study.

Evaluation of improvement and side effects were conducted at baseline and 4th, 8th, and 12th week of treatment. In each visit, digital photographs were taken by a facial photo fixture using a Canon PowerShot G12 stand-off camera.

In order to evaluate patient satisfaction surveys, assessment of the treatment areas using comparative photographs were conducted by patient based satisfaction, and 12 weeks after starting of treatment (Patient Global Assessment).^[20]

The improvement of vitiligo was scored by a quartile grading scale – mild: <25%, moderate: 25–50%, good: 51–75%, and excellent response: 76–100%.^[19]

Laboratory tests including a check of serum levels of lactate dehydrogenase, creatine phosphokinase and also liver function tests performed in all patients at the beginning and the end of the treatment.

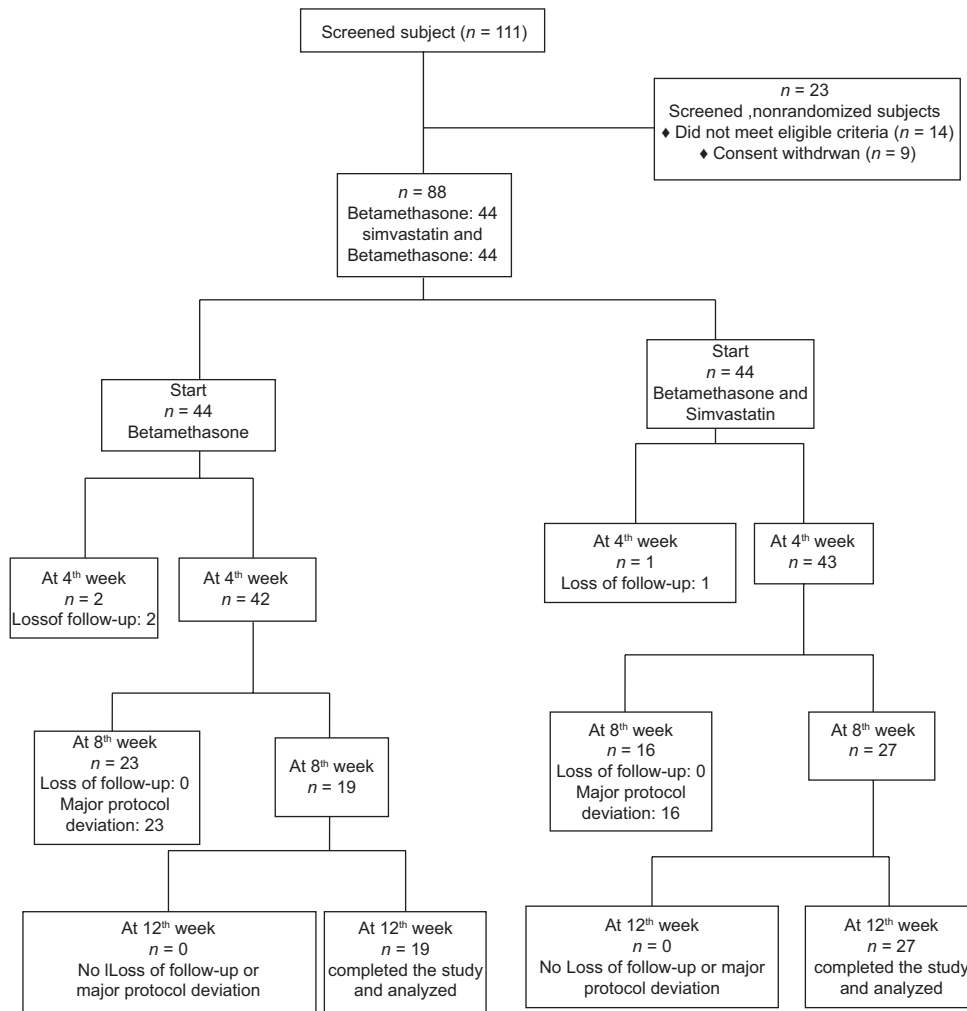


Figure 1: Flow chart of the treatment in the 2 groups

The statistical analysis was carried out by SPSS version 18.0 for Windows software (SPSS Inc., Chicago, IL, USA) by using Chi-square, Mann–Whitney, and repeated measures ANOVA analyses. The significance level was set at $P < 0.05$.

Results

Eighty-eight subjects (100%) with a body surface area involvement of $<20\%$ were recruited in the study. At the end of study 42 subjects failed to complete the study. Thirty-nine subjects (23 subjects in Group A and 16 subjects in Group B) excluded from the study due to persistence of lesions after 8th week of treatment or aggravation of lesions and 3 subjects (2 subjects in Group A and 1 subject in Group B) gave up the study due to scheduling difficulties.

The mean age of patients was 35.7 ± 10.5 years in Group A and 36.5 ± 10.2 years in Group B. The difference in mean ages of the two groups was not statistically significant ($P = 0.75$). Group A included 24 (45%) female and 20 (54.5%) male patients. Group B included 21 (47.7%) female and 23 (52.3%) male patients. There

was no significant difference between sex ratios in the two groups ($P = 0.52$).

By Chi-square test, the distribution of vitiligo patches between two groups ($P = 0.776$) was not statistically significant between them [Table 1].

Patient satisfaction survey at the end of the study revealed that of patients in Group A, 31.6% (6 out of 19) rated themselves as having $<25\%$ of overall improvement, 52.6% (10 out of 19) judged themselves as having 25–50% improvement and 15.8% (3 out of 19) rated improvement of 50–75%. Nobody reported improvement of more than 75% (excellent).

Both total number of patients with improvement and the number of subjects with more than 50% were increased in Group B [Table 2].

Despite the steadily decrease in mean VASI value in both groups by means of repeated measure ANOVA test, Mann–Whitney analysis revealed no significantly greater improvement of depigmented patches according to clinician’s ($P = 0.1$) and patient satisfaction

Table 1: Patient characteristic of betamethasone valerate versus betamethasone valerate plus oral simvastatin group

Distribution of vitiligo patches	Group A* (%)	Group B** (%)
Face	24 (20)	24 (18)
Trunk	48 (39)	46 (35)
Limb	22 (18)	28 (21)
Hands/feet	28 (23)	33 (25)
Genital	0 (0)	1 (1)
Total	122	132

*Group A: Betamethasone valerate cream, **Group B: Betamethasone valerate plus oral simvastatin

Table 2: Vitiligo parameters betamethasone cream and betamethasone cream plus oral simvastatin group

Score	Kind of treatment	Degree of improvement, number (%)			
		Mild	Moderate	Good	Excellent
VASI	Betamethasone cream	7 (36.8)	7 (36.8)	5 (26.3)	0 (0)
	Betamethasone cream plus oral simvastatin	7 (25.9)	10 (37)	6 (22.2)	4 (14.8)
PGA	Betamethasone cream	6 (31.6)	10 (52.6)	3 (15.8)	0 (0)
	Betamethasone cream plus oral simvastatin	7 (25.9)	12 (44.5)	5 (18.5)	3 (11.1)

VASI: Vitiligo Area Scoring Index, PGA: Patient global assessment

assessment ($P = 0.14$) at the end of study in patients of Group B.

In a similar way, the results of dermatologist assessment at the end of 4th ($P = 0.98$) and 8th ($P = 0.89$) week of treatment confirmed the aforementioned final results. By considering the clinical response with repigmentation >50%, greater number of subjects in Group B have been improved at the end of 4th (7% vs. 0%), 8th (22% vs. 15.4%), and 12th (37% vs. 26.3%) week of treatment. However, Mann–Whitney test is used because of nonnormal frequency distributions. It detected no significant difference between groups in all stages of evaluation.

No side effect or any laboratory abnormality has been detected in both groups.

Discussion

Although topical corticosteroids along with phototherapy are the mainstay of treatment of vitiligo, the overall outcome still remains modest.^[21] Indeed, an interest for finding a cheap, safe, and common treatment is unstoppable.

With regard to the more accepted role of autoimmune factors in the pathogenesis of vitiligo, investigators turn their attention to the drugs with immunomodulatory

activities. In fact, nonsegmental vitiligo as the more common form of the disease is primarily affected by the autoimmune factors.^[6] In this model, the main effector cell is CD8⁺ T cell that depends on the action of both interferon-gamma (IFN- γ) and chemokine receptors, especially CCR3.^[1,6]

Other than inhibiting of 3-hydroxy-3-methyl glutaryl CoA, another convincing mechanisms by which statins are therapeutic, are anti-inflammatory properties.^[10] By means of flow cytometry, it was shown that simvastatin are direct inhibitors of IFN- γ . Furthermore, statins downregulate the Th1-type chemokine receptors including CCR5 and CCR3.^[22]

In the present study to our knowledge, we provide the first clinical evidence that measures quantitatively the effectiveness of oral simvastatin in the treatment of vitiligo. Considering the effectiveness of topical corticosteroids according to current data in vitiligo, betamethasone valerate cream as class III corticosteroid, was given to all patients.^[1,9,23,24]

Topical corticosteroids included among the most compelling approaches for small, localized vitiligo.^[9] Despite the primary recommendations on the use of Class III and IV of corticosteroids, recent publications propose that even Class I can be used with good results in an intermittent manner to minimize side effects.^[1] The reported efficacy of corticosteroid varying from one study to another (ranging from 30% to 80%) indicating a different response.^[23,25] In cases that there was not response after 2 months of therapy, to minimize the possible side effects, treatment should be halted.^[1]

In our study, 26.3% (5 out of 19) of our patients in Group A (reflecting only the effect of corticosteroid) revealed >50% regmentation, which is near to the lower limit of response in the statistics of literature. The lower response rate may reflect the small number of subjects in our study. Moreover, by eliminating children from the study, a population group with better responses in comparison with adults, was excluded.^[24]

Despite the greater number of patients with improvement more than 50% greater in subjects of Group B (37% vs. 26.3%), by statistical analysis no significance difference between two groups at the end of study was detected. In other words, oral simvastatin was not accompanied by remarkable effects in the treatment of vitiligo.

Following explanation relevant documents on the immunomodulatory effects of statins in the treatment of dermatologic disease,^[16] Wolkenstein *et al.* has noticed the diminished risk of psoriasis associated with statin intake.^[26] In another study Naseri *et al.*, evaluated the efficacy of oral simvastatin on improvement of psoriasis.^[17] This paper has shown significantly more reduction of Psoriasis Area Severity Index score in the group received oral simvastatin compared to group who did not ($P = 0.001$).

Concerning vitiligo, only in one case study by Noël *et al.*, a clear regression of skin's depigmentation was observed in a 55-year-old man with vitiligo who received simvastatin. After the cessation of simvastatin, his vitiligo lesions relapsed. He was retreated with simvastatin which resulted in reallocation of his disease.^[27]

In comparison to aforementioned studies on the beneficial impact of simvastatin in psoriasis and inflammatory conditions, the number of patients with remarkable response in our study was much less. This difference in response could be because of some limitations. It is now proven that vitiligo represent a group of heterozygous pathophysiologic disorders with the same characteristics. Despite the fact that autoimmune mechanisms are considered the main cause of generalized vitiligo, the role of neurohumoral, cytotoxic, and genetic factors is not insignificant.^[7] In other words, considering autoimmune factors as the only underlying cause of all forms of generalized vitiligo is not logical. Furthermore, pathway alteration of the Th1/Th2 balance and inhibition of lymphocyte migration are the conjectural actions of simvastatin in vitiligo. However, inhibition of Th17 cell induction and interleukin-17 production, inhibition of mast cell degranulation, and induction of angiogenesis which are attributable to statins,^[16] are not considered to be involved in improving vitiligo.

In addition, childhood vitiligo better responds to therapy compared with the adult.^[23] Excluding children from the study thus have affected the results, and underscores the clinical relevance of the pigmentary induction capacities of the treatment protocol. In determining the limitations of study, if we excluded subjects with rapidly spreading vitiligo, and those with lesions on areas known to be recalcitrant to therapy, fewer subjects would drop out of the study. Moreover, most of the studies regarding evaluation the effectiveness of a given therapy defined for 8 weeks. Considering that lesions unresponsive to corticosteroids after 8th week of treatment should be excluded, if we defined the study for 8 weeks, more subjects would remain at the end of the study.

Conclusion

In summary, despite the continuous improvement of disease by therapy, adding of simvastatin was not statistically associated with significant effects. With regard to the discovery of immunomodulatory effects of simvastatin through studies of organ transplant patients, caution should be performed when considering definite immunorelated disorders such as vitiligo. Moreover, parallel experiments should be initiated regarding exact molecular and cellular effects of statins in the treatment of vitiligo.

Acknowledgment

We thank all the patients who participated in the study and the staff Dermatology Department of the Alzahra Hospital.

Financial support and sponsorship

Nil.

Conflicts of interest

There are no conflicts of interest.

References

1. Ortonne JP, Passeron T. Vitiligo and other disorders of hypopigmentation. In: Bologna J, Jorizzo J, Schaffer J, editors. *Dermatolog*. 3rd ed. Elsevier Saunders; 2012. p. 1023-48.
2. Dwivedi M, Laddha NC, Shajil EM, Shah BJ, Begum R. The ACE gene I/D polymorphism is not associated with generalized vitiligo susceptibility in Gujarat population. *Pigment Cell Melanoma Res* 2008;21:407-8.
3. Das SK, Majumder PP, Chakraborty R, Majumdar TK, Haldar B. Studies on vitiligo. I. Epidemiological profile in Calcutta, India. *Genet Epidemiol* 1985;2:71-8.
4. Dogra S, Parsad D, Handa S, Kanwar AJ. Late onset vitiligo: A study of 182 patients. *Int J Dermatol* 2005;44:193-6.
5. Halder RM, Taliaferro SJ. Vitiligo. In: Wolff K, Goldsmith L, Katz S, Gilchrist B, Paller A, Lefell D, editors. *Fitzpatrick's Dermatology in General Medicine*. New York: McGraw-Hill; 2008. p. 72.
6. Palermo B, Campanelli R, Garbelli S, Mantovani S, Lantelme E, Brazzelli V, *et al.* Specific cytotoxic T lymphocyte responses against Melan-A/MART1, tyrosinase and gp100 in vitiligo by the use of major histocompatibility complex/peptide tetramers: The role of cellular immunity in the etiopathogenesis of vitiligo. *J Invest Dermatol* 2001;117:326-32.
7. Njoo MD, Westerhof W. Vitiligo. Pathogenesis and treatment. *Am J Clin Dermatol* 2001;2:167-81.
8. Lee AY, Kim NH, Choi WI, Youm YH. Less keratinocyte-derived factors related to more keratinocyte apoptosis in depigmented than normally pigmented suction-blistered epidermis may cause passive melanocyte death in vitiligo. *J Invest Dermatol* 2005;124:976-83.
9. Falabella R, Barona MI. Update on skin repigmentation therapies in vitiligo. *Pigment Cell Melanoma Res* 2009;22:42-65.
10. Zamvil SS, Steinman L. Cholesterol-lowering statins possess anti-inflammatory activity that might be useful for treatment of MS. *Neurology* 2002;59:970-1.
11. Kobashigawa JA, Katznelson S, Laks H, Johnson JA, Yeatman L, Wang XM, *et al.* Effect of pravastatin on outcomes after cardiac transplantation. *N Engl J Med* 1995;333:621-7.
12. Dobreanu M, Dobreanu D, Fodor A, Bacarea A. Integrin expression on monocytes and lymphocytes in unstable angina short term effects of atorvastatin. *Rom J Intern Med* 2007;45:193-9.
13. Yamashita M, Otsuka F, Mukai T, Otani H, Inagaki K, Miyoshi T, *et al.* Simvastatin antagonizes tumor necrosis factor-alpha inhibition of bone morphogenetic proteins-2-induced osteoblast differentiation by regulating Smad signaling and Ras/Rho-mitogen-activated protein kinase pathway. *J Endocrinol* 2008;196:601-13.
14. Asarch A, Barak O, Loo DS, Gottlieb AB. Th17 cells: A new therapeutic target in inflammatory dermatoses. *J Dermatolog Treat* 2008;19:318-26.
15. Amadi-Obi A, Yu CR, Liu X, Mahdi RM, Clarke GL, Nussenblatt RB, *et al.* TH17 cells contribute to uveitis and scleritis and are expanded by IL-2 and inhibited by IL-27/STAT1. *Nat Med* 2007;13:711-8.

16. Namazi MR. Statins: Novel additions to the dermatologic arsenal? *Exp Dermatol* 2004;13:337-9.
17. Naseri M, Hadipour A, Sepaskhah M, Namazi MR. The remarkable beneficial effect of adding oral simvastatin to topical betamethasone for treatment of psoriasis: A double-blind, randomized, placebo-controlled study. *Niger J Med* 2010;19:58-61.
18. Hamzavi I, Jain H, McLean D, Shapiro J, Zeng H, Lui H. Parametric modeling of narrowband UV-B phototherapy for vitiligo using a novel quantitative tool: The Vitiligo Area Scoring Index. *Arch Dermatol* 2004;140:677-83.
19. Mythili G, Sarma KL. Design and development of an area estimating system to find the body surface area affected by vitiligo using simulation approach. *Int J Adv Res Comput Sci Softw Eng* 2012;2:75-81.
20. Fai D, Cassano N, Vena GA. Narrow-band UVB phototherapy combined with tacrolimus ointment in vitiligo: A review of 110 patients. *J Eur Acad Dermatol Venereol* 2007;21:916-20.
21. Hann SK, Park YK. New concepts in vitiligo. *Clin Dermatol* 1997;15:835-41.
22. Kwak B, Mulhaupt F, Veillard N, Pelli G, Mach F. The HMG-CoA reductase inhibitor simvastatin inhibits IFN-gamma induced MHC class II expression in human vascular endothelial cells. *Swiss Med Wkly* 2001;131:41-6.
23. Kumaran MS, Kaur I, Kumar B. Effect of topical calcipotriol, betamethasone dipropionate and their combination in the treatment of localized vitiligo. *J Eur Acad Dermatol Venereol* 2006;20:269-73.
24. Kumari J. Vitiligo treated with topical clobetasol propionate. *Arch Dermatol* 1984;120:631-5.
25. Shahmoradi S, Mokhtari F, Faghihi G, Adibi N. Comparing the efficacy of topical clobetasol 0.05% plus 5-fluorouracil 5% cream vs. topical clobetasol 0.05% alone in treatment of vitiligo. *J Res Med Sci* 2012;17:17-23.
26. Wolkenstein P, Revuz J, Roujeau JC, Bonnelye G, Grob JJ, Bastuji-Garin S, *et al.* Psoriasis in France and associated risk factors: Results of a case-control study based on a large community survey. *Dermatology* 2009;218:103-9.
27. Noël M, Gagné C, Bergeron J, Jobin J, Poirier P. Positive pleiotropic effects of HMG-CoA reductase inhibitor on vitiligo. *Lipids Health Dis* 2004;3:7.