

## Is it Necessary to Perform Nephrostography before Tube Removal after Percutaneous Nephrolithotomy

### Abstract

**Background:** The aim of this study is the comparison of the complications rate among the patients which underwent nephrostomy removal with and without performing nephrostography. **Materials and Methods:** Between October 2010 and November 2011, 200 patients who underwent standard percutaneous nephrolithotomy (PCNL) procedures were included in this study. The patients were randomly assigned into two groups, Group A ( $n = 100$ ) did not undergo the antegrade nephrostography on postoperative day 2 and the patients were discharged keeping the nephrostomy until postoperative day 3, while in Group B ( $n = 100$ ) the nephrostomy tube was removed on postoperative day 3 after antegrade nephrostography demonstrating ureteral drainage down to the bladder. Postoperative complications in both groups were recorded and compared between two groups. **Results:** A total of 200 patients were treated with standard PCNL. The persistent leakage of urine after removal of the nephrostomy tube was encountered in 5 (5.0%) and 3 (3%) of patients in Groups 1 and 2, respectively. Urinary leakage was resolved with conservative management in 3 and 2 patients of Groups 1 and 2, respectively, but a double-J stent was inserted in 2 and 1 patients in each group because of persistent leakage of urine more than 1-week. The two groups show comparable complications such as prolonged urinary leakage which managed in a similar manner, however, postoperative hospital stay was lesser in Group 1. **Conclusion:** Our results revealed postoperative performing nephrostography before tube removal changed the planning of complications such as prolonged urinary leakage and could be omitted in cases.

**Keywords:** Nephrostography, nephrostomy removal, percutaneous nephrolithotomy

### Introduction

Percutaneous nephrolithotomy (PCNL) has been established as a first-line treatment for larger than 2 cm renal stones,<sup>[1]</sup> and stones resistant to management with shock wave lithotripsy (SWL),<sup>[2]</sup> with >90% success rate.<sup>[1]</sup>

By the time, technical advancement and amplified operative skill have resulted in considerable improvement of this approach,<sup>[3]</sup> however, PCNL does place the patient at risk for complications after or during the procedure with rate of up to 83%, including urinary extravasation (7.2%), bleeding needing transfusion (10.9–17.5%), postoperative fever (4–32.1%), septicemia (0.3–4.7%), and colonic (0.1–0.8%), or pleural injury (0.3–3.1%).<sup>[4-7]</sup> Urinary leakage after removal of the nephrostomy tube is a common complication which could be secondary to ureteral stone fragments, blood clots, or ureteral edema at the ureteropelvic

junction or ureterovesical junction after PCNL.<sup>[8]</sup>

A nephrostomy tube is usually kept for 2 days following the PCNL to supply external drainage of urine, homeostasis, healing of the mucosal edema, and preserves antegrade access if the presence of residual stones necessitates a second nephroscopic procedure<sup>[9,10]</sup> and would be removed following an antegrade nephrostography suggesting ureteral drainage down to the bladder.<sup>[11]</sup>

In our study, an attempt was made to evaluate whether performing nephrostography on the 2<sup>nd</sup> day of operation have an influence on final interventions which are necessitate for management of complications.

### Materials and Methods

This clinical trial was done between October 2010 and November 2011,

Mehrdad Mohammadi Sichani, Masih Babaeian<sup>1</sup>, Saeid Haghdani<sup>2</sup>, Farshid Alizadeh, Hamid Mazdak, Mazaher Hadi<sup>1</sup>, Mohammadhatef Khorrami

From the Department of Urology, Isfahan Kidney Transplantation Research Center, <sup>1</sup>Department of Urology, Isfahan University of Medical Sciences, Isfahan, <sup>2</sup>Department of Urology, Iran University of Medical Sciences, Tehran, Iran

**Address for correspondence:** Dr. Mohammadhatef Khorrami, Department of Urology, Isfahan Kidney Transplantation Research Center, Isfahan University of Medical Sciences, Isfahan, Iran. E-mail: [kharami@med.mui.ac.ir](mailto:kharami@med.mui.ac.ir)

#### Access this article online

Website: [www.advbiores.net](http://www.advbiores.net)

DOI: 10.4103/2277-9175.203160

#### Quick Response Code:

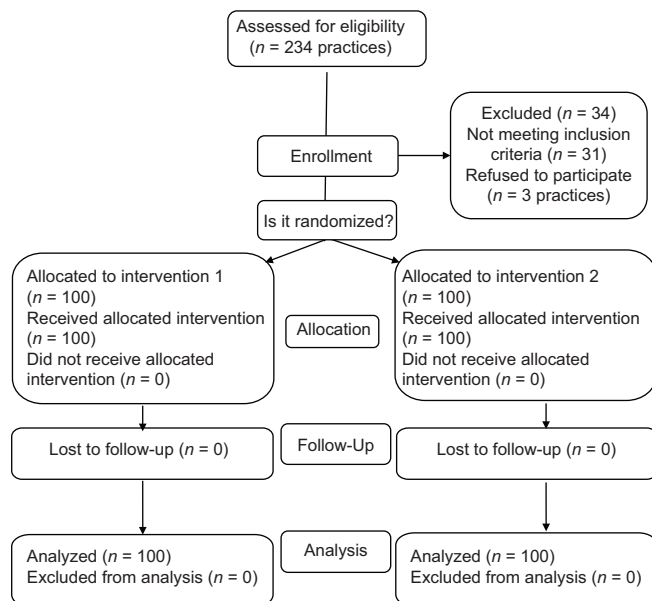


**How to cite this article:** Sichani MM, Babaeian M, Haghdani S, Alizadeh F, Mazdak H, Hadi M, *et al.* Is it Necessary to Perform Nephrostography before Tube Removal after Percutaneous Nephrolithotomy. *Adv Biomed Res* 2017;6:35.

**Received:** April, 2013. **Accepted:** August, 2015.

This is an open access article distributed under the terms of the Creative Commons Attribution-NonCommercial-ShareAlike 3.0 License, which allows others to remix, tweak, and build upon the work non-commercially, as long as the author is credited and the new creations are licensed under the identical terms.

For reprints contact: [reprints@medknow.com](mailto:reprints@medknow.com)



**The consort flowchart**

200 patients who had renal stone larger than 2 cm<sup>2</sup> in the renal pelvis and at most two calices were included in the study. The patients were randomly assigned into two groups. Standard PCNL procedures were performed for all of them. Group A ( $n = 100$ ) did not undergo the antegrade nephrostography on postoperative day 2 and the patients were discharged keeping the nephrostomy until postoperative day 3, while in Group B ( $n = 100$ ) the nephrostomy tube was removed on postoperative day 3 after antegrade nephrostography demonstrating ureteral drainage down to the bladder and no evidence of fever or flank pain was noted. If the nephrostography shows not enough drainage to bladder due to filling defects suggesting significant obstruction in ureter the patient is schedule for ureteroscopy and JJ insertion or transureteral lithotripsy if needed. Exclusion criteria's for the survey were patients who needed more than one percutaneous tract; patients with a significant residual stone burden that necessitated staged second-look nephroscopy; patients with urinary extravasation on nephrostography during surgery; patients with abnormal preoperative renal function (serum creatinine more than 1.5 mg/dl), history of bilateral PCNL, patients with radiolucent stones, and lastly patients with congenital structural anomaly such as horseshoe kidney. Patients who need placement of JJ stent during PCNL due to multiple tract formation, significant residual stones requiring extracorporeal SWL postoperatively, and urinary extravasations in fluoroscopy, etc., were excluded from study too. All procedures were performed with the patient under general anesthesia in the prone position. After retrograde ureteral catheterization, initial percutaneous renal access was obtained under fluoroscopic guidance. The tract was dilated under fluoroscopic control using a 26 to 30 Fr Amplatz Sheath (Goharshafa, Lorestan, Iran) was positioned in the renal collecting system and

when it was impossible, dilation was performed by serial metallic dilators. Stone disintegration was performed using pneumatic lithotripsy.

Normal saline was used for continuous irrigation. Stone clearance and the integrity of the collecting system were confirmed intraoperatively by fluoroscopy and antegrade nephrostography. After complete calculus clearance was confirmed, a standard 16 Fr nephrostomy tube was placed in patients. In both groups, the Foley catheter was removed in all patients 24 h after the procedure, once hematuria was not observed. The nephrostomy tube was removed on postoperative day 3 according to study protocol.

Preoperative, intraoperative, and postoperative data, including patient demographics, stone size; the operation duration, number of tracts, intraoperative complications; length of hospitalization, postoperative complications, need for secondary procedures, blood transfusion requirements, stone-free rates, and patients who were in need of double-J placement because of prolonged urine leakage (PUL) from the percutaneous tract for more than 1-week after removal of the nephrostomy tube following PCNL, were all recorded.

The data were entered into SPSS version 16.0 (SPSS, Chicago, IL, USA) statistical software package and using the paired *t*-test, and Chi-square test for comparison of two study groups. The  $P < 0.05$  was considered statistically significant.

## Results

A total of 200 patients, including 121 males and 79 females, were treated with standard PCNL. Group A, was composed of 62 men and 38 women and Group B, 59 men and 41 women, respectively. The mean age of the patients, stone size and duration of surgery were similar between two groups while postoperative hospital stay was lesser in Group 1 [Table 1]. Total complication rates are given in Table 2. Patients who suffered fever following the removal of nephrostomy in both groups were treated with intravenous antibiotic therapy that discontinued 48 h after resolving of fever. Renal colic in both groups was treated with analgesic therapy without more intervention. The persistent leakage of urine after removal of the nephrostomy tube was encountered in 5 (5.0%) and 3 (3.0%) patients in Groups 1 and 2, respectively.

Urinary leakage in 1 patient of each group was resolved with conservative management with the placement of urostomy bag for 72 h. Eventually, A double-J stent was inserted in 2 patients in Group 1, and in 1 patient in Group 2 because of persistent leakage of urine more than 1-week.

## Discussion

Since the first PCNL which was performed by Fernström and Johansson in 1976,<sup>[12]</sup> the various efforts have

**Table 1: Patients demographic data**

Patients parameter	Mean±SD		P
	Study group 1 (n=100)	Study group 2 (n=100)	
Age (years)	42.8±12	49.5±15	<0.05
Sex (male/female)	62/38	59/41	<0.05
Stone size (mm)	3.5±3.1	4.5±2.9	<0.05
Duration of surgery (h)	108.1±40	110±53	<0.05
Postoperative hospital stay (h)	60	67	<0.05

SD: Standard deviation

**Table 2: Surgical complications**

Patients parameter	Study group 1 n (%)	Study group 2 n (%)
Postoperative fever (>38°C)	5	6
Blood transfusion requirement	10 (10)	8 (8)
Urinary leak (more than 24 h)	5 (5)	3 (3)
Ureteral catheter insertion	2	1

involved to improving PCNL in terms of morbidity, mortality, and cost-effectiveness.<sup>[13]</sup> Standard PCNL needs a period of percutaneous drainage postoperatively, for which nephrostomy tubes of various sizes (5–32 F) and types (Foley, malecot, council, cope loop, reentry tube, pigtail catheter, etc.) have been used.<sup>[14]</sup> Still with the experienced urologists, major, and minor complications happen in 1.1–7% and 11–25% of the patients, respectively.<sup>[15,16]</sup> Prolonged urinary leakage from the nephrostomy site after removal of the nephrostomy has been reported about 16% for more than 24 h<sup>[8]</sup> and in 0.13–1.5% of patients lasting more than 7 days<sup>[17-19]</sup> Typically, intraoperative nephrostography is done to exclude distal ureteral stone fragments and contrast extravasation.

Once there is no flank pain, fever, or urine leakage in the region of the tube, nephrostography is repeated on postoperative day 2 prior to its removal. If contrast extravasation or obstruction occurred on the nephrostogram, the tube is kept till a following imaging shows appropriate drainage.<sup>[8]</sup>

Obstruction on the nephrostogram may predict urinary leak, although in Andonian *et al.* study, urinary obstruction in 27% of patients resolved spontaneously, and distal obstruction did not correlate with postoperative ureteral stent placement. The only patient who was underwent ureteral stent did not reveal obstruction or medial extravasation on the nephrostogram. However, they still recommended, doing postoperative nephrostogram guides the management of the nephrostomy tube and rules out residual fragments, urinary extravasation, and distal

obstruction.<sup>[8]</sup> In our study, only 1 patient in Group A and 2 patients in Group B needed to insert double-J following removal of nephrostomy, so in contrast with the previous study, our findings suggested doing nephrostography on postoperative day 2 have not influence on final interventions for management of complications and can be omitted.

Different factors have been found as promoting factors for prolonged urinary leakage following PCNL such as, increased stone size, complex stone, longer operation time by increasing risk of pelviciceal edema, and exposure to irrigation fluids for a longer period.<sup>[19,20]</sup> Moreover, nephrostomy tube caliber is an important concern that has been revealed to be associated with PUL, which can confound with findings in various previous studies. After removal of smaller caliber nephrostomy tube, the chance of PUL is lesser and more importantly this move toward smaller tubes has limited patient morbidity as well as decreased the length of hospital stay.<sup>[21]</sup>

This trend guided the urologists to tubeless PCNL which is now an accepted procedure in selected patients with kidney stones and is associated with the least postoperative pain; urinary leakage and hospital stay.<sup>[13,22,23]</sup> Considering the declared aspects, Srinivasan *et al.* concluded that drainage of the kidney after PCNL should be an intraoperative decision based on preoperative characteristics and operative complexity and, therefore, individualized.<sup>[24]</sup>

## Conclusion

Although our results revealed postoperative nephrostogram on postoperative day 2 have not changed the planning of complications and could be omitted, previous study recommended doing nephrostogram despite similar results with us which imaging did not affect their final interventions for managing complications. These observations necessitate more comprehensive evaluations about this imaging.

## Financial support and sponsorship

Nil.

## Conflicts of interest

There are no conflicts of interest.

## References

- Matlaga BR, Kim SC, Lingeman JE. Improving outcomes of percutaneous nephrolithotomy access. *Eur Urol EAU Update Ser* 2005;3:37-43.
- Grasso M, Loisesides P, Beaghtler M, Bagley D. The case for primary endoscopic management of upper urinary tract calculi: I. A critical review of 121 extracorporeal shock-wave lithotripsy failures. *Urology* 1995;45:363-71.
- Pietrow PK, Auge BK, Zhong P, Preminger GM. Clinical efficacy of a combination pneumatic and ultrasonic lithotrite. *J Urol* 2003;169:1247-9.
- Lingeman JE, Coury TA, Newman DM, Kahnoski RJ, Mertz JH, Mosbaugh PG, *et al.* Comparison of results and morbidity of percutaneous nephrostolithotomy and extracorporeal shock wave

- lithotripsy. *J Urol* 1987;138:485-90.
- Michel MS, Trojan L, Rassweiler JJ. Complications in percutaneous nephrolithotomy. *Eur Urol* 2007;51:899-906.
  - Tefekli A, Ali Karadag M, Tepeler K, Sari E, Berberoglu Y, Baykal M, *et al.* Classification of percutaneous nephrolithotomy complications using the modified Clavien grading system: Looking for a standard. *Eur Urol* 2008;53:184-90.
  - Stoller ML, Wolf JS Jr, St Lezin MA. Estimated blood loss and transfusion rates associated with percutaneous nephrolithotomy. *J Urol* 1994;152(6 Pt 1):1977-81.
  - Andonian S, Okhunov Z, Shapiro EY, Smith AD, Okeke Z. Diagnostic utility and clinical value of postpercutaneous nephrolithotomy nephrostogram. *J Endourol* 2010;24:1427-30.
  - Winfield HN, Weyman P, Clayman RV. Percutaneous nephrostolithotomy: Complications of premature nephrostomy tube removal. *J Urol* 1986;136:77-9.
  - Maheshwari PN, Andankar MG, Bansal M. Nephrostomy tube after percutaneous nephrolithotomy: Large-bore or pigtail catheter? *J Endourol* 2000;14:735-7.
  - Yu DS. Gelatin packing of intracortical tract after percutaneous nephrostomy lithotripsy for decreasing bleeding and urine leakage. *J Chin Med Assoc* 2006;69:162-5.
  - Fernström I, Johansson B. Percutaneous pyelolithotomy. A new extraction technique. *Scand J Urol Nephrol* 1976;10:257-9.
  - Agrawal MS, Agrawal M, Gupta A, Bansal S, Yadav A, Goyal J. A randomized comparison of tubeless and standard percutaneous nephrolithotomy. *J Endourol* 2008;22:439-42.
  - Paul EM, Marcovich R, Lee BR, Smith AD. Choosing the ideal nephrostomy tube. *BJU Int* 2003;92:672-7.
  - Lam HS, Lingeman JE, Mosbaugh PG, Steele RE, Knapp PM, Scott JW, *et al.* Evolution of the technique of combination therapy for staghorn calculi: A decreasing role for extracorporeal shock wave lithotripsy. *J Urol* 1992;148(3 Pt 2):1058-62.
  - Segura JW, Preminger GM, Assimos DG, Dretler SP, Kahn RI, Lingeman JE, *et al.* Nephrolithiasis Clinical Guidelines Panel summary report on the management of staghorn calculi. The American Urological Association Nephrolithiasis Clinical Guidelines Panel. *J Urol* 1994;151:1648-51.
  - Duvdevani M, Razvi H, Sofer M, Beiko DT, Nott L, Chew BH, *et al.* Third prize: Contemporary percutaneous nephrolithotripsy: 1585 procedures in 1338 consecutive patients. *J Endourol* 2007;21:824-9.
  - Lee WJ, Smith AD, Cubelli V, Badlani GH, Lewin B, Vernace F, *et al.* Complications of percutaneous nephrolithotomy. *AJR Am J Roentgenol* 1987;148:177-80.
  - Binbay M, Sari E, Tepeler A, Erbin A, Savas O, Muslumanoglu AY, *et al.* Characteristics of patients requiring Double-J placement because of urine leakage after percutaneous nephrolithotomy. *J Endourol* 2009;23:1945-9.
  - Herroeder S, Durieux ME, Hollmann MW. Inflammatory responses after surgery. *Hosp Med* 2002;63:99-103.
  - Marcovich R, Jacobson AI, Singh J, Shah D, El-Hakim A, Lee BR, *et al.* No panacea for drainage after percutaneous nephrolithotomy. *J Endourol* 2004;18:743-7.
  - Shah HN, Sodha HS, Khandkar AA, Kharodawala S, Hegde SS, Bansal MB. A randomized trial evaluating type of nephrostomy drainage after percutaneous nephrolithotomy: Small bore v tubeless. *J Endourol* 2008;22:1433-9.
  - Feng MI, Tamaddon K, Mikhail A, Kaptein JS, Bellman GC. Prospective randomized study of various techniques of percutaneous nephrolithotomy. *Urology* 2001;58:345-50.
  - Srinivasan AK, Herati A, Okeke Z, Smith AD. Renal drainage after percutaneous nephrolithotomy. *J Endourol* 2009;23:1743-9.