

## A Novel Method for the Management of Anophthalmic Socket

### Abstract

An orbital defect causes severe facial asymmetry and disfigurement that result in an immense emotional trauma to the patient and is also associated with economic, esthetic, and psychological problems. A prosthetic replacement is the treatment of choice in helping individual to return to his normal life by producing an acceptable and lifelike appearance. This case report describes the critical areas of fabrication of ocular prosthesis for a patient with missing right eye due to trauma to eye ball in an accident. Patient had given a history of surgical enucleation of the eye 15 days after ocular trauma. A polymethyl methacrylate ocular prosthesis was planned. The technique described in this case report presents the use of both custom-made and stock eye shell in an attempt to include the benefits of both. A novel attempt was made to simulate eye movements and exact color matching to that of contralateral eye to provide a better and functional ocular prosthesis to the patient.

**Keywords:** Anophthalmic socket, custom-made eye prosthesis, orbital defect, orofacial structures

### Introduction

Eye is an important sense organ and not only responsible for vision but also for facial expression and esthetics of an individual. When the eye was lost, the individual undergoes psychological stress and feel themselves as isolated from the society.<sup>[1]</sup> After enucleation, evisceration, and exenteration of the eye, the main goal of the maxillofacial prosthodontist is to rehabilitate the patient to look normal and lead a stress-free life. The missing orbital tissues can be replaced with an artificial prosthesis so that the facial symmetry and esthetics can be restored. The maxillofacial prosthodontist can take the help of ophthalmologist, and the plastic surgeon to restore the orbital defect and improve the patient's lifestyle.<sup>[2]</sup> Usually, literature presents the management of anophthalmic socket either using stock ocular prosthesis or by fabricating a custom-made ocular prosthesis. Stock ocular prostheses are produced in mass. A major drawback of the stock eye is it is not made for a particular person to fit. Sometimes, the iris portion matches, but exact color match of the sclera was not obtained with the adjacent eye. A custom ocular prosthesis, on the other hand, is made to fit a particular patient and has better retention than stock ocular prostheses. A well-planned and properly

made custom ocular prosthesis has a good orientation within the socket when patient performs various eye movements and exact color match of sclera and blood vessels present can be obtained.<sup>[3]</sup> The technique described in this case report presents the use of both custom-made and stock eye shell in an attempt to include the benefits of both and provide a good, functional and with exact color match of the ocular prosthesis to the contralateral eye of the patient.

### Case Report

A 45-year-old male patient was reported to the Department of Maxillofacial Prosthodontics, with a chief complaint of missing right eye and wants it to be replaced with an artificial prosthesis [Figure 1]. Patient had given a history of trauma to the right eyeball due to an accident 1 year back. Patient had given a history of surgical enucleation of the right eye under general anesthesia 15 days after ocular trauma. When further asked, we come to know that the enucleation was only done and no intraorbital implant was placed and also there was no history of using ocular prosthesis. Examination of the socket revealed an adequately healed defect with the absence of eyeball, the presence of superior sulcus deepening, narrow opening of eye with upper eyelid ptosis, depth

**Srinivasa B. Rao,**  
**Savita Akki<sup>1</sup>,**  
**Deepak Kumar<sup>2</sup>,**  
**Sunil Kumar**  
**Mishra<sup>3</sup>**

*From the Department of Maxillofacial Prosthodontics and Implantology, Gitams Dental College, Visakhapatnam, Andhra Pradesh, <sup>1</sup>Department of Dentistry, Bidar Institute of Medical Sciences, Bidar, Karnataka, <sup>2</sup>Department of Oral and Maxillofacial Surgery, Purvanchal Institute of Dental Sciences, Gorakhpur, Uttar Pradesh, <sup>3</sup>Department of Maxillofacial Prosthodontics and Implantology, Peoples College of Dental Sciences and Research Centre, Bhopal, Madhya Pradesh, India*

**Address for correspondence:**  
Dr. Sunil Kumar Mishra,  
Department of Maxillofacial Prosthodontics and Implantology, Peoples College of Dental Sciences and Research Centre, Bhopal, Madhya Pradesh, India.  
E-mail: [sunilmsr200@yahoo.co.in](mailto:sunilmsr200@yahoo.co.in)

#### Access this article online

**Website:** [www.advbiores.net](http://www.advbiores.net)

**DOI:** 10.4103/abr.abr\_247\_16

#### Quick Response Code:



**How to cite this article:** Rao SB, Akki S, Kumar D, Mishra SK. A Novel Method for the Management of Anophthalmic Socket. *Adv Biomed Res* 2017;6:72.

**Received:** October, 2016. **Accepted:** January, 2017.

This is an open access article distributed under the terms of the Creative Commons Attribution-NonCommercial-ShareAlike 3.0 License, which allows others to remix, tweak, and build upon the work non-commercially, as long as the author is credited and the new creations are licensed under the identical terms.

**For reprints contact:** [reprints@medknow.com](mailto:reprints@medknow.com)

of the lower fornix was reduced, and movements of the musculature were normal. A thorough inspection and palpation of the defect were done to check the resiliency of the superior and inferior palpebrae. On clinical examination, there was the absence of swelling, bleeding, inflammation, and pain in relation to the anophthalmic socket. On thorough examination of the socket, it was found that there was no undercut present.

The treatment plan was involved, fabrication of an ocular prosthesis with the modifications to correct the opening of both eyelids with correction of ptosis, expansion of remaining eye socket and the superior sulcus deformities. It was planned that a custom-made ocular prosthesis would be given to meet the needs of the patient. The treatment planned and technique involved was explained in detail to the patients along with the limitation of the technique and a written consent was obtained from the patient.

The contralateral eye measurements were taken as a guide for the fabrication of identical custom-made eye prosthesis. The measurements from the inner canthus to the outer canthus was 3.2 cm, inner canthus to the center of pupil was 1.9 cm, center of the pupil to the outer canthus was 1.6 cm, bridge of the nose to the inner canthus was 1.4 cm, diameter of the cornea was 1.1 cm, length from the center of pupil to the lower eyelid was 0.9 cm, and center of the pupil to the outer limbus was 0.6 cm.

Primary impression of the defect was made with alginate (Zelgan, Dentsply, Gurgaon, India). Beading and boxing of primary impression was done, and cast poured in type II dental plaster (Kalabhai, Mumbai, India). Wax spacer with a syringe was positioned in the center of the defect on the cast, and a special tray was fabricated using cold cure clear acrylic resin (DPI, Mumbai, India) [Figure 2]. The syringe fitted to the special tray was filled with polyvinylsiloxane monophase impression material (Reposil, Dentsply, Milford, USA), and the tray was placed over the defect, and the syringe was pressed to inject the impression material into the orbital socket [Figure 3]. Instruction was given to the patient to do the movements of the eye to record the functional impression of the orbital socket. The impression was removed and checked for any bubbles or inaccuracy. The beading and boxing of the impression was done in such a way that a split cast mold in two sections was obtained [Figure 4]. Wax pattern was fabricated in the defect area of the sectioned and stabilized cast [Figure 5]. The color matching of the stock eye shell's iris was done with the contralateral side of the iris. Iris part is trimmed from the stock eye shell and was positioned in scleral wax pattern with the help of measurements taken from contralateral eye [Figure 6]. Try-in of the wax pattern was done to evaluate the size, comfort, the simulation of eye movement, and the eyelid support [Figure 7]. Once the patient was satisfied, the iris was removed from the wax pattern. Flasking and dewaxing of the wax pattern were

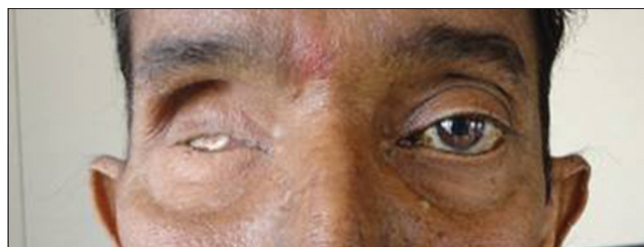


Figure 1: Patient with the right eye defect

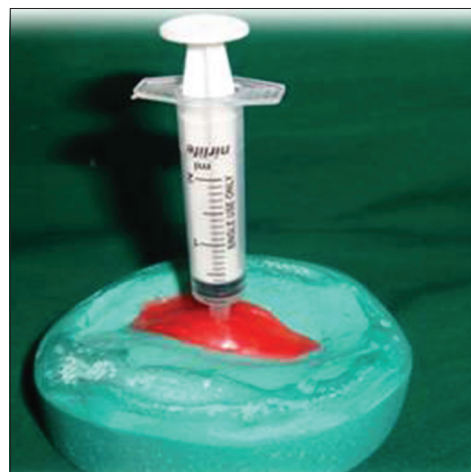

Figure 2: Syringe attached for fabrication of custom tray

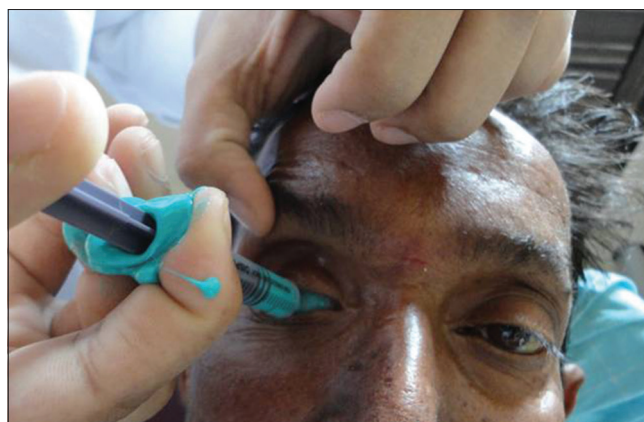

Figure 3: Impression of the orbital socket with custom tray

carried out, and packing was done using tooth-colored heat cure polymethyl methacrylate (PMMA) resin (Pyrex, Roorkee, India). The iris was placed back in the position using adhesive (Fevikwik, Pidilite, Mumbai, India) in the scleral shell, and characterization of the eye was completed using floccules and artist's oil paints (Camlin, Mumbai, India).

The characterized eye was coated with a thin layer of inlay wax (Shiva, Thane, India) and again flasking and dewaxing were done and was packed with heat cure clear acrylic resin so that all the floccules and oil paints are retained on the sclera, and this clear acrylic simulates the conjunctiva and curing was done. The ocular prosthesis obtained was trimmed

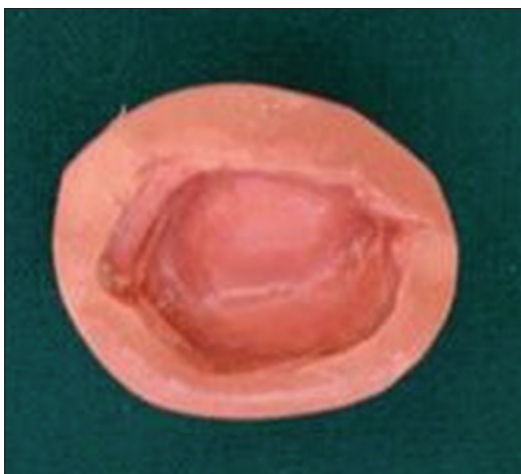

Figure 4: Two piece split cast mold

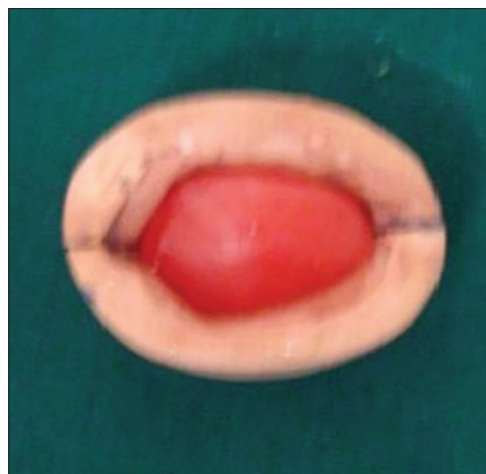

Figure 5: Fabrication of wax pattern in the mold

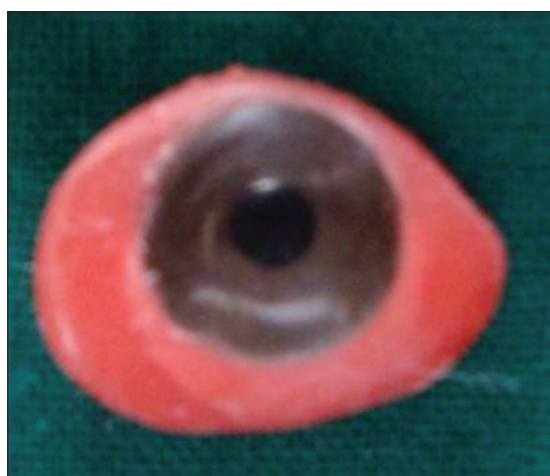

Figure 6: Scleral wax pattern with trimmed and embedded stock iris

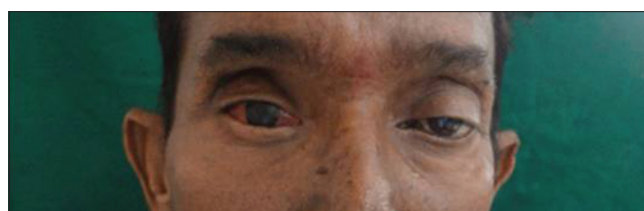

Figure 7: Try-in of the wax prosthesis

and finished [Figure 8]. The insertion of the eye prosthesis was done, and postinsertion instructions were given to the patient [Figure 9]. Prosthesis should be removed from the eye socket during night times and while sleeping. Prosthesis should be cleaned before placing and after removal from the socket. Lubricate the eye with Lubrex eye drops once daily. Clean the prosthesis with mild soap solution once in a week and recall visit for every 6 months.

## Discussion

An orbital prosthesis is a replacement of missing eye in cases of congenital absence of eye, trauma or surgery with an artificial substitute. Studies have reported the successful use of a free skin graft in an anophthalmic socket reconstruction. Sometimes, surgery cannot be done due to different reasons such as lack of patient's interest, limited oculoplastic surgery facility, and technique sensitive surgery. An ocular prosthesis can be introduced in the eye socket in such conditions.<sup>[4]</sup>

Ocular implant can be placed which helped in maintaining the volume of the defect and also improved the mobility

of the prosthesis. The implants are commonly classified as nonintegrated (nonporous) and integrated (porous) implants. PMMA and silicone implants are both smooth and nonintegrated implants, inert in nature, and cause little reaction in the host. PMMA is the material of choice among nonintegrated implants. Previous studies provide no evidence that integrated implants are superior to nonintegrated implants.<sup>[5,6]</sup>

Various methods and different impression techniques were given by many authors for fabrication of eye prosthesis,<sup>[1,3,5,7]</sup> but this case report presents a novel method with taking care of tissue surface of prosthesis for better fit, utilizing a custom-made tray for impression with regular body impression material. Furthermore, the cost-effective stock eye shell was used to take the advantage of iris in that for proper orientation and esthetics to enhance the success and acceptance of prosthesis. In patients where the color of stock iris matches, but the sclera part does not match to the contralateral eye of the patient, this technique described above would be a good alternative for patient.

It is very important to take the general eye care for the patient wearing a prosthetic device. A detailed history of the patient's wearing habits and how often the device is removed and cleaned and also any discharge from the eye, dryness of the eye, any discomfort, pain, ptosis, lid laxity, expulsion, and adhesions should be examined. Patient should see the ophthalmologist or maxillofacial prosthodontist every 6 months for polishing and adjustments of the prosthesis.<sup>[6]</sup>

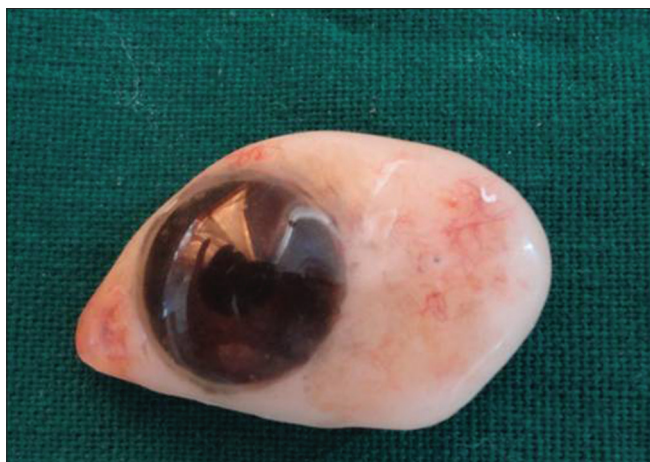

Figure 8: Final ocular prosthesis

### Conclusion

The disfigurement resulting from loss of an eye can cause significant psychological as well as social consequences. This paper describes a simple and economical technique for fabricating an ocular prosthesis. Effort was placed to record the proper anatomy of the enucleated socket and overlying tissues with greater detail with proper tissue contours so that the prosthesis obtained will have closed adaptation to the tissues and simulate natural mobility of the eyeball. The stock sclera used provides good esthetics and color match to that of the contralateral natural eye.

### Declaration of patient consent

The authors certify that they have obtained all appropriate patient consent forms. In the form the patient(s) has/have given his/her/their consent for his/her/their images and other clinical information to be reported in the journal. The patients understand that their names and initials will not

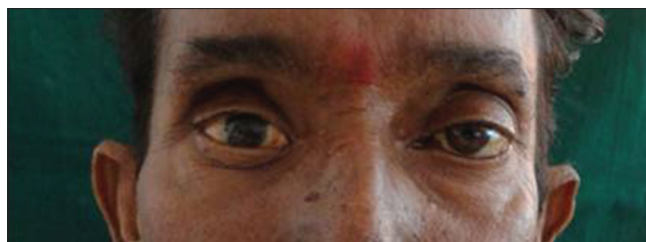

Figure 9: Final prosthesis in the socket

be published and due efforts will be made to conceal their identity, but anonymity cannot be guaranteed.

### Financial support and sponsorship

Nil.

### Conflicts of interest

There are no conflicts of interest.

### References

1. Manoj SS. Modified impression technique for fabrication of a custom made ocular prosthesis. *Anaplastology* 2014;3:129-30.
2. Raizada K, Rani D. Ocular prosthesis. *Cont Lens Anterior Eye* 2007;30:152-62.
3. Mishra SK, Chowdhary R. Reproduction of custom made eye prosthesis maneuver – A case report. *J Dent Oral Hyg* 2009;1:59-63.
4. Jamayet NB, Johari Y, Alam MA, Husein A. Expansion of a contracted eye socket by ocular prosthesis: An alternative prosthetic approach to correct the post enucleation socket syndrome. *OHDM* 2015;14:136-9.
5. Schellini SA, El Dib R, Limongi RM, Mörschbacher R. Anophthalmic socket: Choice of orbital implants for reconstruction. *Arq Bras Oftalmol* 2015;78:260-3.
6. Cafiero-Chin M, Marques C, Danz HJ. Ocular prosthesis: Indications to management. *Can J Opt* 2015;77:24-32.
7. Bindhoo YA, Aruna U. Prosthetic rehabilitation of an orbital defect: A case report. *J Indian Prosthodont Soc* 2011;11:258-64.