

A Case of Adams–Oliver Syndrome

Abstract

Adams–Oliver syndrome (AOS) is a rare congenital disorder with unknown etiology commonly presented with aplasia cutis and terminal limb defects. Central nervous and cardiopulmonary systems may also be affected. It is commonly inherited as an autosomal dominant disorder but autosomal recessive and sporadic cases have also been reported. Here, we present a 10-year-old boy with extensive aplasia cutis congenita and limb anomalies as well as mild pachygyria and focal acrania in neuroimaging. No other internal organ involvement was obvious in this patient. Family history was negative for this syndrome. AOS is a multisystem disorder, and so it is crucial to investigate for internal organ involvements.

Keywords: Absence defect of limbs, Adams–Oliver syndrome, aplasia cutis of the scalp

Introduction

Adams–Oliver syndrome (AOS) is a rare congenital disorder that was initially described in 1945 by Adams and Oliver.^[1] The most characteristic features of this syndrome are congenital scalp defect and terminal limb anomalies.^[2,3] Other presentations include cleft lip or palate, mottled skin, poor height growth, cardiovascular and central nervous system (CNS) malformations, anomalies of urinary system, and mental retardation.^[4-7] Internal organ abnormalities may be lethal and influence the life expectancy of the patient.^[8]

Here, we present a case of AOS with terminal limb defects, aplasia cutis congenita, cranial bone defect, and abnormal findings in neuroimaging.

Case Report

A 10-year-old boy with a large scalp defect was admitted for plastic surgery. The surgery team encountered a malodorous, tender, and secretory wound following the previous unsuccessful tissue expansion reconstruction on the scalp. Because of fever and unfavorable general conditions and with high suspicion of osteomyelitis, the patient was moved to the pediatric ward. Osteomyelitis was ruled out, and the patient had a good response to debridement and wide-spectrum intravenous antibiotic therapy.

This is an open access article distributed under the terms of the Creative Commons Attribution-NonCommercial-ShareAlike 3.0 License, which allows others to remix, tweak, and build upon the work non-commercially, as long as the author is credited and the new creations are licensed under the identical terms.

For reprints contact: reprints@medknow.com

In addition to scalp defect, the patient also had transverse terminal limb anomalies such as brachydactyly, cutaneous syndactyly, and hypoplastic nails [Figure 1a-c]. Speech development was not appropriate for the patient age, and he had difficulty in social interactions. Furthermore, his school performance was not acceptable. The anthropometric parameters of growth were normal. The patient was the first sibling of a consanguineous Iranian family. Gestational age and birth weight were normal. The mother reported that she had frequent use of analgesics such as acetaminophen and ibuprofen for toothache throughout her pregnancy and also had neurotic distress because of familial conflicts. The parents did not indicate any case of scalp and limb defects or mental retardation in their families.

Cranial bone defect under the area of aplasia cutis congenita was obvious in skull X-ray. Furthermore, upper and lower extremities X-rays confirmed bony defects in fingers [Figure 1d-f]. Brain imaging showed focal acrania, an extensive chronic subdural collection under the areas of bone defect and mild pachygyria. Cerebellum was intact [Figure 2]. Chest X-ray and echocardiography were unremarkable (not shown). The parents were not cooperative and did not allow for intelligence quotients (IQ) test, genetic counseling and sampling for DNA analysis, and histopathologic examinations.

How to cite this article: Saeidi M, Ehsanipoor F. A Case of Adams–Oliver Syndrome. *Adv Biomed Res* 2017;6:167.

Received: March, 2016. **Accepted:** July, 2016.

**Minoosaeidi,
Fahime Ehsanipoor¹**

From the Department of Pediatrics, Isfahan University of Medical Sciences, Isfahan, ¹Department of Pediatrics, Iran University of Medical Sciences, Tehran, Iran

Address for correspondence:
Dr. Minoosaeidi, Imam Hossein Children Hospital, Isfahan University of Medical Sciences, Isfahan, Iran.
E-mail: minoosaeidi@gmail.com

Access this article online

Website: www.advbiores.net

DOI: 10.4103/2277-9175.221861

Quick Response Code:



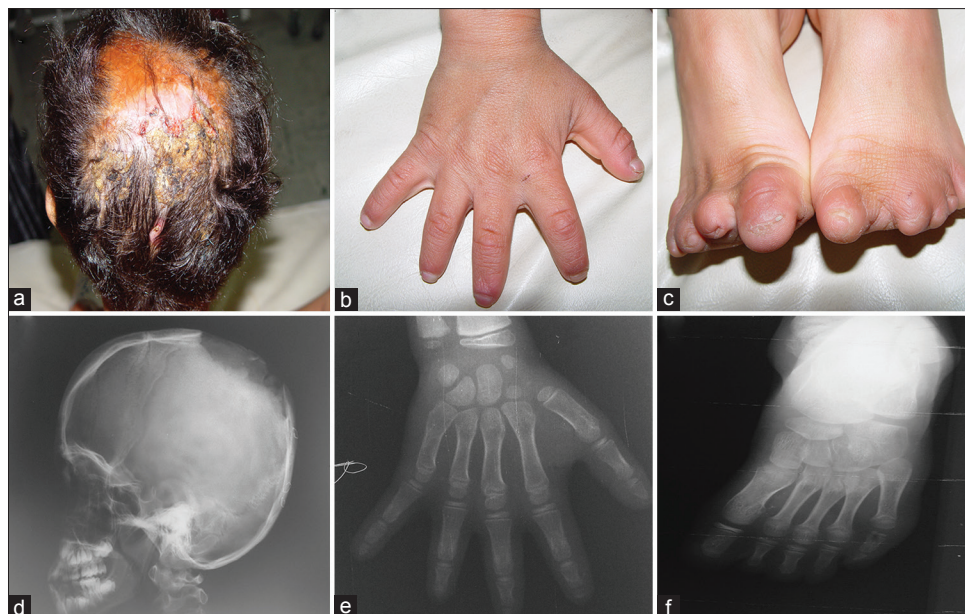


Figure 1: The patient presented with scalp defect (a) as well as upper (b) and lower limb (c) anomalies. Skull X-ray revealed bone defects (d). Upper (e) and lower limb (f) X-ray showed absent or short distal phalanges

The combination of scalp defect, terminal limb anomalies, and neuroimaging findings suggests the diagnosis of AOS.

Discussion

AOS (MIM 100300) is a rare disorder with an estimated incidence of 1 in 225,000 individuals.^[1] Although it is mainly inherited in autosomal dominant manner, autosomal recessive and sporadic cases have also been reported with similar clinical presentations.^[5,9,10] Major criteria for diagnosis are terminal transverse limb defects, aplasia cutis congenita, and family history of AOS. Minor criteria include cutis marmorata, congenital heart defects as well as vascular anomaly. The presence of two major criteria or combination of one major and one minor criterion are sufficient for diagnosis.^[11]

Two affected persons in one Iranian family have been previously reported by Rajabian and Aghaei.^[12] Hence, this is the third case of AOS reported from Iran. Parents of this patient appeared to be normal and did not report any relative with common manifestations of this syndrome. Therefore, it seems that this is a sporadic case of AOS.

The most frequent clinical manifestation of AOS is limb anomaly which is commonly asymmetric and presents in different forms such as syndactyly, brachydactyly, oligodactyly, polydactyly, and hypoplastic nails.^[3] The second most common presentation is scalp defect, generally in vertex area with or without underlying skull defect.^[2] Our case presented with limb anomalies as well as scalp and skull defects.

AOS may be associated with a variety of CNS complications such as microcephaly, encephalocele,

polymicrogyria, ventriculomegaly, hypoplastic corpus callosum, seizure disorders, developmental delay, and mental retardation.^[5,13] Small parenchymal cyst-like lesions and dysplasia of cerebellar cortex have also been reported in this syndrome.^[14] Hypoplastic midline structure of the CNS can lead to partial growth hormone deficiency and short stature.^[7] In addition to chronic subdural collection under the areas of bone defect, we noted mild pachygyria in neuroimaging of our patient. Although we could not perform IQ test for this child, a mild to moderate mental retardation was expected based on the assessment of psychomotor development and school achievements.

Cardiopulmonary complications such as valvular defects, stenotic lesions of left heart, cardiomyopathy, heart block, malformation of pulmonary vessels, and progressive pulmonary hypertension have been reported in AOS patients.^[6,15,16] Therefore, echocardiography for screening or regular workup is pivotal in the management of these patients. We did not detect any cardiopulmonary defect in this case.

The genetic basis and molecular pathogenesis of this disorder are not yet clearly understood. Verdyck *et al.* studied ten affected families in four generations; however, they could not find any causative mutations after genetic study in those family members.^[2] However, abnormal bone morphogenetic protein pathway^[17] and Notch1 mutation^[18] have been reported in these patients. Developmental arrest in the formation of skeletal and soft tissues,^[1] intrauterine pressure and amniotic bands,^[19] abnormal vascular supply in the embryogenesis phase, and numerous microthrombi in the placenta^[20,21] as well as impaired blood supply in the branches of the subclavian and vertebral arteries^[22]

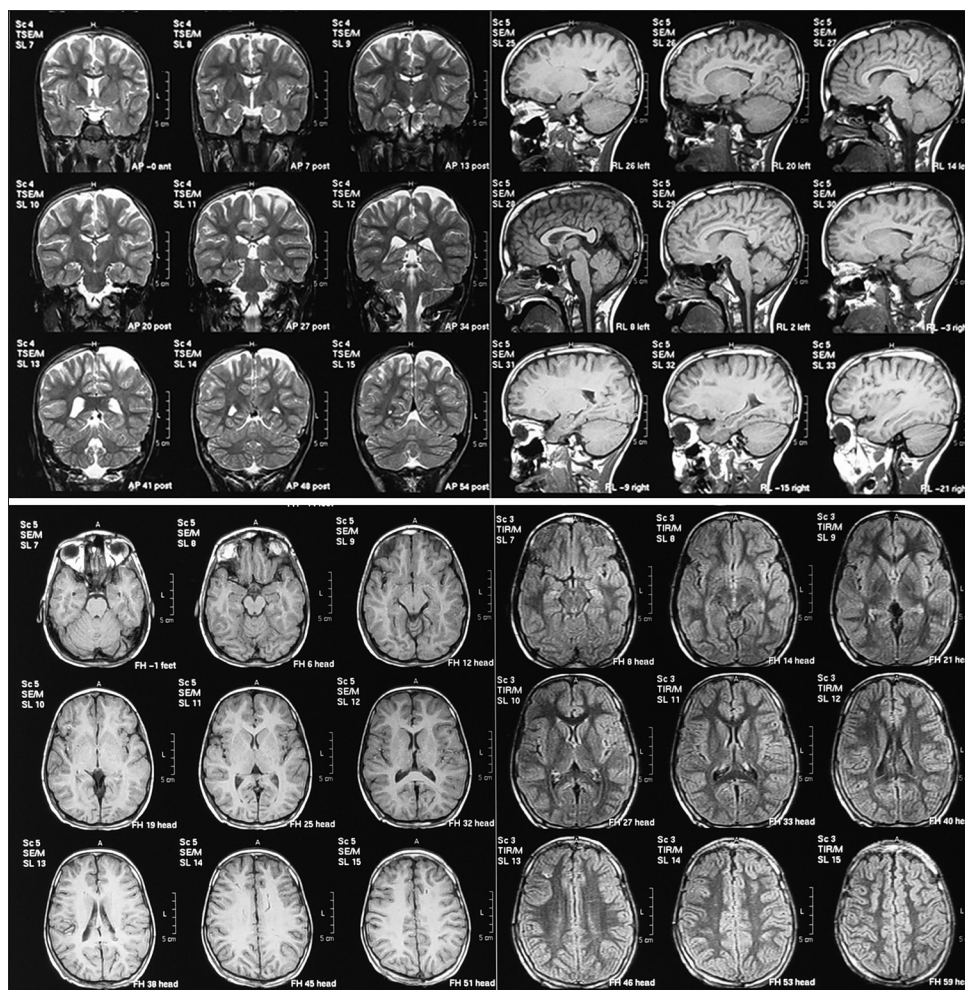


Figure 2: Focal acrania, extensive chronic subdural collection under the areas of bone defect, and mild pachygyria are evident in computed tomography scan

were proposed as potential underlying mechanisms. Swartz *et al.* suggested that the generalized irregularities in the vascular system have an important effect in this disorder.^[16] In addition, Patel *et al.* emphasized on the role of pericytes and their abnormal recruitment as the key mechanism.^[23]

Conclusion

AOS is a rare syndrome with a variety of clinical presentations. Internal organ involvement and intellectual disabilities should be considered in the management of these patients. Understanding the molecular pathogenesis of this disorder can pave the way for more efficient diagnostic and therapeutic modalities.

Declaration of patient consent

The authors certify that they have obtained all appropriate patient consent forms. In the form the patient(s) has/have given his/her/their consent for his/her/their images and other clinical information to be reported in the journal. The patients understand that their names and initials will not be published and due efforts will be made to conceal their identity, but anonymity cannot be guaranteed.

Financial support and sponsorship

Nil.

Conflicts of interest

There are no conflicts of interest.

References

- Adams FH, Oliver CP. Hereditary deformities in man: Due to arrested development. *J Hered* 1945;36:3-7.
- Verdyck P, Holder-Espinasse M, Hul WV, Wuyts W. Clinical and molecular analysis of nine families with Adams-Oliver syndrome. *Eur J Hum Genet* 2003;11:457-63.
- Sankhyan N, Kaushal RK, Jaswal RS. Adams-Oliver syndrome: A case with complete expression. *J Dermatol* 2006;33:435-6.
- Seo JK, Kang JH, Lee HJ, Lee D, Sung HS, Hwang SW, *et al.* A case of Adams-Oliver syndrome. *Ann Dermatol* 2010;22:96-8.
- McGoey RR, Lacassie Y. Adams-Oliver syndrome in siblings with central nervous system findings, epilepsy, and developmental delay: Refining the features of a severe autosomal recessive variant. *Am J Med Genet A* 2008;146A: 488-91.
- Zapata HH, Sletten LJ, Pierpont ME. Congenital cardiac malformations in Adams-Oliver syndrome. *Clin Genet* 1995;47:80-4.

7. Kalina MA, Kalina-Faska B, Paprocka J, Jamroz E, Pyrkosz A, Marszal E, *et al.* Do children with Adams-Oliver syndrome require endocrine follow-up? New information on the phenotype and management. *Clin Genet* 2010;78:227-35.
8. Küster W, Lenz W, Kääriäinen H, Majewski F. Congenital scalp defects with distal limb anomalies (Adams-Oliver syndrome): Report of ten cases and review of the literature. *Am J Med Genet* 1988;31:99-115.
9. Temtamy SA, Aqlan MS, Ashour AM, Zaki MS. Adams-Oliver syndrome: Further evidence of an autosomal recessive variant. *Clin Dysmorphol* 2007;16:141-9.
10. Mempel M, Abeck D, Lange I, Strom K, Caliebe A, Beham A, *et al.* The wide spectrum of clinical expression in Adams-Oliver syndrome: A report of two cases. *Br J Dermatol* 1999;140:1157-60.
11. Bonafede RP, Beighton P. Autosomal dominant inheritance of scalp defects with ectrodactyly. *Am J Med Genet* 1979;3:35-41.
12. Rajabian MH, Aghaei S. Adams-Oliver syndrome and isolated aplasia cutis congenita in two siblings. *Dermatol Online J* 2006;12:17.
13. Amor DJ, Leventer RJ, Hayllar S, Bankier A. Polymicrogyria associated with scalp and limb defects: Variant of Adams-Oliver syndrome. *Am J Med Genet* 2000;93:328-34.
14. D'Amico A, Melis D, D'Arco F, Di Paolo N, Carotenuto B, D'Anna G, *et al.* Adams Oliver syndrome: Description of a new phenotype with cerebellar abnormalities in a family. *Pol J Radiol* 2013;78:83-7.
15. Atasoy HI, Tug E, Yavuz T, Cine N. Unique variant of Adams-Oliver syndrome with dilated cardiomyopathy and heart block. *Pediatr Int* 2013;55:508-12.
16. Swartz EN, Sanatani S, Sandor GG, Schreiber RA. Vascular abnormalities in Adams-Oliver syndrome: Cause or effect? *Am J Med Genet* 1999;82:49-52.
17. Becker R, Kunze J, Horn D, Gasiorek-Wiens A, Entezami M, Rossi R, *et al.* Autosomal recessive type of Adams-Oliver syndrome: Prenatal diagnosis. *Ultrasound Obstet Gynecol* 2002;20:506-10.
18. Stittrich AB, Lehman A, Bodian DL, Ashworth J, Zong Z, Li H, *et al.* Mutations in NOTCH1 cause Adams-Oliver syndrome. *Am J Hum Genet* 2014;95:275-84.
19. Sybert VP. Aplasia cutis congenita: A report of 12 new families and review of the literature. *Pediatr Dermatol* 1985;3:1-14.
20. Fryns JP, Legius E, Demaerel P, van den Berghe H. Congenital scalp defect, distal limb reduction anomalies, right spastic hemiplegia and hypoplasia of the left arteria cerebri media. Further evidence that interruption of early embryonic blood supply may result in Adams-Oliver (plus) syndrome. *Clin Genet* 1996;50:505-9.
21. Hoyme HE, Jones KL, Van Allen MI, Saunders BS, Benirschke K. Vascular pathogenesis of transverse limb reduction defects. *J Pediatr* 1982;101:839-43.
22. Der Kaloustian VM, Hoyme HE, Hogg H, Entin MA, Guttmacher AE. Possible common pathogenetic mechanisms for Poland sequence and Adams-Oliver syndrome. *Am J Med Genet* 1991;38:69-73.
23. Patel MS, Taylor GP, Bharya S, Al-Sanna'a N, Adatia I, Chitayat D, *et al.* Abnormal pericyte recruitment as a cause for pulmonary hypertension in Adams-Oliver syndrome. *Am J Med Genet A* 2004;129A:294-9.