

Osseous Metaplasia in Rectal Polyp: A Case Report with Review of Probable Pathogenesis

Abstract

Heterotopic bone formation is a rare event in gastrointestinal lesions, especially in the pediatric population. Osseous metaplasia is exceedingly rare in colonic polyps. We present a case of rectal juvenile polyp with stromal osseous metaplasia in a 10-year-old male child. This histologic finding is very rare in children with colorectal polyps.

Keywords: Juvenile, osseous metaplasia, pediatric, rectal polyp

**Azar Naimi,
Mehrddad
Hosseinpour¹**

From the Departments of Pathology and ¹Surgery, School of Medicine, Isfahan University of Medical Sciences, Isfahan, Iran

Introduction

Osseous metaplasia is rarely detected in the gastrointestinal tract. It is a phenomenon that has been described in a wide variety of tissue types with respect to mainly neoplastic and rarely nonneoplastic conditions. In colonic polyps, its occurrence is extremely rare.^[1]

Heterotopic bone formation in the digestive tract usually occurs in the colorectal area in association with benign or malignant epithelial tumors.^[2]

Here, we report a rare case of heterotopic bone formation in a juvenile polyp, with discussing potential etiologies.

Case Report

A 10-year-old male child with a history of rectorrhagia since the past 2 weeks visited to the gastrointestinal clinic of our hospital.

The local examination of the rectum revealed no abnormal finding.

A colonoscopic examination revealed a single pedunculated polyp at 5 cm of anal verge measuring 3 cm × 2 cm × 1 cm.

The rest of the colonoscopic examination was unremarkable. Thereafter, according to rather large size of polyp, the patient referred to a surgeon and a polypectomy was performed under general anesthesia and the polypoid mass was sent to the laboratory.

On gross examination, one polypoid tissue fragment of gray-white color with rather

soft consistency was seen. The tissue was embedded totally. On microscopic examination, sections showed a polypoid colonic mucosa which was ulcerated, with granulation tissue, edema, and a mixed inflammatory cell infiltrate, bony trabeculae in lamina propria, which were surrounded by osteoblastic cells, was encountered also [Figure 1a and b].

Discussion

The osseous metaplasia has been reported in a wide variety of tissue types such as prostate, uterus, breasts, skin appendages, pulmonary system, and gastrointestinal organs with respect to both neoplastic and nonneoplastic conditions.^[1,3]

Osseous metaplasia has been described in various types of gastrointestinal polyps as well as in mucin-producing tumors. These include adenomatous, hyperplastic, and hamartomatous polyps.^[4]

Although it mostly occurs in adenomatous polyps, only rare cases of osseous metaplasia have been reported in benign colonic polyps.^[5]

In 1981, Sperling described bone formation within a benign lesion, a rectal polyp. Since then, it has been described a few cases of gastrointestinal polyps with osseous metaplasia. The majority of the occurrences have been rectal or left-sided lesions.^[6] Other case reports comment on lesions located in the ileum,^[7] stomach,^[8] and Barrett's esophagus.^[2] In one case report of

This is an open access journal, and articles are distributed under the terms of the Creative Commons Attribution-NonCommercial-ShareAlike 4.0 License, which allows others to remix, tweak, and build upon the work non-commercially, as long as appropriate credit is given and the new creations are licensed under the identical terms.

For reprints contact: reprints@medknow.com

How to cite this article: Naimi A, Hosseinpour M. Osseous Metaplasia in Rectal Polyp: A Case Report with Review of Probable Pathogenesis. *Adv Biomed Res* 2018;7:78.

Received: July, 2016. **Accepted:** January, 2017.

Address for correspondence:

*Dr. Azar Naimi,
Department of Pathology,
School of Medicine, Isfahan
University of Medical Sciences,
Isfahan, Iran.
E-mail: azar.naimi@med.mui.ac.ir*

Access this article online

Website: www.advbiores.net

DOI: 10.4103/abr.abr_169_16

Quick Response Code:



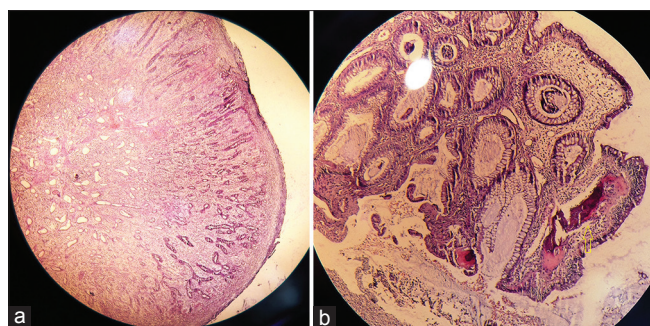


Figure 1: (a) Juvenile polyp histology predominantly composed of granulation tissue (H and E, ×40). (b) Osseous metaplasia (arrow) in polyp stroma

a patient with Peutz–Jeghers syndrome, osseous metaplasia was found in 3 of 15 polyps in the jejunum.^[9]

In a review of case studies among the cases with juvenile polyps, a majority of the patients were males, with a mean age of 7.4 years (range 3–15 years). The polyp size varied from 5 mm to 20 mm, with a mean size of 9 mm.

Histologically, necrosis, inflammation, preexisting calcification, increased vascularity, active chronic inflammation, ulceration, and extracellular mucin deposition were reported to be associated with heterotopic bone formation in tumors.^[2,10]

Various mechanisms have been proposed for the mechanism of bone formation.^[4]

van Patter and Whittick^[11] and Sanerkin^[12] thought that mucinous stromal infiltration was associated with osseous metaplasia and, similar to dystrophic calcification, frequently occurred close to tumor necrosis or squamous metaplasia. Groisman *et al.*^[13] first described bone formation within a benign tubulovillous adenoma without signs of necrosis or mucinous accumulation.^[6]

In 1989, Randall *et al.* suggested alkaline phosphatase expression, a marker of osteoblasts from proliferating mesenchymal cells. Recently, most of the studies have suggested expression of bone morphogenic proteins (BMPs) in the setting of osseous metaplasia.^[5] BMP2 and BMP4 were noted in the stromal fibroblasts. Kypson suggested BMP2 expression in rectal adenocarcinoma with osseous metaplasia.^[14]

In *in vitro* studies, under the influence of four specific transcription factors (Oct3/4, Sox2, c-Myc, and Klf4), they have been found to generate pluripotent stem cells. Subsequently, these stem cells have demonstrated the capability to differentiate into different cell types.^[15,16] Hence, mature fibroblasts which present within the stromal component are under the influence of these similar transcription factors, leading to differentiation of stem cells to osteoblasts.^[5]

Other factors of osteogenesis may include growth factors such as transforming growth factor β 1 and β 2 or other

paracrine factors;^[17] however, this warrants further investigation.

An osseous metaplasia is clinically and prognostically insignificant, and most of the times, it is an incidental finding.^[6]

Conclusion

Although detecting bone tissue in intestinal polyp stroma is a rare event, it cannot exclude the diagnosis of juvenile polyp.

Declaration of patient consent

The authors certify that they have obtained all appropriate patient consent forms. In the form the patient(s) has/have given his/her/their consent for his/her/their images and other clinical information to be reported in the journal. The patients understand that their names and initials will not be published and due efforts will be made to conceal their identity, but anonymity cannot be guaranteed.

Financial support and sponsorship

Nil.

Conflicts of interest

There are no conflicts of interest.

References

- Garg M, Kaur J, Bindroo S, Sharma A, Mahajan NC. Metaplastic ossification in a juvenile rectal polyp: A rare histological finding. *J Clin Diagn Res* 2013;7:908-10.
- Haque S, Eisen RN, West AB. Heterotopic bone formation in the gastrointestinal tract. *Arch Pathol Lab Med* 1996;120:666-70.
- Nakajima H, Iwane S, Mikami T, Nara H, Yamagata K, Morita T, *et al.* Osseous metaplasia in benign rectal polyps. *J Clin Gastroenterol* 1997;25:558-9.
- Bhat V, Roopa A, Shariff S. Juvenile rectal polyp with osseous metaplasia – A rare case with review of literature. *Int J Health Sci Res* 2012;2:114-6.
- Bhattacharya N, Sarkar T. Osseous metaplasia in a juvenile polyp: A rare case report in India. *J Clin Diagn Res* 2013;7:2004-5.
- Hjelkrem M, Fair K, Pabby A. Osseous metaplasia in a colon polyp. *Pract Gastroenterol* 2012;36:58-62.
- Dukes CE. Ossification in rectal cancer: (Section of surgery: Sub-section of proctology). *Proc R Soc Med* 1939;32:1489-94.
- Ohtsuki Y, Danbara Y, Takeda I, Takahashi K, Hayashi K, Sonobe H, *et al.* Metaplastic bone formation in a hyperplastic polyp of the stomach: A case report. *Acta Med Okayama* 1987;41:43-6.
- Oono Y, Fu KL, Nakamura H, Iriguchi Y, Oda J, Mizutani M, *et al.* Bone formation in a rectal inflammatory polyp. *World J Gastrointest Endosc* 2010;2:104-6.
- Narita T, Ohnuma H, Yokoyama S. Peutz-Jeghers syndrome with osseous metaplasia of the intestinal polyps. *Pathol Int* 1995;45:388-92.
- van Patter HT, Whittick JW. Heterotopic ossification in intestinal neoplasms. *Am J Pathol* 1955;31:73.
- Sanerkin NG. Squamous metaplasia and ossification in colonic adenocarcinoma. *J Pathol Bacteriol* 1968;95:547-9.

13. Groisman GM, Benkov KJ, Adsay V, Dische MR. Osseous metaplasia in benign colorectal polyps. *Arch Pathol Lab Med* 1994;118:64-5.
14. Kypson AP, Morphew E, Jones R, Gottfried MR, Seigler HF. Heterotopic ossification in rectal cancer: Rare finding with a novel proposed mechanism. *J Surg Oncol* 2003;82:132-6.
15. Wernig M, Meissner A, Foreman R, Brambrink T, Ku M, Hochedlinger K, *et al.* *In vitro* reprogramming of fibroblasts into a pluripotent ES-cell-like state. *Nature* 2007;448:318-24.
16. Takahashi K, Tanabe K, Ohnuki M, Narita M, Ichisaka T, Tomoda K, *et al.* Induction of pluripotent stem cells from adult human fibroblasts by defined factors. *Cell* 2007;131:861-72.
17. Teot LA, O'Keefe RJ, Rosier RN, O'Connell JX, Fox EJ, Hicks DG. Extrasosseous primary and recurrent giant cell tumors: Transforming growth factor-beta1 and -beta2 expression may explain metaplastic bone formation. *Hum Pathol* 1996;27:625-32.