

Evaluation of Efficacy of Transvaginal Sonography with Hysteroscopy for Assessment of Tubal Patency in Infertile Women Regarding Diagnostic Laparoscopy

Abstract

Background: Infertility, as one of the most common gynecological disorders, affects many people worldwide. To choose the clinical treatment, correct assessment of tubal patency can provide an important clue; therefore, it is considered as one of the major steps in workup examinations of infertile women. In this study, we aimed to compare the results of transvaginal ultrasonography (TVS) after hysteroscopy (HSC) with laparoscopy, as a gold standard, for assessing the fallopian tubal patency in infertile women. **Materials and Methods:** This is a cross-sectional study which included 49 infertile women referred to Shahid Beheshti Hospital affiliated with Isfahan University of Medical Sciences during the years 2015 and 2016. At first, patients who met the inclusion criteria were examined through HSC in by a specialist in gynecology and obstetrics in operating room because laparoscopy was performed after TVS with HSC, but HSC was performed without anesthesia. TVS was performed before and after of HSC to observe fluid in the pouch of Douglas. The findings of TVS with HSC and laparoscopy were compared. **Results:** There was a strong agreement between TVS after HSC and laparoscopy (kappa coefficient = 0.935, 95% confidence interval [CI]: 0.81, 1.00). The sensitivity of TVS after HSC was 100% (95% CI: 66.37, 100) and specificity was 97.50% (95% CI: 86.84, 99.94) with a positive predictive value of 90% (95% CI: 55.50, 99.75) and negative predictive value of 100% (95% CI: 90.97, 100). **Conclusion:** TVS after HSC is an accurate diagnostic tool for examination of fallopian tubal patency in infertile women.

Keywords: Fallopian tubal patency, hysteroscopy, infertility, laparoscopy, transvaginal sonography

Introduction

Worldwide, millions of couples estimated as infertile.^[1,2] Infertility is defined as failure to achieve a successful pregnancy after 12 months of regular unprotected intercourse. Fallopian tube anomalies account for more than 25% of all cases of infertility.^[3-5] The assessment of the uterine cavity and tubal patency is an important step in the investigation of female infertility. Program for investigating infertile patient include a variety of test such as physical examination, laboratory testing, and most of the time, radiologic, and surgical studies. To choose the clinical treatment, correct assessment of tubal patency can provide an important clue; therefore, it is considered as one of the major steps in workup examinations of infertile women.^[4]

The tubal patency evaluation usually consisted of a combination of hysterosalpingography (HSG), hysteroscopy

(HSC), transvaginal ultrasonography (TVS), and laparoscopy.^[6,7]

The gold standard, but invasive and expensive, test for diagnosing tubal patency is laparoscopy.^[6] HSG is widely used as a first-line approach in the routine infertility workup, for assessing the patency of fallopian tubes and investigating uterine anomalies. Contrast reaction and X-ray radiation exposure during HSG may induce abdominal pain and allergic reactions.^[3,8,9] Moreover, to rule out the presence of endometriosis and peritubal adhesions, which could be missed with HSG, laparoscopy is a forced step after diagnosing tubal patency by HSG.^[10] However, although diagnostic laparoscopy offers the possibility of surgical treatment, it expose the patient to operative and anesthesia risk.

Diagnostic HSC is superior to other method for assessing the uterine cavity.

This is an open access journal, and articles are distributed under the terms of the Creative Commons Attribution-NonCommercial-ShareAlike 4.0 License, which allows others to remix, tweak, and build upon the work non-commercially, as long as appropriate credit is given and the new creations are licensed under the identical terms.

For reprints contact: reprints@medknow.com

How to cite this article: Mardanian F, Rouholamin S, Nazemi M. Evaluation of Efficacy of Transvaginal Sonography with Hysteroscopy for Assessment of Tubal Patency in Infertile Women Regarding Diagnostic Laparoscopy. *Adv Biomed Res* 2018;7:101.

Received: June, 2017. **Accepted:** December, 2017.

Farahnaz
Mardanian,
Safoura
Rouholamin,
Maryam Nazemi

From the Department of
Obstetrics and Gynecology,
School of Medicine, Isfahan
University of Medical Sciences,
Isfahan, Iran

Address for correspondence:
Dr. Farahnaz Mardanian,
Department of Obstetrics and
Gynecology, School of Medicine,
Isfahan University of Medical
Sciences, Isfahan, Iran.
E-mail: mardanian@med.mui.ac.ir

Access this article online

Website: www.advbiores.net

DOI: 10.4103/abr.abr_71_17

Quick Response Code:



HSC in combination with sonography is also applicable to examine infertile women for tubal patency. It is the first and best practice to evaluate the uterine cavity, the functional problem of uterine, such as polyps, and myoma development.^[9] Accurate and precise diagnosis of intrauterine conditions is provided by HSC due to its ability to make available panoramic vision of the uterine cavity and direct biopsy of lesions. There is about 30% disagreement between HSG and HSC.^[11] Nevertheless, HSC does not help to examine fallopian tubal patency except when it is followed by ultrasonography.^[9,12-14]

Although a number of studies^[3,9] found that HSC had better diagnostic value in combination with TSV than other modalities, in this study, we aimed to compare the results of TVS after HSC with laparoscopy, as a gold standard, for assessing the fallopian tubal patency in infertile women referred to Shahid Beheshti Hospital affiliated with Isfahan University of Medical Sciences (IUMS).

Materials and Methods

This is a cross-sectional study which included 49 infertile women referred to Shahid Beheshti hospital affiliated with IUMS during the years 2015 and 2016. The Ethics Committee of IUMS approved the study. After an explanation of the aims of the study, informed written consent was taken from the participants. Women with proven infertility (failure to conceive after 12 months unprotected intercourse) that filled informed consent were included in the study. Patients with abnormal uterine bleeding, pelvic infections, urinary tract infection, male factor infertility, and pelvic inflammatory disease were excluded from the study. All procedures were carried out between the 7th and 9th day of follicular phase the menstrual cycle. At first, patients who met the inclusion criteria, baseline TVS examination of the pelvis was performed using GE Voluson E6, Japan. The presence of free fluid in the cul-de-sac in the sagittal plane of the pelvic area was recorded before HSC to calculate prehysteroscopic free fluid. Immediately, after the performance of TVS, the vagina and the cervix were cleaned with an iodine solution. HSC was performed in operating room but without anesthesia. A hysteroscope with 30 optic and 3/5mm external sheath was employed (Karl Storz GmbH and Co., Tuttlingen, Germany). Normal Saline was used as the distension media throughout the procedure, the intrauterine pressure was maintained at 80–100 mmHg. The uterine cavity, endometrial thickness, proximal tube orifices, fundus contour, and cervical canal were assessed. The hysteroscope was then withdrawn, and TVS probe was reinserted into the posterior fornix of the vagina to measure the abdominal fluid of the cul-de-sac in the sagittal plane. TVS was performed with 15 min of finishing HSC to observe fluid in the pouch of Douglas. The presence of the fluid was considered positive for unilateral or bilateral tubal patency. Patients underwent the laparoscopy under general anesthesia during the follicular phase of the menstrual

cycle; after making a pneumoperitoneum, a thorough inspection of the pelvis, internal genitalia, and liver region was performed, followed by testing for fallopian tube patency using methylene blue. Chromopertubation was done by injecting a dilute solution of methylene blue through the cervix. Passage of the dye was observed through the fimbrial ends. The presence of any adhesions, structural anomaly of the uterus, endometriosis, and fallopian tube occlusion was recorded. On completion of the procedure, the incision was repaired; analgesic and antibiotic were given for 24 h. During laparoscopy, if needed, reproductive surgery such as excision and ablation of endometriosis and adhesiolysis was performed. Results of TVS after HSC were compared with those of laparoscopy.

Quantitative and qualitative variables were described by mean \pm standard deviation (SD) and frequency (percent), respectively. The sensitivity, specificity, positive predictive value, and negative predictive value of TVS after HSC were calculated by comparing the results with those obtained by laparoscopy. The kappa coefficient was employed to assess the agreement between TVS after HSC and laparoscopy. The following cutoff points were used for the interpretation of kappa: <0.20 , very poor; $0.21-0.40$, poor; $0.41-0.60$, moderate; $0.61-0.80$, good; and ≥ 0.81 , very good.^[15] Chi-square and Mann-Whitney tests were used to compare qualitative and quantitative variables among the groups, respectively. All of the statistical analysis was performed using MedCalc software version 15 (MedCalc Software, Broekstraat 52, B-9030 Mariakerke, Belgium). $P < 0.05$ was considered significant.

Results

HSC was normal in 29 (59%) of the 49 cases. Endometrial myoma was most common finding (seven cases) among women with abnormal results. The other findings were submucous myoma (four cases) and uterine septum (two cases). Ultrasound examination indicated the presence of fluid in the pouch of Douglas in 39 cases [Figure 1]. In 39 of these cases, tubal patency was confirmed by laparoscopic chromopertubation. In 10 cases with fluid in the pouch of Douglas, unilateral tubal occlusion was confirmed by laparoscopy. Of the 10 negative cases (without fluid in the pouch of Douglas), bilateral tubal occlusion was confirmed in 9 cases by laparoscopic chromopertubation. In one of the negative cases, patent tubes were confirmed by laparoscopic chromopertubation. In a further one negative cases, bilateral hydrosalpinx was confirmed by laparoscopy.

Mean \pm SD age of the participants was 30.91 ± 3.52 ranged from 25 to 38 years. Out of 49 participants included in the study, 34 (69.4%) were cases of primary infertility and 15 (30.6%) were cases of secondary infertility.

Other laparoscopic findings were myoma (7 cases out of 49), endometriosis Grade III (3 cases), and 2 patients with endometriosis Grade I.

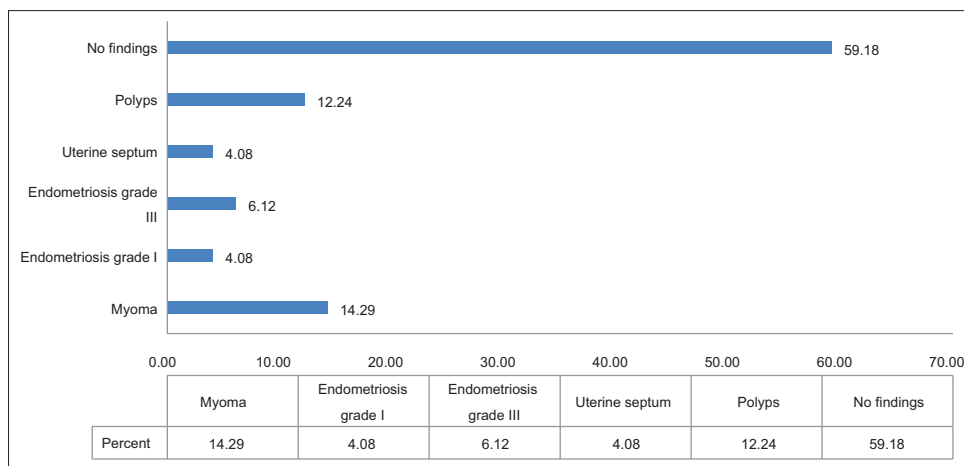


Figure 1: Percentage of the findings detected by transvaginal ultrasonography with hysteroscopy or laparoscopy

Table 1 shows the results of TVS after HSC and laparoscopy. Of 49 patients examined by laparoscopy, 30 (61.2%) were patent, 10 (20.4%) unilateral tubal block, and 9 (18.4%) bilateral tubal block, respectively.

There was a very good agreement between TVS after HSC and laparoscopy (kappa coefficient = 0.935, 95% confidence interval [CI]: 0.81, 1.00). The sensitivity of TVS after HSC was 100% (95% CI: 66.37, 100) and specificity was 97.50% (95% CI: 86.84, 99.94) with a positive predictive value of 90% (95% CI: 55.50, 99.75) and negative predictive value of 100% (95% CI: 90.97, 100).

Graph 1 shows percentage of the findings detected by TVS with HSC or laparoscopy. The three most frequent findings among the patients were myoma (7 cases out of 49), polyp (6 cases out of 49), and endometriosis Grade III (3 cases out of 49). Furthermore, 2 patients with uterine septum and 2 patients with endometriosis Grade I were diagnosed. Twenty-nine out of 49 patients had no findings.

Discussion

Infertility, as one of the most common gynecological disorders, affects many people worldwide.^[1,2] An accurate tubal patency examination is important to diagnose and correct choice for the treatment of infertility.^[6] Till now, expensive and invasive gold standard for tubal patency evaluation is laparoscopy that provides a direct diagnosis.^[7] In this study, we utilized TVS after HSC to examine tubal patency and compared the outcomes to those acquired by laparoscopy. In our study, HSC was performed without anesthesia, and during laparoscopy, therapeutic reproductive surgery, such as coagulation of Grade 1 or 2 endometriosis and adhesiolysis, was performed when required.

In our study, TVS after HSC for testing fallopian tubal patency showed a very good concordance with the findings from laparoscopy rather than other study. We correctly identified 100% and 97.50% of the patent tubes and blocked tubes by TVS, respectively. Therefore, the diagnostic value

| Variables | Laparoscopy | | P |
|----------------------------------|------------------|---------------|-------|
| | No tubal patency | Tubal patency | |
| TVS after HSC, n (%) | | | |
| No fluid in the pouch of Douglas | 9 (90) | 1 (10) | 0.001 |
| Fluid in the pouch of Douglas | 0 (0) | 39 (100) | |
| Infertility type, n (%) | | | |
| Primary | 5 (14.7) | 29 (85.3) | 0.550 |
| Secondary | 4 (26.7) | 11 (73.3) | |
| Infertility duration (year) | 3.89±0.93 | 3.15±0.98 | 0.043 |
| Age (year) | 32.22±3.42 | 30.63±3.51 | 0.223 |

TVS: Transvaginal ultrasonography, HSC: After hysteroscopy

of TVS after HSC was high. These results are in line with other researches.^[3,9,14]

Habibaj *et al.*^[3] concluded that TVS after HSC could provide extra useful information about tubal patency.

Luciano *et al.*^[14] and Allam *et al.*^[9] proposed HSC in combination with TVS as an appropriate alternative to HSG and laparoscopy. In contrast to these researches, Youssef *et al.*^[16] demonstrated TVS after HSC is a good outpatient diagnostic tool for detecting at least one patent tube; although, they reported low negative predictive value but high positive predictive value. Although most of the studies verified the high diagnostic value of TVS after HSC, the low number of cases studied in the sparse researches is the limitation of concluding a general rule about it.

At present, the most accurate diagnostic tool to evaluate tubal patency in infertile women is laparoscopy^[7] that would be an invasive examination in combination with some necessary items, such as an equipped operating room, general anesthesia, laboratory test and trained staff, make laparoscopy an expensive and complex gold standard.^[7,10,17] HSG is less invasive and widely used tool

to detect fallopian tubal patency.^[14,18] It used radiation and is associated with some complications such as allergic reactions.^[7,18] Our results with confirmation of the other researches^[3,9,12] could propose TVS after HSC as an accurate, uncomplicated, quick with low-cost outpatient diagnostic test for detecting fallopian tubal patency. Further studies in large scale are required to assess reliability and precision of TVS after HSC. To complete the finding of the present study, taking three-dimensional sonography for accurate diagnosis is suggested.

Conclusion

In comparison with laparoscopy, as an invasive with the high-cost test, TVS after HSC is an accurate, rapid, easy, and outpatient diagnostic procedure for examination of fallopian tubal patency in infertile women.

Acknowledgment

This study was supported by the IUMS, and thus we are thankful for the women who participated in the study.

Financial support and sponsorship

This study was supported by the IUMS, and thus we are thankful for the women who participated in the study.

Conflicts of interest

There are no conflicts of interest.

References

1. Mascarenhas MN, Flaxman SR, Boerma T, Vanderpoel S, Stevens GA. National, regional, and global trends in infertility prevalence since 1990: A systematic analysis of 277 health surveys. *PLoS Med* 2012;9:e1001356.
2. Inhorn MC, Patrizio P. Infertility around the globe: New thinking on gender, reproductive technologies and global movements in the 21st century. *Hum Reprod Update* 2015;21:411-26.
3. Habibaj J, Kosova H, Bilali S, Bilali V, Qama D. Comparison between transvaginal sonography after diagnostic hysteroscopy and laparoscopic chromopertubation for the assessment of tubal patency in infertile women. *J Clin Ultrasound* 2012;40:68-73.
4. Wang Y, Qian L. Three- or four-dimensional hysterosalpingo contrast sonography for diagnosing tubal patency in infertile females: A systematic review with meta-analysis. *Br J Radiol* 2016;89:20151013.
5. Shalev J, Krissi H, Blankstein J, Meizner I, Ben-Rafael Z, Dicker D, *et al.* Modified hysterosalpingography during infertility work-up: Use of contrast medium and saline to investigate mechanical factors. *Fertil Steril* 2000;74:372-5.
6. Suresh YN, Narvekar NN. The role of tubal patency tests and tubal surgery in the era of assisted reproductive techniques. *Obstet Gynaecol* 2014;16:37-45.
7. Panchal S, Nagori C. Imaging techniques for assessment of tubal status. *J Hum Reprod Sci* 2014;7:2-12.
8. Emanuel MH, van Vliet M, Weber M, Exalto N. First experiences with hysterosalpingo-foam sonography (HyFoSy) for office tubal patency testing. *Hum Reprod* 2012;27:114-7.
9. Allam IS, Rashed AM, Sweedan KH, El Bishry GA, Ahmed WE. Role of hysteroscopy in the evaluation of tubal patency in infertile women. *Middle East Fertil Soc J* 2014;19:215-20.
10. Corson SL, Cheng A, Gutmann JN. Laparoscopy in the "normal" infertile patient: A question revisited. *J Am Assoc Gynecol Laparosc* 2000;7:317-24.
11. Brown SE, Coddington CC, Schnorr J, Toner JP, Gibbons W, Oehninger S, *et al.* Evaluation of outpatient hysteroscopy, saline infusion hysterosonography, and hysterosalpingography in infertile women: A prospective, randomized study. *Fertil Steril* 2000;74:1029-34.
12. Yildizhan B, Durmusoglu F, Uygur M, Erenus M. A new technique for the diagnosis of fallopian tube patency by using hysteroscopy with ultrasound compared with hysterosalpingography in infertile women. *Arch Gynecol Obstet* 2009;280:543-7.
13. Taşkın EA, Berker B, Ozmen B, Sönmezer M, Atabekoğlu C. Comparison of hysterosalpingography and hysteroscopy in the evaluation of the uterine cavity in patients undergoing assisted reproductive techniques. *Fertil Steril* 2011;96:349-5200.
14. Luciano DE, Exacoustos C, Luciano AA. Contrast ultrasonography for tubal patency. *J Minim Invasive Gynecol* 2014;21:994-8.
15. Kottner J, Audige L, Brorson S, Donner A, Gajewski BJ, Hróbjartsson A, *et al.* Guidelines for reporting reliability and agreement studies (GRRAS) were proposed. *Int J Nurs Stud* 2011;48:661-71.
16. Youssef G, El-Sherbini M, El-Komy R, Tarek A. Combined transvaginal sonography and diagnostic hysteroscopy in the assessment of tubal patency in infertile women in correlation to laparoscopic chromopertubation. *J Evid Based Womens Health J Soc* 2015;5:67-71.
17. Török P, Major T. Accuracy of assessment of tubal patency with selective pertubation at office hysteroscopy compared with laparoscopy in infertile women. *J Minim Invasive Gynecol* 2012;19:627-30.
18. Adelusi B, al-Nuaim L, Makanjuola D, Khashoggi T, Chowdhury N, Kangave D, *et al.* Accuracy of hysterosalpingography and laparoscopic hydrotubation in diagnosis of tubal patency. *Fertil Steril* 1995;63:1016-20.