

Stress Urinary Incontinence and Pelvic Organ Prolapse Correction by Single Incision and Using Monoprosthesis: Three-year Follow-up

Abstract

Background: The aim was to study the effectiveness and safety of a modified technique that employs a four-arm polypropylene (PP) mesh (NAZCA-TC) to treat pelvic organ prolapse (POP) and concurrent stress urinary incontinence (SUI) simultaneously. **Materials and Methods:** This prospective follow-up study was conducted on fifty SUI women with concurrent high-grade (greater than Stage 2) anterior vaginal wall and/or uterine prolapse who were referred to Al-Zahra and Noor Hospitals in Isfahan and underwent surgery using the NAZCA-TC, Promedon, Argentina kit. The POP-Quantification system was employed for staging POP before and after surgery. To evaluate lower urinary tract symptoms (LUTS) and patients' quality of life, a stress test and the short form of International Consultation on Incontinence Questionnaire of Female Lower Urinary Tract Symptom were used. Patients were followed up and assessed at 6 weeks, 6 months, and 1, 2, and 3 years after surgery. **Results:** The mean age of patients was 58.2 ± 10.2 years. There was a great reduction (88.6%) in POP staging after surgery. The success rate of SUI treatment was significantly high (83.5%). During 3 years of postoperative follow-up, mesh erosion occurred in 18%, 5 patients (10%) presented with mesh erosion in the first years after operation, 16% reported significant groin or pelvic pain, and 10% required sling release. **Conclusion:** A single vaginal incision and using two less percutaneous access sites with the PP meshes were effective for treating patients with concurrent POP and SUI but have a high rate of postsurgery erosion rate.

Keywords: Erosion, mesh complication, polypropylene, prolapse repair, sling, stress urinary incontinence

Introduction

Anterior vaginal wall prolapse is the most common type of pelvic organ prolapse (POP) in female population, which requires surgical management approximately in 10% of reproductive-aged women.^[1,2] Standard surgical procedures available for treating POP combined with apical and anterior prolapse include hysterectomy with colpopexy or anterior colporrhaphy with high recurrent rate (30%) but are inadequate for the treatment of related symptoms such as stress urinary incontinence (SUI).^[3-6]

After 1996, when Peters and Ulmsten used a new surgical technique to treat incontinence, mid-urethral polypropylene mesh sling (mid-urethral sling [MUS]) was used worldwide to treat SUI.^[7,8] According to "Integral theory" and "Hammock hypothesis," there is an important relationship between incontinence and

prolapse which must be addressed for surgical planning. For patients with concurrent SUI, especially high-grade POP, the surgeon must offer an operation that corrects incontinence and repairs the anatomical defect, which brings about efficient long-term results.^[6,9,10]

In 2008, manufacturers introduced various types of mesh-based POP surgical products in a pack of two-, four-, or six-arm kit to treat POP and SUI separately.^[11,12]

However, using an increasing number of accesses in pelvic floor may lead to more complications and using multiple kits impose more cost on patients. Furthermore, similar to our study, some efforts have been undertaken to use a combination of concurrent anti-incontinence and anti-prolapse techniques to reduce the number of complications and cost of these surgeries.^[3,13-15]

This is an open access journal, and articles are distributed under the terms of the Creative Commons Attribution-NonCommercial-ShareAlike 4.0 License, which allows others to remix, tweak, and build upon the work non-commercially, as long as appropriate credit is given and the new creations are licensed under the identical terms.

For reprints contact: reprints@medknow.com

How to cite this article: Zargham M, Saberi N, Khorrami MH, Mohamadi M, Nourimahdavi K, Izadpanahi MH. Stress Urinary Incontinence and Pelvic Organ Prolapse Correction by Single Incision and Using Monoprosthesis: Three-year Follow-up. *Adv Biomed Res* 2018;7:159.

Received: May, 2018. **Accepted:** November, 2018.

Mahtab Zargham,
Narjes Saberi,
Mohammad Hatf
Khorrami,
Mehrdad Mohamadi,
Kia Nourimahdavi,
Mohammad Hosein
Izadpanahi

From the Isfahan Kidney
Transplantation Research
Center, AL-Zahra Institute
Research Center, Isfahan
University of Medical Sciences,
Isfahan, Iran

Address for correspondence:
Dr. Mahtab Zargham,
Isfahan Kidney Transplantation
Research Center, AL-Zahra
Institute Research Center,
Isfahan University of Medical
Sciences, Hezar Jerib Avenue,
Isfahan, Iran.
E-mail: mah_zargham@yahoo.com

Access this article online

Website: www.advbiores.net

DOI: 10.4103/abr.abr_57_18

Quick Response Code:



This study aimed to evaluate anatomical and functional results and complications of using a NAZCA-TC mesh to treat SUI and POP simultaneously.

Materials and Methods

This was a prospective follow-up study conducted on 98 patients with SUI and anterior vaginal wall prolapse. Patients were recruited from two university hospitals of Al-Zahra and Noor in 2009 and 2011 and followed up by 2016. Women of 18–80 years old who complained of SUI and POP (anterior vaginal wall prolapse with cystocele or without apical or posterior vaginal prolapse) symptoms were included in the study. Among these women, 48 patients were excluded from the study because of refusing vaginal prosthesis (17 patients), 7 patients did not attend follow-up evaluation after the surgery, 14 patients had low-stage POP and did not require surgical intervention, and 10 patients with SUI were treated by pelvic floor exercise and refused surgical intervention.

All the fifty patients who were included in the study had symptomatic SUI and suffered from concurrent anterior vaginal wall prolapse or cystocele (more than Stage 2), which did not respond to conservative management, so they are considered candidates for anti-incontinence and vaginal reconstructive surgery.

The Medical School Review Board of Isfahan University of Medical Sciences approved this prospective follow-up study (Project Number 391493).

Pre- and post-operative evaluations

All the fifty patients included in the study provided detailed urogynecological (symptoms, parity, and surgeries) and medical histories. They also underwent a physical examination including vaginal and stress test. The POP-Quantification (POP-Q) staging system was used for the anatomical evaluation of prolapse.^[16] We employed the validated International Consultation on Incontinence Questionnaire – Short Form of Female Lower Urinary Tract Symptoms for the assessment of LUTS and quality of life and identification of incontinence at the baseline, 6 weeks, 6 months, and 1, 2, and up to 3 years after operation.^[17]

SUI was confirmed according to a positive stress test. Invasive urodynamic investigation was performed in the following conditions: if patient history was not reliable, being in old age, history of anti-incontinence surgery, symptoms suggestive of detrusor overactivity or dysfunctional voiding, abnormal neurological examination, and high postvoid residual volume.^[18] All surgeries were done by the same surgeon who was expert in slingplasty.

Intraoperative data regarding concomitant surgeries and intraoperative complications (e.g., injury to bladder, urethra, or bowel) were included. Blood transfusion, urinary tract infection, fever (temperature >38°C), temporary urinary retention, and thromboembolism were considered as early

complications. Late complications included mesh erosion, dyspareunia, groin pain, vaginal pain, and *de novo* urgency.

Surgical procedure

Prophylactic antibiotic administered (ceftriaxone 1 g) 1 h before surgery lasted until the 2nd postoperative day. Urinary tract or vaginal infection was treated before surgery. All patients underwent cystoscopy before surgical intervention to evaluate any other pathologic findings (e.g., bladder tumors and stone).

- First step: All patients received general or regional anesthesia. After submucosal normal saline injection, longitudinal incision was made into the full thickness of the vaginal epithelium from about 2 cm below the urinary meatus to 3 cm above the cervical or vaginal cuff. The incision first laterally released the vaginal wall to the pubic ramous, and then down to the ischia spines with sharp and blunt dissection. Using fingers, we palpated the tendinous arc of the pelvic fascia, the ischial spine, and the sacrospinous ligament (SSL)
- Second step: Two incisions were placed in the suprapubic area (just adjacent to symphysis pubic) at 2 cm apart from each side of the middle line. Retropubic trocars were then sequentially passed bilaterally through the suprapubic left and right incisions to the mid-urethra craniocaudally with a tension-free vaginal tape (suprapubic arc or SPARK needles). Cystoscopy was performed in all patients to control bladder injury
- Third step: To repair POP, the posterior arms of the mesh were inserted bilaterally through the obturator membrane from postinferior angle of the obturator foramen. Posterior transobturator tape (TOT) curved needles were passed, as much as possible, near to the SSLs approximately 2 cm medial and inferior to the ischia spine [Figures 1 and 2]. Two nonabsorbable nylon 2/0 sutures were used to fix the tail of mesh to the cervical ring
- Fourth step: After irrigation, the vaginal mucosa was closed without trimming. Four hands of mesh proper adjustment which 2 posterior strips elevates the prolapsed apex to be near the SSL and 2 anterior strips adjust MUS gently.

The four ends of mesh's strips were cut at the body plane. Concomitant procedures were carried out if required, including posterior colporrhaphy, levatorplasty, and perineorrhaphy.

At the end of vaginal epithelial-suturing surgery, 1 or 2 gauze pads soaked with triple sulfa vaginal creame were tamponed into the vagina for 12–24 h. A Foley catheter was fixed for 1 day. Patients were often discharged 2 days after surgery and requested to avoid lifting weights or engaging in intense exercises for 4 weeks and to refrain from sexual intercourse for 6 weeks. We suggested hormone replacement therapy (HRT) to menopausal patients (0.625 mg of vaginal estrogen twice weekly). Follow-up visits were scheduled at 6 weeks, 6 months, and 1, 2, and 3 years after surgery. A pelvic examination

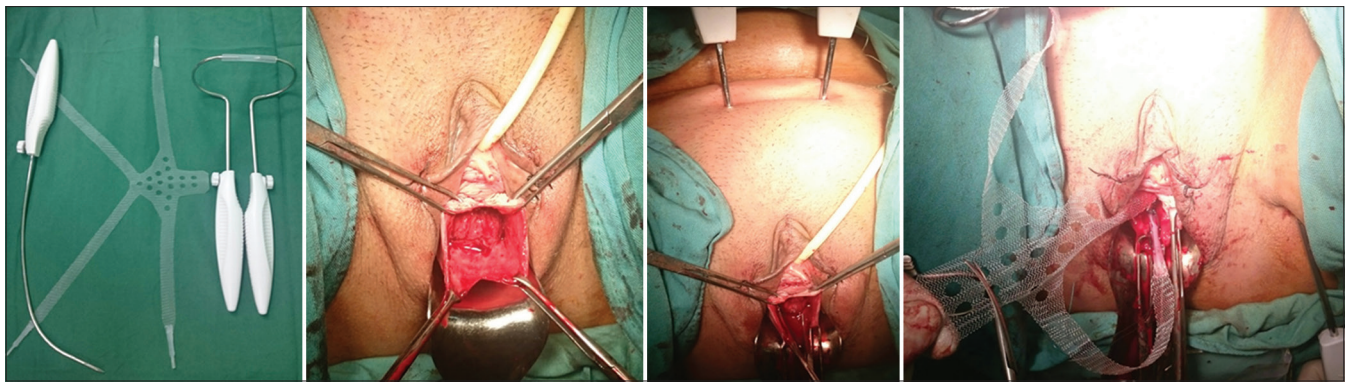


Figure 1: Representation of the mesh kit and surgical technique: up and left: Kit of NAZCA monoprostheses and needles. Two anterior arms utilized for retropubic mid-urethral sling and two posterior arms inserted with transobturator. Up and right: The anterior vaginal wall is incised and the bladder was dissected sharply to the pelvic side walls. Lower and left: both side mid-urethral access by retropubic craniocaudal tunneller insertion (suprapubic arc). Lower and right: Two posterior arms of NAZCA mesh used to insert the prosthesis during the passage of the transobturator tunnellers for posterior transobturator tape

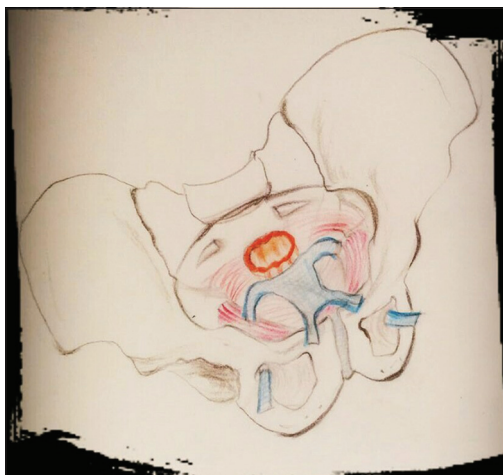


Figure 2: Schematic representation of the surgical technique. Mid-urethral sling from retropubic route and infrasacral colpopexy by posterior transobturator tape insertion and fixation of distal and posterior arms anchored to the obturator nitrous muscle as much as possible near the sacrospinous ligament

was performed to assess the anatomical status and mesh erosion, and stress test was performed for SUI evaluation.

The recurrent prolapse and failure was defined as any anterior or apical descent higher than Stage 1, even if patients were asymptomatic.

Statistical analysis

Quantitative data were expressed as mean \pm standard deviation (SD), and categorical data were expressed as number and percentage. The success rates of POP and SUI were compared using a nonparametric K-related sample test was considered statistically significant. ($P < 0.05$) All statistical analyses were conducted using SPSS software version 20 (Chicago, SPSS Inc).

Results

Fifty patients with a mean age of 58.2 (SD = 10.2) years were included in the study. On an average, patients

were followed up by 26.4 months (SD = 9.6). As shown in Table 1, 18 (36%) patients had previous vaginal surgery, 11 (22%) had prolapse repair, and 7 (14%) had anti-incontinence surgery.

Twenty-three (46%) patients underwent simultaneous posterior compartment repair. A NAZC A-R mesh was used to correct posterior vaginal wall prolapse in 17 (34%) patients. The rest (12%) of the patients were treated by levatorplasty and posterior colporrhaphy.

Table 2 shows pre- and post-operative SUI severity immediately after surgery and 6-week to 3-year follow-up. Among 44 severe SUI patients, 38 (86%) were completely treated ($P < 0.001$) [Table 2].

Table 3 summarizes the prolapse treatment results based on POP-Q. The POP stages had a significant reduction ($P < 0.001$) after treatment. Among all the 43 (86%) high-stage anterior prolapse cases at the baseline, 89.6% of them (39 out of 44 patients) were successfully treated at the end of 3-year follow-up [Table 3]. Our findings revealed that 7% of prolapsed failures were in Grade 4, so perhaps this procedure should be avoided for patients with Stage 4 apical prolapse.

Postoperative complications and further treatment

Among all the fifty patients who were operated, early complications included the following: one of the patients had bladder injury which was revealed by cystoscopy during operation (2%) and treated by bladder catheterization; none of the patients suffered from bowel or visceral injuries; two patients (4%) required blood transfusion; and one (2%) was diagnosed with deep-vein thrombosis.

The most important late complication, vaginal and suburethral mesh erosion, occurred in eight patients (18%). Two patients were treated successfully by HRT and by topical application of estrogen and antibiotics. The rest, six patients, required surgery to remove the mesh.

Table 1: Patient's characteristics

Patient characteristics	Mean±SD
Age (years)	58.2±10.2
Natural Vaginal delivery	4.2±2.7
Cesarean section	0.3±1.4
	n (%)
Previous hysterectomy	12 (24.0%)
Previous prolapse repair (POP)	11 (22.0%)
Previous anti incontinence (SUI)	7 (14.0%)
Follow-up (months; Mean±SD)	26.4±9.6
Sexual activity	28 (56.0%)
Postsurgery HRT	44 (88.0%)
Tobacco use	2 (4.0%)
Diabet mellitus	8 (16.0%)
Hypothyroid	9 (18.0%)
Renal transplantation	1 (2.0%)
Obesity (body mass index>30)	7 (14.0%)

Urinary retention was experienced by six (12%) patients. One patient was managed successfully by clean intermittent catheterization for 6 weeks. In the rest of the five patients, with high postvoid residual volume (>200 ml), bladder outlet obstruction was approved in urodynamic study (according to Blaivas–Groutz nomogram) and they were treated by using sling-release surgery (incised sling strip unilaterally).^[19]

On 3-year follow-up, six (13.5%) patients failed treatment for SUI; two (4.5%) with moderate SUI and four (9%) with severe SUI [Table 2].

Discussion

The present study confirmed that the success rate of the modified NAZCA-TC technique for treating SUI concomitant with POP was highly significant after 3-year follow-up (88.6% and 86.4%, respectively).

Table 2: SUI severity before and after surgery

SUI Severity	Before surgery		6 weeks		6 months		1 year		2 years		3 years		P
	n	Percentage	n	Percentage	n	Percentage	n	Percentage	n	Percentage	n	Percentage	
No	0	0	50	100	47	100	41	87.2	36	80.0	38	86.4	<0.001
Mild	6	12.0	0	0.0	0	0.0	3	6.3	2	4.4	0	0.0	<0.001
Moderate	21	42.0	0	0.0	0	0.0	3	6.3	4	8.9	2	4.5	<0.001
Severe	23	46.0	0	0.0	0	0.0	0	0.0	3	6.7	4	9.0	<0.001
Total	50	100	50	100	47	100	47	100	45	100	44	100	

Table 3: Different types of prolapse by pelvic organ prolapse-quantification stages after surgery with 3-year follow-up

Type of prolapse	POP stage	Preoperation, n (%)	After surgery, n (%)					P
			6 weeks	6 months	1 year	2 years	3 years	
Anterior prolapse	0	0 (0.0)	50 (100)	45 (95.8)	44 (93.7)	39 (92.9)	39 (88.6)	<0.001
	1	2 (4.0)	0 (0.0)	0 (0.0)	0 (0.0)	0 (0.0)	0 (0.0)	
	2	5 (10.0)	0 (0.0)	0 (0.0)	1 (2.1)	1 (2.4)	0 (0.0)	
	3	35 (70.0)	0 (0.0)	2 (4.2)	2 (4.2)	2 (4.7)	4 (9.1)	
	4	8 (16.0)	0 (0.0)	0 (0.0)	0 (0.0)	0 (0.0)	1 (2.3)	
Total		50	50	47	47	42	44	
Posterior prolapse	0	20 (40.0)	50 (100)	47 (100)	45 (95.8)	39 (92.9)	41 (93.2)	<0.001
	1	6 (12.0)	0	0	0	0	0	
	2	12 (24.0)	0	0	0	0	0	
	3	8 (16.0)	0	0	1 (2.1)	2 (4.7)	2 (4.5)	
	4	4 (8.0)	0	0	1 (2.1)	1 (2.4)	1 (2.3)	
Total		50	50	47	47	42	44	
Apical prolapse	0	8 (16.0)	50 (100)	47 (100)	46 (97.9)	39 (92.9)	41 (93.2)	<0.001
	1	1 (2.0)	0	0	0	0	0	
	2	8 (16.0)	0	0	0	0	0	
	3	27 (54.0)	0	0	0	0	0	
	4	6 (12.0)	0	0	1 (2.1)	3 (7.1)	3 (6.8)	
Total		50	50	47	47	42	44	

POP: Pelvic organ prolapse

SUI occurs in a majority of women who undergo surgery because of prolapse. In the standard method and simultaneously applying for treating SUI, an MUS can be used effectively. There are many studies to support the POP repair in prolapse surgery with or without mesh in conjunction with MUS by separate meshes and through separate routes of arm mesh (NAZCA-TC) to repair the cystocele. Furthermore, we suggested using one for SUI and apical prolapse simultaneously. The advantages of integrating two techniques (anti-prolapse and incontinence surgery) into one by using one mesh are lower costs and less pelvic floor trauma because only one mesh and four accesses are required instead of two meshes and six accesses. Palma *et al.*^[14] used the same NAZCA-TC kit to the placement of anterior arm prepubic route and posterior arm transobturator, but republic MUS is not a standard technique for anti-incontinence surgery with unknown long-term results. All of the patients in this study were seeking SUI, and introducing sling mesh through stable anatomic structures was preferred to solve SUI classically. Sharifiaghdas *et al.*^[15] using the same mesh NAZCA-TC to POP treatment in a double TOT approach concluded that 78% of their patients had occult SUI. Their investigation had a doubtful result about patients presenting with significant SUI and seeking SUI treatment, but they concluded that double TOT is an effective method for both complaints (SUI and POP).

Ignjatovic *et al.* reported the use of other mesh (Prolift kit)^[20] and separated the access (two for MUS and four for double TOT as anti-prolapse technique at the same time), and their results was similar.

Recurrence of apical prolapse was more frequent in patients with Stage 4 apical prolapse before surgery. Our study showed that anatomical restoration was not perfect in patients with Stage 4 of apical prolapse, and the majority of prolapse recurrence occurred in the apical compartment and anterior vaginal wall that was fixed by mesh fibrosis. Hence, in patients with Stage 4 apical prolapse, we propose the abdominal sacral colpopexy method, against performing vaginal surgery, because obviously the results will be better.

We performed SSL fixation to correct apical prolapse by deep passaging of helical needles into the SSL and fixing the mesh to the vaginal cuff or cervical ring.

In our study, only obstructive symptoms increased by using this method, likely because of performing concomitant anterior colporrhaphy, which is the most important risk factor associated with voiding dysfunction in simultaneous POP therapy.^[21]

The frequency of vaginal mesh erosion (16%) is higher compared with that of other studies (5.7% and 0%). It may be due to the high rate of previous vaginal surgery in our group compared to others that employed NAZKA

kits. Scarred vaginal tissue and high rate of fibrosis were consistent with higher rate of erosion and weak healing.^[14,15,19] Here, we found that the most common sites of mesh erosion were the cervix and anterior fornix. An atrophic vagina and an insufficient blood supply to the vaginal epithelium may account for the increased frequency of vaginal erosion. Our findings indicated the importance of paying close attention in ensuring appropriate intraoperative coverage of the mesh and preventing vaginal infection and administering postoperative HRT because of the increased probability of recurrent mesh erosion.

Postoperative obstructive symptoms that were experienced by 38% of patients diminished 1 month after surgery. According to the Blaivas and Groutz nomogram, if the obstructed bladder outlet proven in urodynamic, Mesh release was required to treat 10% of patients with severe symptoms.^[22]

Urge symptoms were not significantly alleviated in our patients, likely because of their *de novo* nature. However, persistent urge symptoms lasting 3 years after surgery were rare, which differs from the results of other studies. For example, one study reported 49% amelioration of urgency and urgency urinary incontinence after surgery.^[23] The use of a mesh and presence of inflammation and fibrosis in the trigon area of the bladder may cause afferent nerve stimulation and serve as the source of overactive bladder and urge symptoms.^[24] This event is common in the first 6 months after surgery but gradually will be decreased.

Two patients required blood transfusion. They were younger than other patients, and posterior colporrhaphy was done for them simultaneously. It may be explained by the elevated blood supply to their vaginal epithelium and also extensive anterior and posterior vaginal wall dissection. However, in the majority of patients, approximately 0.5 mg/dl decrease in hemoglobin concentration was detected. We already had experiences of simultaneous anti-incontinence and anti-prolapse surgeries without using mesh^[25] and know that it is the state of the art to select the proper patient for perfect intervention.

The limitations of the present study included no analyses of quality of life-related issues and no quantification of inguinal and pelvic pain and dyspareunia.

Conclusion

A single vaginal incision and using two less percutaneous access sites with the monoprosthesis NAZCA-TC kit were effective for treating patients with concurrent POP and SUI but have high rate of postoperative erosion rate.

Financial support and sponsorship

Isfahan University of Medical Sciences

Conflicts of interest

There are no conflicts of interest.

References

1. Olsen AL, Smith VJ, Bergstrom JO, Colling JC, Clark AL. Epidemiology of surgically managed pelvic organ prolapse and urinary incontinence. *Obstet Gynecol* 1997;89:501-6.
2. Fritel X, Varnoux N, Zins M, Breart G, Ringa V. Symptomatic pelvic organ prolapse at midlife, quality of life, and risk factors. *Obstet Gynecol* 2009;113:609-16.
3. Gordon D, Groutz A, Wolman I, Lessing JB, David MP. Development of postoperative urinary stress incontinence in clinically continent patients undergoing prophylactic Kelly plication during genitourinary prolapse repair. *Neurourol Urodyn* 1999;18:193-7.
4. Groutz A, Gordon D, Wolman I, Jaffa AJ, Kupferminc MJ, David MP, *et al.* The use of prophylactic stamey bladder neck suspension to prevent post-operative stress urinary incontinence in clinically continent women undergoing genitourinary prolapse repair. *Neurourol Urodyn* 2000;19:671-6.
5. Whiteside JL, Weber AM, Meyn LA, Walters MD. Risk factors for prolapse recurrence after vaginal repair. *Am J Obstet Gynecol* 2004;191:1533-8.
6. Huang KH, Kung FT, Liang HM, Chen CW, Chang SY, Hwang LL. Concomitant pelvic organ prolapse surgery with TVT procedure. *Int Urogynecol J Pelvic Floor Dysfunct* 2006;17:60-5.
7. Maher CM, Feiner B, Baessler K, Glazener CM. Surgical management of pelvic organ prolapse in women: The updated summary version Cochrane review. *Int Urogynecol J* 2011;22:1445-57.
8. Walter JE; Urogynaecology Committee. Transvaginal mesh procedures for pelvic organ prolapse. *J Obstet Gynaecol Can* 2011;33:168-74.
9. Maher CF, Qatawneh AM, Dwyer PL, Carey MP, Cornish A, Schluter PJ, *et al.* Abdominal sacral colpopexy or vaginal sacrospinous colpopexy for vaginal vault prolapse: A prospective randomized study. *Am J Obstet Gynecol* 2004;190:20-6.
10. Ulmsten U, Petros P. Intravaginal slingplasty (IVS): An ambulatory surgical procedure for treatment of female urinary incontinence. *Scand J Urol Nephrol* 1995;29:75-82.
11. Margulies RU, Lewicky-Gaupp C, Fenner DE, McGuire EJ, Clemens JQ, Delancey JO, *et al.* Complications requiring reoperation following vaginal mesh kit procedures for prolapse. *Am J Obstet Gynecol* 2008;199:678.e1-4.
12. Ridgeway B, Walters MD, Paraiso MF, Barber MD, McAchrans SE, Goldman HB, *et al.* Early experience with mesh excision for adverse outcomes after transvaginal mesh placement using prolapse kits. *Am J Obstet Gynecol* 2008;199:703.e1-7.
13. Ignjatovic I, Basic D, Stosic D, Potic M, Mitic P, Milic V. Reutilization of the prolift mark system for the simultaneous correction of prolapse and incontinence in patients with pelvic organ prolapse and stress urinary incontinence. *Eur J Obstet Gynecol Reprod Biol* 2008;141:79-82.
14. Palma P, Riccetto C, Prudente A, Dalphorno F, Delroy C, Castro R, *et al.* Monoprosthesis for anterior vaginal prolapse and stress urinary incontinence: Midterm results of an international multicentre prospective study. *Int Urogynecol J* 2011;22:1535-41.
15. Sharifiaghdas F, Daneshpajoo A, Mirzaei M. Simultaneous treatment of anterior vaginal wall prolapse and stress urinary incontinence by using transobturator four arms polypropylene mesh. *Korean J Urol* 2015;56:811-6.
16. Persu C, Chapple CR, Cauni V, Gutue S, Geavlete P. Pelvic organ prolapse quantification system (POP-Q) – A new era in pelvic prolapse staging. *J Med Life* 2011;4:75-81.
17. Hajebrahimi S, Nourizadeh D, Hamedani R, Pezeshki MZ. Validity and reliability of the international consultation on incontinence questionnaire-urinary incontinence short form and its correlation with urodynamic findings. *Urol J* 2012;9:685-90.
18. Ridgeway B, Barber MD. Midurethral slings for stress urinary incontinence: A urogynecology perspective. *Urol Clin North Am* 2012;39:289-97.
19. Ficazzola M, Nitti VW. Complications of incontinence procedures in women. In: Taneja S, Smith RD, Ehrlich R, Taneja S, editors. *Complications of Urologic Surgery*. 3rd ed. Philadelphia: Saunders; 2000.
20. Ignjatovic I, Stojkovic I, Basic D, Medojevic N, Potic M. Optimal primary minimally invasive treatment for patients with stress urinary incontinence and symptomatic pelvic organ prolapse: Tension free slings with colporrhaphy, or prolift with the tension free midurethral sling? *Eur J Obstet Gynecol Reprod Biol* 2010;150:97-101.
21. Chung SM, Moon YJ, Jeon MJ, Kim SK, Bai SW. Risk factors associated with voiding dysfunction after anti-incontinence surgery. *Int Urogynecol J* 2010;21:1505-9.
22. Blaivas JG, Groutz A. Bladder outlet obstruction nomogram for women with lower urinary tract symptomatology. *Neurourol Urodyn* 2000;19:553-64.
23. Fletcher SG, Haverkorn RM, Yan J, Lee JJ, Zimmern PE, Lemack GE. Demographic and urodynamic factors associated with persistent OAB after anterior compartment prolapse repair. *Neurourol Urodyn* 2010;29:1414-8.
24. Moore RD, Mitchell GK, Miklos JR. Single-incision vaginal approach to treat cystocele and vault prolapse with an anterior wall mesh anchored apically to the sacrospinous ligaments. *Int Urogynecol J* 2012;23:85-91.
25. Zargham M, Alizadeh F, Tadayyon F, Khorrami MH, Nouri-Mahdavi K, Gharaati MR, *et al.* Concomitant surgical correction of severe stress urinary incontinence and anterior vaginal wall prolapse by anterior vaginal wall wrap: 18 months outcomes. *Journal of research in medical sciences: The official journal of Isfahan University of Medical Sciences* 2013;18:588.