

The Radioprotective Effect of Combination of Melatonin and Metformin on Rat Duodenum Damage Induced by Ionizing Radiation: A Histological Study

Abstract

Background: Radiation toxicity is one of the major concerns for patients with gastrointestinal cancers that undergo radiotherapy. Duodenum is one of the most radiosensitive parts of gastrointestinal system that may be exposed to a high dose of radiation during radiotherapy for some cancers. The development or identification of appropriate radioprotectors with less toxicity is an interesting aim in radiobiology for clinical radiotherapy applications. In the present study, we aimed to evaluate the radioprotective effect of melatonin and metformin combination in rat's duodenum. In addition, we compared our results with the radioprotective effect of melatonin, when administered alone. **Materials and Methods:** Thirty male rats were divided into six groups: control, melatonin treatment, melatonin plus metformin treatment, whole-body irradiation, irradiation with melatonin treatment, and irradiation with melatonin plus metformin treatment. Irradiation was performed with 10 Gy cobalt-60 gamma rays, while 100 mg/kg of melatonin and metformin were administered 24 h before to 72 h after irradiation. After 3.5 days, their duodenum tissues were removed for histopathological evaluation. **Results:** Irradiation of rats led to mild-to-moderate mucositis signs, infiltration of inflammatory cells, necrosis, and damage to Brunner's glands and reduction of goblet cells. Melatonin was able to alleviate these damages, while melatonin plus metformin could reduce some radiation toxicity signs. **Conclusion:** Administration of melatonin plus metformin could reduce mucositis in duodenum. However, the administration of melatonin is more effective for mitigation of duodenal injury compared with melatonin plus metformin.

Keywords: Duodenum, melatonin, metformin, radiation, radioprotection

Introduction

Radiotherapy plays a key role in the control and treatment of cancers. Some studies have reported that up to 70% of cancer patients may require treatment with radiation.^[1] During radiotherapy, patients receive a high total dose of ionizing radiation (about 50–80 Gy) in several fractions which may take some weeks.^[2] The most important aim in radiotherapy is the control or complete eradication of tumor, without significant damages to surrounding organs. However, this aim is usually not achieved completely, because exposure to high doses of radiation leads to severe reactions in normal tissues. The side effects of radiotherapy are of utmost concern when an organ with high proliferation rate is located within the field of treatment.^[3] The most radiosensitive organs and tissues include the gastrointestinal system, bone marrow,

testis, tongue, lung, and microvascular. When a tumor is located within or adjacent to these organs, their toxicities are major concerns that pose threats to patients' quality of life.^[4]

Toxicity to the gastrointestinal system is one of the major concerns for patients with gastrointestinal cancers. Among the different parts of the gastrointestinal system, the small intestine has the highest radiosensitivity. Duodenum is the first part of the intestine that may be exposed to a high total dose of radiation during radiotherapy for duodenal, liver, stomach, or pancreatic cancers.^[5-7] A pathological evaluation has reported that radiotherapy for gastric lymphoma led to severe damages to the vascular and villi and may continue for years after the end of treatment.^[8] Furthermore, it has been

Masoud Najafi,
Mohsen Cheki¹,
Gholamreza
Hassanzadeh²,
Peyman Amini³,
Dheyauldeen
Shabeeb^{4,5},
Ahmed Elejo
Musa^{4,6}

From the Department of Radiology and Nuclear Medicine, School of Paramedical Sciences, Kermanshah University of Medical Sciences, Kermanshah, ¹Cancer Research Center, Ahvaz Jundishapur University of Medical Sciences, Ahvaz, ²Department of Anatomy, School of Medicine, Tehran University of Medical Sciences, ³Department of Radiology, Faculty of Paramedical, Tehran University of Medical Sciences, ⁴Department of Medical Physics and Biomedical Engineering, School of Medicine, Tehran University of Medical Science, International Campus, ⁶Research Center for Molecular and Cellular Imaging, Tehran University of Medical Sciences, Tehran, Iran, ⁵Department of Physiology, College of Medicine, University of Misan, Misan, Iraq

Address for correspondence:

Dr. Mohsen Cheki,
Cancer Research Center, Ahvaz
Jundishapur University of
Medical Sciences, Ahvaz, Iran.
E-mail: mohsencheiky@gmail.com

This is an open access journal, and articles are distributed under the terms of the Creative Commons Attribution-NonCommercial-ShareAlike 4.0 License, which allows others to remix, tweak, and build upon the work non-commercially, as long as appropriate credit is given and the new creations are licensed under the identical terms.

For reprints contact: reprints@medknow.com

How to cite this article: Najafi M, Cheki M, Hassanzadeh G, Amini P, Shabeeb D, Musa AE. The radioprotective effect of combination of melatonin and metformin on rat duodenum damage induced by ionizing radiation: A histological study. *Adv Biomed Res* 2019;8:51.

Received: March, 2019. **Accepted:** June, 2019.

Access this article online

Website: www.advbiores.net

DOI: 10.4103/abr.abr_68_19

Quick Response Code:



shown that radiotherapy induces chronic inflammation and ulceration in the duodenum, which may lead to bleeding for over a long time.^[9] A study showed that the treatment of pancreatic head cancer with hypofractionated stereotactic body radiation therapy (SBRT) led to duodenal injury, which has a direct relationship with the appearance of some side effects such as anorexia, abdominal discomfort, anemia, and diarrhea.^[10]

So far, efforts have been made by several studies to manage these serious side effects of radiotherapy. Localized radiotherapy is a recent radiotherapy technology with less toxicity. However, advanced treatment methods such as SBRT may be associated with some serious toxicities. One of the most interesting strategies for the amelioration of radiation toxicity is the use of some adjuvant agents that change responses to ionizing radiation in normal tissues. So far, several different agents have been discovered to counter the toxic effects of radiation.^[11-13] However, achieving an appropriate radioprotector with less toxicity remains unresolved. Melatonin and metformin are two Food and Drug Administration-approved drugs that are used by millions of people worldwide for regulating sleep and control of diabetes, respectively. Melatonin has shown potent antioxidant and anti-inflammatory properties, without serious side effect on the normal function of cells and tissues.^[14,15] Metformin has also attracted interests in recent years due to its promising property of protection against genotoxic agents, including ionizing radiation.^[16-18]

In the present study, we aimed to evaluate the possible radioprotective effect of a combination of melatonin and metformin in a safe dose. Furthermore, we compared our results with the radioprotective effect of melatonin, when administered alone.

Materials and Methods

Animals

Thirty male Wistar rats weighing 200 ± 20 g were purchased from Razi Institute, Tehran, Iran. Rats were kept under standard conditions (temperature of 22°C and 55% humidity). Furthermore, for control of light/dark cycle effect on the normal hemostasis of rats, a light/dark cycle of 5AM-5PM and 5PM-5AM was implemented. In addition, all animals were kept in the same room and fed with the same food and water. All study protocols were ratified in Animal Ethical Committee of Ahvaz Jundishapur University of Medical Sciences (IR. AJUMS. REC.1396.683).

Drugs preparation

Melatonin (98%) was purchased from Sigma Aldrich Company (the United States). Furthermore, metformin was provided by Tehran Chemie Pharmaceutical Company, Tehran, Iran. Melatonin was dissolved in absolute ethanol and then diluted to 15% ethanol with distilled

water. Metformin was dissolved completely in distilled water. Since the rats weighed 200 g, both melatonin and metformin solutions were prepared using 20 mg/ml. This was equal to 100 mg/kg body weight for each rat, based on our previous studies. For preparing melatonin plus metformin solution, melatonin was first dissolved in ethanol, followed by adding metformin to 15% ethanol, to achieve a concentration of 20 mg melatonin plus 20 mg metformin in each milliliter.

Irradiation

Irradiation was performed using a cobalt-60 (⁶⁰Co) gamma-ray source (1.25 MeV). Before irradiation, all rats were anesthetized using ketamine and xylazine (80 mg/kg and 5 mg/kg, respectively). Afterward, rats were placed supine under the ⁶⁰Co source, with their whole body exposed to 10 Gy at 95 cGy/min and source to skin distance of 60 cm. This dose of radiation selected based on previous studies.^[19,20]

Experimental design

Rats were divided into the following six groups (5 rats in each): G1: Control without any intervention except anesthesia drugs; G2: Rats received only oral administration of 100 mg/kg melatonin for 4 days; G3: Rats received only oral administration of 100 mg/kg melatonin plus 100 mg/kg metformin for 4 days; G4: Rats received 10 Gy gamma rays without any drugs; G5: Rats received 10 Gy gamma rays in addition to 100 mg/kg melatonin per day from 24 h before irradiation to 72 h after; G6: Rats received 10 Gy gamma rays in addition to 100 mg/kg melatonin plus 100 mg/kg metformin per day from 24 h before to 72 h after irradiation. The selected doses of melatonin and metformin were chosen based on previous studies.^[21,22] As earlier mentioned, treatments with melatonin or melatonin plus metformin started from 24 h before irradiation and continued for 4 days. On the day of irradiation, melatonin or its combination with metformin was administered 30 min before irradiation as orally gavage. Groups 2 and 3 received melatonin as well as its combination with metformin using the same dose and time. Three days after irradiation, all rats were sacrificed, and their duodenum tissues were taken out and fixed in 10% normal buffer formalin.

Histopathological evaluation

After the completion of tissue fixation, all samples were embedded in paraffin. Four-micron thickness samples were provided. The provided samples were located on the glass slides and then stained with hematoxylin and eosin. The prepared slides were studied for histological changes such as congestion of blood vessels, degenerative changes, and necrosis of lamina propria, intestinal mucositis changes, inflammatory cells infiltration, degenerative changes of Brunner's glands, villi height, and goblet cell numbers in each villus. Slides were read using a light microscope (OPTIKA, Italy) with $\times 100$ and $\times 400$. Results

were scored from 0 to 3, indicating normal, mild, moderate, and severe changes, respectively. Furthermore, crypt depth and villus height were measured using image tool 2 of OPTIKA software, OPTIKA microscope, Italy.

Statistical analysis

After reading all slides, results were scored and reported as mean \pm standard deviation. Data were analyzed using SPSS software version 16 (IBM, Chicago, USA). Nonparametric Mann–Whitney test was used to examine the differences between groups. These differences at $P < 0.05$ were considered statistically significant.

Results

The results of histopathological evaluation of radioprotective effect of melatonin and its combination with metformin in rat's duodenum are presented in Table 1.

Congestion of blood vessels

Results showed no congestion of vessels in the control, melatonin or melatonin plus metformin-treated rats (0.00 ± 00). Irradiation of rats with gamma rays led to significant damages to the blood vessels (2.70 ± 0.31 , $P = 0.009$). Treatment with melatonin significantly attenuated blood vessel congestion compared with non-treated irradiated rats (0.50 ± 0.57 , $P = 0.022$). While metformin plus melatonin treatment before and after irradiation could not alleviate vessels' injury (1.60 ± 0.54 , $P = 0.34$).

Degenerative changes and necrosis of lamina propria

Results showed that treatment with melatonin or melatonin plus metformin had no deleterious effect on the lamina propria (0.00 ± 00). However, exposure to radiation caused a moderate necrosis of lamina propria (1.8 ± 0.45 , $P = 0.007$). The administration of melatonin before and after irradiation showed a significant reduction of damage to the lamina (0.75 ± 0.50 , $P = 0.023$). In contrast to melatonin, the administration of the combination of melatonin with metformin could not ameliorate necrosis of lamina propria (1.20 ± 0.44 , $P = 0.057$).

Intestinal mucositis changes

Similar to other parameters, treatment with melatonin or its combination with metformin had no inflammatory response in the duodenum (0.00 ± 00). Whole body irradiation of rats led to moderate mucositis in the duodenum (1.80 ± 0.44 , $P = 0.007$). Treatment with either melatonin or melatonin plus metformin were able to reduce the severity of mucositis (0.20 ± 0.50 , $P = 0.013$; 0.00 ± 0.00 , $P = 0.004$, respectively).

Inflammatory cells infiltration

The histological evaluation showed that treatment with melatonin or melatonin plus metformin did not cause any infiltration of inflammatory cells. Whole body irradiation of rats led to a mild infiltration of inflammatory cells (1.20 ± 0.44 , $P = 0.007$). Treatment with melatonin before and after irradiation could completely reverse infiltration of inflammatory cells (0.00 ± 00 , $P = 0.007$), while treatment with melatonin plus metformin could not ameliorate infiltration of inflammatory cells, a result which was similar to nontreated irradiated rats (1.20 ± 0.44 , $P = 1.00$).

Degenerative changes of Brunner's glands

Results showed no degenerative changes for Brunner's glands in the control group, as well as treatment with melatonin or melatonin plus metformin (0.00 ± 00). Whole body irradiation with gamma rays led to moderate-to-severe changes in the Brunner's glands (2.00 ± 0.70 , $P = 0.009$). Treatment with either melatonin or melatonin plus metformin could reverse these changes completely (0.00 ± 00 , $P = 0.009$ and $P = 0.005$, respectively).

Goblet cells per duodenum villi

For the control group, the number of goblet cells per villi was 44 ± 0.82 . Treatment with melatonin led to a significant increase in goblet cells (48.24 ± 0.96 , $P = 0.029$). However, treatment with metformin plus metformin had no effect on the number of goblet cells (45 ± 0.82). Irradiation of rats led to a remarkable reduction in goblet cells compared

Table 1: Results of histopathological evaluation of radioprotective effect of melatonin and its combination with metformin in rat's duodenum

Histopathological parameters -	Control	MLT	MLT + MET	RAD	RAD + MLT	RAD + MLT + MET
Congestion of blood vessels	0.00±00	0.00±00	0.00±00	2.70±0.31	0.50±0.57	1.60±0.54
Degenerative changes and necrosis of lamina propria	0.00±00	0.00±00	0.00±00	1.8±0.45	0.75±0.50	1.20±0.44
Intestinal mucositis changes	0.00±00	0.00±00	0.00±00	1.80±0.44	0.20±0.50	0.00±00
Inflammatory cells infiltration	0.00±00	0.00±00	0.00±00	1.20±0.44	0.00±00	1.20±0.44
Degenerative changes of Brunner's glands	0.00±00	0.00±00	0.00±00	2.00±0.70	0.00±00	0.00±00
Goblet cells per duodenum villi	44±0.82	48.24±0.96	45±0.82	9.2±0.84	28±0.82	19.80±1.30
Crypt depth	419±119 μ m	382±75 μ m	388±40 μ m	119±40 μ m	180±29 μ m	241±39 μ m
Villous height	1248±37 μ m	1250±50 μ m	1186±25 μ m	546±123 μ m	1058±92 μ m	987±162 μ m

MLT: Melatonin, MET: Metformin, RAD: Radiation

to the control group (9.2 ± 0.84 , $P = 0.013$). Treatment with melatonin before and after irradiation led to a significant increase in goblet cells compared to radiation group (28 ± 0.82 , $P = 0.013$). Treatment with metformin plus melatonin also increased the number of goblet cells (19.80 ± 1.30 , $P = 0.008$), while its effect was weaker compared with melatonin administered alone ($P = 0.014$).

Crypt depth

Results of crypt depth evaluation showed that the crypt depth for control was equal to $419 \pm 119 \mu\text{m}$. For the irradiated rats, their crypt depths were reduced significantly compared with control group ($119 \pm 40 \mu\text{m}$) ($P = 0.001$). Treatment with melatonin increased crypt depth to $180 \pm 29 \mu\text{m}$ ($P = 0.009$). Similarly, treatment with the combination of melatonin and metformin could improve crypt depth to $241 \pm 39 \mu\text{m}$ ($P = 0.001$). The comparison between these two groups showed that the combination of melatonin with metformin had more effect on the preservation of crypt depth ($P = 0.004$).

Villous height

Results showed that villous height for the control was equal to $1248 \pm 37 \mu\text{m}$. Whole body irradiation of rats led to a significant reduction of villous height ($546 \pm 123 \mu\text{m}$) ($P < 0.001$). Treatment with melatonin increased villous height to $1058 \pm 92 \mu\text{m}$ ($P < 0.001$). Furthermore, treatment with melatonin plus metformin before and after irradiation increased height of villous to $987 \pm 162 \mu\text{m}$ ($P < 0.001$) [Figure 1]. The comparison between these two groups showed no significant difference.

Discussion

Exposure to radiation leads to a change in several genes, which mediate increasing or reducing a wide range of cytokines, growth factors, hormones, and others. Exposure to a high dose of ionizing radiation causes the generation of a large amount of free radicals. This is associated with massive damage to DNA and other crucial organelles, and suppression of antioxidant defense enzymes. The unrepaired DNA damages cause cell death, mainly through apoptosis and mitotic catastrophe. However, damage to membrane and some organelles such as mitochondria may lead to necrosis and autophagy. High incidence of cell death in radiosensitive organs such as bone marrow and gastrointestinal system can trigger infiltration of inflammatory cells and release of a wide range of pro-inflammatory and pro-fibrosis cytokines such as interleukin-1 (IL-1), IL-4, IL-6, IL-8, IL-13, IL-33, tumor necrosis factor- α , interferon- γ , and transforming growth factor- β .^[23] The suppression of these cytokines and also related signaling pathways such as NLRP3/inflammasome, COX-2, NADPH Oxidase, and iNOS have suggested to protect and mitigate radiation toxicity in radiosensitive organs, including gastrointestinal system.^[24,25]

So far, several studies have been conducted to illustrate the radioprotective effect of melatonin on several radiosensitive tissues and organs such as the bone marrow, lung, heart, and testis.^[26,27] Metformin has also shown the ability to protect the bone marrow, lung, and heart.^[18,28,29] Melatonin is known as a circadian hormone that has potent

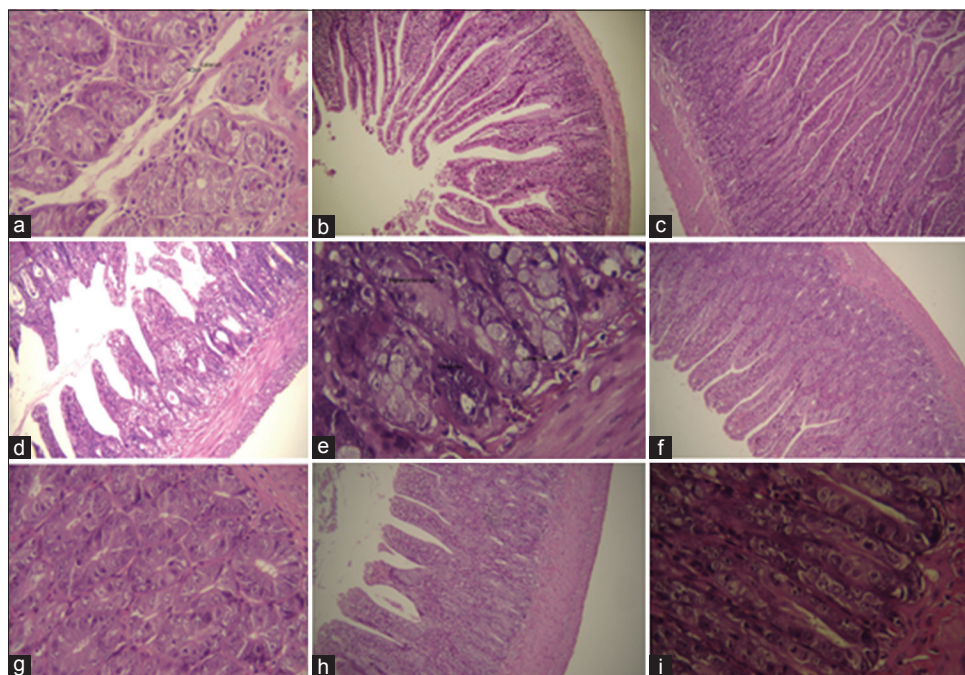


Figure 1: Histopathological evaluation of duodenum following whole body irradiation and treatment with melatonin or its combination with metformin. Treatment with melatonin and metformin did not cause any remarkable change in the histology of duodenum. (a): control; (b): melatonin treatment; (c): metformin treatment. Whole body irradiation led to shortening of villi (d, $\times 100$) and also congestion, degeneration, and reduction of goblet cells (e, $\times 400$). Irradiation plus melatonin treatment alleviate villi damage (f, $\times 100$) and other degenerative changes (g, $\times 400$). Irradiation plus melatonin and metformin treatment also reversed shortening of villi (h, $\times 100$), damage to goblet cells and degenerative changes (i, $\times 400$) (H and E staining)

antioxidant and anti-inflammation effects. In response to radiation, administration of melatonin can help DNA repair, stimulates activities of antioxidant enzymes especially superoxide dismutase and glutathione peroxidase, and prevents severe inflammatory reaction through reduction in the release of inflammatory cytokines and alleviation of macrophage activity.^[15] Melatonin has shown that mitigates jejunum injury following irradiation through suppression of NLRP3/inflammasome pathway. This is associated with a reduction of pro-inflammatory cytokines including IL-1 and IL-18, as well as suppression of chronic oxidative stress and mucositis.^[30] Melatonin also has shown that is able to prevent apoptosis and stimulation of pro-oxidant enzymes. It can suppress increased level of TGF- β , IL-4, IL-13, and attenuates the activation of ROS generating enzymes such as NADPH Oxidase, Dual Oxidase 1 and 2 (Duox 1 and 2), COX-2, and iNOS.^[31,32] These properties of melatonin can help to attenuate infiltration of macrophages and lymphocytes in irradiated tissues.^[32] Metformin triggers DNA damage responses which is mainly mediated through stimulation of AMP-activated protein kinase activity, which stimulates repair of damaged DNA through ATM pathway. Metformin also has the ability to neutralize-free radicals directly or through stimulation of antioxidant enzymes.^[5-7,14] Furthermore, metformin can activate p53 following phosphorylation of MDMX. Metformin also has shown that prevent late histopathological changes following exposure to radiation through downregulation of pro-inflammatory and pro-fibrosis cytokines.^[28] It also can suppress continuous free radicals' production through downregulation of NOX4, Duox 1 and 2, and COX-2.^[28,33,34] These properties of melatonin and metformin make them appropriate for use as radioprotectors. Interestingly, both metformin and melatonin have shown anticancer and radiosensitive effects.^[35,36] Differential effects of both metformin and melatonin may make them good candidates for clinical applications.

In the present study, we aimed to determine the radioprotective effect of melatonin as well as its combination with metformin on rat's duodenum. Results of our study showed that irradiation of rats led to infiltration of inflammatory cells, vascular injury, lamina propria necrosis, intestinal mucositis, and damages to Brunner's glands. Furthermore, irradiation led to severe reduction of goblet cells (to 20% compared with normal) in the duodenum. Treatment with melatonin could alleviate all duodenal injury parameters in this study. Melatonin was able to completely reverse Brunner's glands damage and inflammatory cells infiltration. Melatonin was also able to increase the number of goblet cells up to 60% compared to normal levels. Interestingly, our results showed that using a combinational form of melatonin with metformin had a lower protective effect compared to melatonin administered alone. This combination was able to completely reverse damages to Brunner's glands and mucositis. It also

increased the number of goblet cells up to 40%. However, this combination could not ameliorate infiltration of macrophages and lymphocytes, damages to vessels and lamina propria necrosis. By contrast, the combination of melatonin with metformin could improve crypt depth more effectively compared to melatonin alone. However, no significant difference was observed for villous height when rats were treated with melatonin or its combination with metformin.

So far, some other radioprotectors and antioxidants have been used for mitigation of radiation-induced small intestine injury, including duodenal toxicity. Studies have shown the radioprotective effects of amifostine, selenium, alpha-tocopherol, and some other antioxidants.^[5-7] In this study, we showed that melatonin as well as its combination with metformin can be proposed for the alleviation of radiation-induced duodenal mucositis, while melatonin administered alone may have a more potent protective effect. However, in some studies, it has been shown that combination of melatonin and metformin do not have any interaction and is more effective compared to single drug for the treatment of polycystic ovary syndrome, glucose metabolism, circadian disruption, and diet-induced obesity.^[37-39] The combination of melatonin with some other radioprotectors has investigated to improve normal tissues sparing following exposure to radiation. A study by Li *et al.* showed that the combination of melatonin and alpha-lipoic acid can protect bone marrow and reduce NOX4 upregulation more effectively compared to melatonin alone.^[40] Similar results also have shown for human lymphocytes.^[13] By contrast, a study by Topkan *et al.* showed that the combination of melatonin and amifostine do not cause any improvement in the protection of rats bone against ionizing radiation.^[41] By contrast, in the current study, we showed that metformin attenuates radioprotective effect of melatonin in duodenum. Further studies are needed to explore possible mechanisms for melatonin and metformin combination in different tissues, including duodenum to explain possible interactions or improvements in the normal tissues radioprotection.

Conclusion

This study was conducted to evaluate the possible radioprotective effect of melatonin as well as its combination with metformin for amelioration of radiation-induced duodenal injury. Our results showed that whole body irradiation led to mild-to-moderate increase in the signs of mucositis in rat's duodenum. Pre- and post-administration of melatonin plus metformin could alleviate mucositis. However, our results showed that the administration of melatonin was more effective for mitigation of duodenal injury compared with melatonin plus metformin.

Financial support and sponsorship

This research was supported by the Cancer Research Center (Grant number: CRC-9608) from the vice chancellor of research at Ahvaz Jundishapur University of Medical Sciences (Iran).

Conflicts of interest

There are no conflicts of interest.

References

- Mofid B, Razzaghdoust A, Kashi AS, Mirzaei HR. A comparative study of cisplatin-based definitive chemo-radiation in non-metastatic squamous cell carcinoma of the esophagus. *Electron Physician* 2016;8:3069-75.
- Saadipoor A, Razzaghdoust A, Simforoosh N, Mahdavi A, Bakhshandeh M, Moghadam M, *et al.* Randomized, double-blind, placebo-controlled phase II trial of nanocurcumin in prostate cancer patients undergoing radiotherapy. *Phytother Res* 2019;33:370-8.
- Razzaghdoust A, Mozdarani H, Mofid B. Famotidine as a radioprotector for rectal mucosa in prostate cancer patients treated with radiotherapy: Phase I/II randomized placebo-controlled trial. *Strahlenther Onkol* 2014;190:739-44.
- Mofid B, Razzaghdoust A, Peyghambarlou P. 436P Identifying predictive factors for severe anemia in cancer patients treated with cytotoxic chemotherapy. *Ann Oncol* 2018;29:133-135.
- Elhammali A, Patel M, Weinberg B, Verma V, Liu J, Olsen JR, *et al.* Late gastrointestinal tissue effects after hypofractionated radiation therapy of the pancreas. *Radiat Oncol* 2015;10:186.
- Prior P, Tai A, Erickson B, Allen Li X. Consolidating duodenal and small bowel toxicity data via isoeffective dose calculations based on compiled clinical data. *Pract Radiat Oncol* 2014;4:e125-31.
- Kim H, Lim DH, Paik SW, Yoo BC, Koh KG, Lee JH, *et al.* Predictive factors of gastroduodenal toxicity in cirrhotic patients after three-dimensional conformal radiotherapy for hepatocellular carcinoma. *Radiother Oncol* 2009;93:302-6.
- Iwamuro M, Tanaka T, Kanzaki H, Kawano S, Kawahara Y, Iwasaki Y, *et al.* Deterioration of duodenal lymphangiectasia after radiotherapy for gastric MALT lymphoma. *Ecancermedicinescience* 2017;11:752.
- Holyoake DL, Aznar M, Mukherjee S, Partridge M, Hawkins MA. Modelling duodenum radiotherapy toxicity using cohort dose-volume-histogram data. *Radiother Oncol* 2017;123:431-7.
- Lin C, Lazenby AJ, Bhirud AR, Sehi ED, Zheng D. A Dosimetric analysis of duodenal toxicity after hypofractionated stereotactic body radiation therapy for pancreatic cancer. *Int J Radiat Oncol Biol Phys* 2013;87:S29.
- Willis J, Epperly MW, Fisher R, Zhang X, Shields D, Hou W, *et al.* Amelioration of head and neck radiation-induced mucositis and distant marrow suppression in *fanca*^{-/-} and *fancc*^{-/-} mice by intraoral administration of GS-nitroxide (JP4-039). *Radiat Res* 2018;189:560-78.
- Mishra K, Alsbeih G. Appraisal of biochemical classes of radioprotectors: Evidence, current status and guidelines for future development 3 *Biotech* 2017;7:292.
- Kopjar N, Miocić S, Ramić S, Milić M, Viculin T. Assessment of the radioprotective effects of amifostine and melatonin on human lymphocytes irradiated with gamma-rays *in vitro*. *Arh Hig Rada Toksikol* 2006;57:155-63.
- Esposito E, Cuzzocrea S. Antiinflammatory activity of melatonin in central nervous system. *Curr Neuropharmacol* 2010;8:228-42.
- Favero G, Franceschetti L, Bonomini F, Rodella LF, Rezzani R. Melatonin as an anti-inflammatory agent modulating inflammasome activation. *Int J Endocrinol* 2017;2017:1835195.
- Kolivand S, Motevaseli E, Cheki M, Mahmoudzadeh A, Shirazi A, Fait V. The anti-apoptotic mechanism of metformin against apoptosis induced by ionizing radiation in human peripheral blood mononuclear cells. *Klin Onkol Fall*; 30:372-9.
- Kim JM, Yoo H, Kim JY, Oh SH, Kang JW, Yoo BR, *et al.* Metformin alleviates radiation-induced skin fibrosis via the downregulation of FOXO3. *Cell Physiol Biochem* 2018;48:959-70.
- Xu G, Wu H, Zhang J, Li D, Wang Y, Wang Y, *et al.* Metformin ameliorates ionizing irradiation-induced long-term hematopoietic stem cell injury in mice. *Free Radic Biol Med* 2015;87:15-25.
- Abbas B, Boyle FC, Wilson DJ, Nelson AC, Carr KE. Radiation induced changes in the blood capillaries of rat duodenal villi: A corrosion cast, light and transmission electron microscopical study. *J Submicrosc Cytol Pathol* 1990;22:63-70.
- Howarth GS, Fraser R, Frisby CL, Schirmer MB, Yeoh EK. Effects of insulin-like growth factor-I administration on radiation enteritis in rats. *Scand J Gastroenterol* 1997;32:1118-24.
- Choi YH, Kim SG, Lee MG. Dose-independent pharmacokinetics of metformin in rats: Hepatic and gastrointestinal first-pass effects. *J Pharm Sci* 2006;95:2543-52.
- Tahan G, Gramignoli R, Marongiu F, Aktolga S, Cetinkaya A, Tahan V, *et al.* Melatonin expresses powerful anti-inflammatory and antioxidant activities resulting in complete improvement of acetic-acid-induced colitis in rats. *Dig Dis Sci* 2011;56:715-20.
- Robbins ME, Zhao W. Chronic oxidative stress and radiation-induced late normal tissue injury: A review. *Int J Radiat Biol* 2004;80:251-9.
- Theis VS, Sripadam R, Ramani V, Lal S. Chronic radiation enteritis. *Clin Oncol (R Coll Radiol)* 2010;22:70-83.
- Haagen J, Krohn H, Röllig S, Schmidt M, Wolfram K, Dörr W. Effect of selective inhibitors of inflammation on oral mucositis: Preclinical studies. *Radiother Oncol* 2009;92:472-6.
- Farhood B, Goradel NH, Mortezaee K, Khanlarkhani N, Salehi E, Nashtaei MS, *et al.* Melatonin as an adjuvant in radiotherapy for radioprotection and radiosensitization. *Clin Transl Oncol* 2019;21:268-79.
- Aliasgharzadeh A, Farhood B, Amini P, Saffar H, Motevaseli E, Rezapoor S, *et al.* Melatonin attenuates upregulation of Duox1 and Duox2 and protects against lung injury following rchest irradiation in rats. *Cell J* 2019;21:236-242.
- Azmoonfar R, Amini P, Saffar H, Rezapoor S, Motevaseli E, Cheki M, *et al.* Metformin protects against radiation-induced pneumonitis and fibrosis and attenuates upregulation of dual oxidase genes expression. *Adv Pharm Bull* 2018;8:697-704.
- Yahyapour R, Amini P, Saffar H, Rezapoor S, Motevaseli E, Cheki M, *et al.* Metformin protects against radiation-induced heart injury and attenuates the up-regulation of dual oxidase genes following rat's chest irradiation. *Int J Mol Cell Med* 2018;7:-193-202.
- Fernández-Gil B, Moneim AE, Ortiz F, Shen YQ, Soto-Mercado V, Mendivil-Perez M, *et al.* Melatonin protects rats from radiotherapy-induced small intestine toxicity. *PLoS One* 2017;12:e0174474.
- Najafi M, Shirazi A, Motevaseli E, Geraily G, Amini P, Tooli LF, *et al.* Melatonin modulates regulation of NOX2 and NOX4 following irradiation in the lung. *Curr Clin Pharmacol* 2019;15:2-8.

32. Amini P, Mirtavoos-Mahyari H, Motevaseli E, Shabeeb D, Musa AE, Cheki M, *et al.* Mechanisms for radioprotection by melatonin; can it be used as a radiation countermeasure? *Curr Mol Pharmacol* 2019; 12:2-11.
33. Lu CH, Chung CH, Lee CH, Hsieh CH, Hung YJ, Lin FH, *et al.* Combination COX-2 inhibitor and metformin attenuate rate of joint replacement in osteoarthritis with diabetes: A Nationwide, retrospective, matched-cohort study in Taiwan. *PLoS One* 2018;13:e0191242.
34. Sato N, Takasaka N, Yoshida M, Tsubouchi K, Minagawa S, Araya J, *et al.* Metformin attenuates lung fibrosis development via NOX4 suppression. *Respir Res* 2016;17:107.
35. Galdieri L, Gatla H, Vancurova I, Vancura A. Activation of AMP-activated protein kinase by metformin induces protein acetylation in prostate and ovarian cancer cells. *J Biol Chem* 2016;291:25154-66.
36. Taylor M, Mert I, Hijaz M, Chhina J, Morris RT, Giri S, *et al.* Effects of an olaparib and metformin combination on the AMPK and DNA-damage pathways in ovarian cancer. *Gynecol Oncol* 2016;141:197-198.
37. Thomas AP, Hoang J, Vongbunyong K, Nguyen A, Rakshit K, Matveyenko AV, *et al.* Administration of melatonin and metformin prevents deleterious effects of circadian disruption and obesity in male rats. *Endocrinology* 2016;157:4720-31.
38. Lemos-Jordão AJ, Costa FS, Peixoto CA, Teixeira AA, Silva SB, Ferreira SG, *et al.* Combination of melatonin and metformin hydrochloride for treatment polycystic ovarian in female rats. *Acta Sci Vet* 2016;44:1408.
39. Dantas-Ferreira RF, Raingard H, Dumont S, Schuster-Klein C, Guardiola-Lemaitre B, Pevet P, *et al.* Melatonin potentiates the effects of metformin on glucose metabolism and food intake in high-fat-fed rats. *Endocrinol Diabetes Metab* 2018;1:e00039.
40. Li D, Tian Z, Tang W, Zhang J, Lu L, Sun Z, *et al.* The protective effects of 5-methoxytryptamine- α -lipoic acid on ionizing radiation-induced hematopoietic injury. *Int J Mol Sci* 2016;17. pii: E935.
41. Topkan E, Tufan H, Yavuz AA, Bacanlı D, Onal C, Kosdak S, *et al.* Comparison of the protective effects of melatonin and amifostine on radiation-induced epiphyseal injury. *Int J Radiat Biol* 2008;84:796-802.