

Interaction of Sex Hormones and the Renin–Angiotensin System in Ovariectomized Rats Subjected to Ischemia-Reperfusion Induction

Abstract

Backgrounds: Ischemia-reperfusion (IR) injuries occur in a variety of clinical conditions, which lead to kidney damage. Most of the tissue damages after IR are due to the activation of the renin–angiotensin system (RAS). Hence, in this study, the interaction of sex hormones and RAS in ovariectomized (OV) rats subjected to IR induction has been studied. **Materials and Methods:** The animals were divided into different groups. Groups 1 (OV + E, OV rat + estradiol) and 2 (OV rat) each one consisted of three separate IR-induced subgroups treated with losartan, angiotensin 1–7 (Ang 1–7), and their combination, Group 3, as control and Group 4, as sham. Next, 72 h after IR, blood samples were collected, the right kidneys were homogenized, and left kidneys were fixed in 10% formalin. **Results:** Findings show that serum blood urea nitrogen, creatinine, and kidney tissue damage score levels increased significantly with induction of IR ($P < 0.05$). Mean serum levels of these factors in OV + E groups are higher than those of the OV. The presence or absence of estradiol did not affect the levels of antioxidants in the different groups receiving Los, Ang 1–7, and their combination. Los, Ang 1–7, and their combination reduced serum and kidney malondialdehyde levels in both OV and OV + E groups. **Conclusion:** Estrogen not only fails to improve renal functioning but it can also exacerbate it. While the treatments used in this study, in the absence of estradiol, it had a better effect on kidney damages and improved its functions.

Keywords: Estrogen, ischemia-reperfusion, losartan, renin–angiotensin system

Introduction

An ischemia-reperfusion injury (IRI) occurs in a variety of clinical conditions, such as organ transplants, septic shock, cardiovascular surgeries, can lead to acute kidney damages, which is associated with high mortality rates.^[1] Some evidence suggests that the presence of a protective effect of female sex hormones in several organs subjected to IRI.^[2] The exact mechanism of the effect of these hormones is still not well-defined.^[3] However, it is known that the renin–angiotensin system (RAS) is involved in this phenomenon.^[3] RAS with a multifarious complexity plays an important role in regulating body fluids and blood pressure. The components of this system are sex related. Likewise, sex hormones such as estradiol activate RAS.^[4] Vasodepressor arm of RAS includes angiotensin-converting enzyme type 2 (ACE2), angiotensin type 2 receptor, Mas receptor, and angiotensin 1–7 (Ang 1–7). It is known that the

vasopressor arm, Ang II and angiotensin type 1 receptor (AT1) in male, and vasodepressor arm of RAS in female have more prominent roles in the process.^[4] Ang 1–7 is a biological active heptapeptide that is made by ACE2 from Ang II. Similarly, some studies have shown the existence of its antagonistic role against the effects of Ang II.^[5]

According to the literature, after ischemia-reperfusion (IR), the antioxidant system is weakened, the free radicals accumulate, and oxidative stress damage begins.^[6] On the other hand, with the onset of the regeneration phase, a large number of pathogens, such as inflammatory agents together with reactive oxygen species (ROS) are activated, leading to serious renal damage.^[7]

Experimental studies on OV mice show that estradiol (E2) therapy reduces AT1 activity by inhibiting ACE, while it decreases the Ang II tissue that finally enhances the effects of Ang 1–7 vasodilator.^[8] Due to this

**Halimeh Lakzaei,
Tahereh Safari,
Gholam Reza
Komeili**

*From the Department of
Physiology, School of Medicine,
Zahedan University of Medical
Sciences, Zahedan, Iran*

Address for correspondence:

*Dr. Tahereh Safari,
Department of Physiology,
School of Medicine, Infectious
Diseases and Tropical Medicine
Research Center; Resistant
Tuberculosis Institute, Zahedan
University of Medical Sciences,
Zahedan, Iran.
E-mail: tahereh_safari@yahoo.
com*

Access this article online

Website: www.advbiores.net

DOI: 10.4103/abr.abr_172_19

Quick Response Code:



How to cite this article: Lakzaei H, Safari T, Komeili GR. Interaction of sex hormones and the renin–angiotensin system in ovariectomized rats subjected to ischemia-reperfusion induction. *Adv Biomed Res* 2019;8:64.

Received: 16-08-2019; **Revised:** 22-09-2019;
Accepted: 29-09-2019; **Published:** 31-10-2019.

This is an open access journal, and articles are distributed under the terms of the Creative Commons Attribution-NonCommercial-ShareAlike 4.0 License, which allows others to remix, tweak, and build upon the work non-commercially, as long as appropriate credit is given and the new creations are licensed under the identical terms.

For reprints contact: reprints@medknow.com

effect, the greater activity of the vasodepressor arm in the female, it is likely that estradiol also affects the rest of the system components. Estradiol also has antioxidant effects which reduce ROS and upregulates the expression of antioxidant enzymes, by binding to the estrogen receptor.^[9] Hence, in this study, interaction of sex hormones and RAS in OV rats subjected to IR induction are going to be studied.

Materials and Methods

Animals

In this research, 64 female Wistar rats, weighting 162.0 ± 4.1 g, were housed at the room temperature of 23°C – 25°C with 12-h light/dark cycles and were allowed to acclimatize to the conditions for a week. The animals were fed with rat chow and water *ad libitum*. The protocol of experiment was approved in advance by the Zahedan University of Medical Sciences Ethics Committee Number IR.ZAUMS.REC.1397.188.

Chemicals

Estradiol valerate was purchased from Aburaihan (Tehran, Iran), sesame oil from Barij Essence (Kashan, Iran), losartan and Ang 1–7 from Sigma (St. Louis, MO, USA), and ketamine and xylazine from Sigma (St. Louis, MO, USA).

Ovariectomy surgery

A week before the administration of estradiol, animals were anesthetized with ketamine and xylazine, 75 and 10 mg/kg, i.p., respectively. An incision measuring 2 cm in length was made in the subabdominal area. After cutting the abdominal skin, the muscles were opened, and then the intestine was retracted. The ureteric tube and the vascular base of ovaries were ligated, and the ovaries were removed. Finally, the muscle and skin incisions were closed with sutures separately. Next, the animals were allowed to recover and acclimatize to the regular diet for a week.^[10]

Experimental protocol

The animals were divided into two main groups: (a) ovariectomized (OV) female rats (Groups 1 and 2), (b) non-OV female rats (Groups 3 and 4).

OV female rats consist of Groups 1 and 2 each one including three separate IR-induced subgroups receiving medication 15 min before the induction of IR.^[11] Group 1 ($n = 24$) was OV female rats (OV + E) and received estradiol valerate (250 $\mu\text{g}/\text{kg}/\text{week}$) solved in sesame oil intramuscularly for 4 weeks.^[12] After the last injection of estradiol valerate, the rats underwent IR. Group 2 ($n = 24$) was OV females and received sesame oil intramuscularly for 4 weeks. After last injection of sesame oil, the animals underwent IR. Both groups were treated with losartan 10 mg/kg,^[13] Ang 1–7 (50 $\mu\text{g}/\text{kg}$),^[11] and the combination of losartan and Ang 1–7, respectively.

Losartan and Ang 1–7 were administered intraperitoneally, 15 min before the induction of IR.^[11]

Non-OV female rats include Groups 3 and 4. Group 3 ($n = 8$) or control group received sesame oil intramuscularly as placebo once a week for 4 weeks. At the end of the 4th week, they received 0.5 ml saline, 15 min before IR.^[11] Group 4 ($n = 8$) or sham operated group, in this group only, the skin was opened followed by being sutured without the induction of IR.

On the day of IR induction, the animals were anesthetized with the mixture of xylazine (10 mg/kg, i.p.) and ketamine 75 mg/kg, i.p.^[12] The skin was incised prior to the removal of lumbar tissues and then the kidneys were cautiously accessible to avoid being hurt. To achieve the kidney IR in animals, the renal artery and vein were instantaneously obstructed in both kidneys, using clamps on the vessels for 45 min.^[13] Then, the clamps were detached carefully to ensure blood circulation into the kidneys. The same surgical procedure was done on the animals in all groups, except the sham group in which the vessels were not clamped. Seventy-two hours after the IR, blood samples were taken from the heart under anesthetization. Then, the right kidneys were excised, weighted, and homogenized. Next, the left kidney tissues were fixed in 10% formalin to be sent to the laboratory for pathological examinations. The uteruses were weighted at the end of the experiment.

Measurements

The level of blood urea nitrogen (BUN) and creatinine (Cr) in serums was measured using quantitative diagnostic kits (Pars Azmoon, Iran). The levels of nitrite in serum and the amount of supernatant (stable NO metabolite) were determined by means of a colorimetric assay kit (Zelbio, Germany) involving the Griess reaction. Malondialdehyde (MDA) levels of serum and the supernatant from the homogenized tissue were measured based on the manual methodology.^[14,15] Furthermore, catalase (CAT), glutathione (GSH), glutathione peroxidase (GPX), total antioxidant capacity (TAC), and superoxide dismutase (SOD) were measured using a colorimetric assay kit (Zelbio, Germany). After removal, the kidneys were fixed in 10% formalin solution. The hematoxylin and eosin staining were performed to test the tissue damage. Based on the percentage of renal damage, the samples were scored 1–4, where 0 was assigned to the normal tissue.

Statistical analysis

The data are expressed as mean \pm standard error of the mean. The levels of BUN, Cr, MDA, nitrite, CAT, GSH, GPX, TAC, SOD, body weights, kidney weights, and uterus weights were analyzed using one-way analysis of variance followed by the least significant difference test. Likewise, the groups were compared by the Kruskal–Wallis or Mann–Whitney U-tests with regard to the kidney

tissue damage score (KTDS). $P \leq 0.05$ was considered as statistically significant using SPSS version 16 (Chicago, IL, USA).

Results

The results of the mean weight of animals between the first and the last days did not show any significant differences between the groups. The mean left kidney weight in the studied groups did not show any significant differences [Table 1]. Likewise, the mean uterine weight indicates a significant difference between the groups. This treatment with estradiol significantly increases the weight of the uterus in groups receiving estradiol as shown in Table 1 ($P < 0.05$).

The results indicated that serum BUN and Cr levels increased significantly with the induction of IR in the control group compared to the sham group ($P < 0.05$) as depicted in Table 1. It should be noted that the mean serum level of these two factors in OV + E groups is higher than those of the OV, but such a difference was significant only for Cr ($P < 0.05$).

The induction of IR has caused severe tissue damage to the kidneys in the control group compared to the sham

group. The administration of estrogen worsens this damage in OV + E groups. The treatments include Losartan, Ang 1-7 and their combination in the absence of estrogen (OV groups) having a better effect on tissue damage, treatment with losartan, Ang 1-7, and their combination together caused a significant reduction ($P < 0.05$) of tissue damage in both groups OV + E and OV [Table 1]. This finding confirms the results of the pathological evaluations as shown in Figure 1.

The results of the serum antioxidant level indicate that the induction of IR has no effect on the activities of SOD and GPX but it reduces CAT, GSH, and TAC in the control group compared to that of the sham group ($P < 0.05$). The administration of estradiol did not effect on GPX, CAT, and GSH, but increased TAC levels in OV + E groups as depicted in Table 2.

Similarly, the results of the study indicate that the induction of IR has no effect on the level of SOD, CAT, and GSH in the kidney, but it decreased GPX and TAC levels in the control group compared to the sham group. With the exception of GPX, the presence or absence of estradiol did not affect these factors in the different groups receiving Los, Ang 1-7, and their combination [Figures 2 and 3]. In

Table 1: Evaluation of delta body weight, uterine weight, kidney weight, blood urea nitrogen, creatinine, and kidney tissue damage score, the groups received saline, losartan 10 mg/kg, angiotensin 1-7, 50 µg/kg, and angiotensin 1-7 + losartan before ischemia/reperfusion

Parameter	Groups							
	Control	Sham	Losartan		Angiotensin 1-7		Angiotensin 1-7 + losartan	
			OV + E	OV	OV + E	OV	OV + E	OV
BW g	-10.5±0.76	-9.66±0.33	-1.83±5.93	-9.4±1.00	-8.57±1.61	-11.2±1.15	-1.16±1.97	-9.75±1.60
KW g/100 g BW	1.05±0.05	0.83±0.06	1.05±0.07	1.00±0.05	0.96±0.05	1.08±0.05	0.92±0.06	1.10±0.05
UW g/100 g BW	0.21±0.01	0.23±0.06	4.23±0.35	0.14±0.00 [†]	5.18±0.42	0.15±0.00 [†]	2.60±0.33	0.11±0.01 [†]
BUN	46.83±0.74*	27.20±2.06	43.09±1.69	30.11±1.06	37.10±3.34	31.00±2.88	40.66±1.15	37.05±1.86
Creatinine	1.04±0.09*	0.46±0.03	0.59±0.04	0.45±0.01 [†]	0.59±0.02	0.43±0.01 [†]	0.56±0.02	0.57±0.01
KTDS	4.00±0.00* [@]	0.1±0.00	3.5±0.22	1.10±0.10 [†]	3.85±0.20	1.20±0.10 [†]	3.83±0.16	1.14±0.14 [†]

*Significant differences were compared to sham group, [†]Significant differences were compared to OV + E groups, [@]significant differences were compared to OV groups ($P \leq 0.05$). BW: Body weight/g, KW g/100 g BW: Kidney weight per 100 g of BW, UW g/100 g BW: Uterine weight per 100 g of BW, BUN: Blood urea nitrogen, KTDS: Kidney tissue damage score, OV + E: Ovariectomized + estradiol

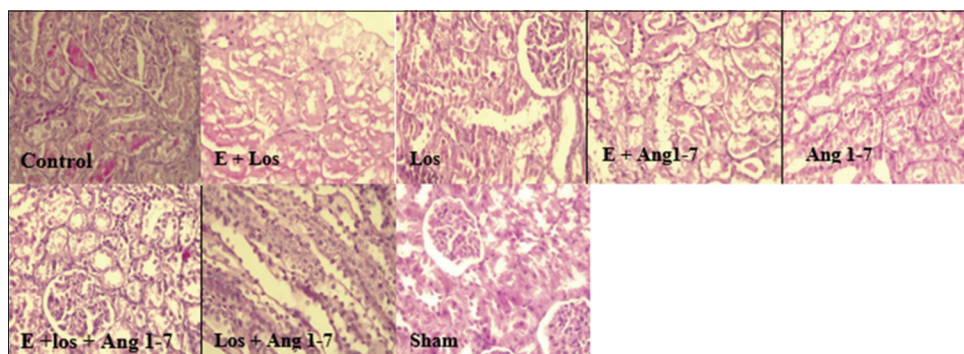


Figure 1: The pathology images (x400) of the kidney tissue in eight experimental groups. The groups received saline (control), estradiol 250 µg/kg/week + losartan, 10 mg/kg (E + Los), losartan (Los), estradiol + angiotensin 1-7, 50 µg/kg (E + Ang 1-7), angiotensin 1-7 (Ang 1-7), estradiol + losartan + angiotensin 1-7 (E + Los + Ang 1-7), losartan + angiotensin 1-7 (Los + Ang 1-7, and sham. The effect of each treatment was evaluated in animals after the induction of ischemia-reperfusion

Table 2: Evaluation of superoxide dismutase, glutathione peroxidase, catalase activity, glutathione, total antioxidant capacity, malondialdehyde, and nitrite levels of serum

Parameter	Groups							
	Control	Sham	Losartan		Angiotensin 1-7		Angiotensin 1-7 + losartan	
			OV + E	OV	OV + E	OV	OV + E	OV
SOD (U/ml)	16.38±1.06	17.88±0.61	15.48±0.83	16.88±0.54	15.06±1.00	16.06±0.89	17.96±0.54	17.76±0.67
GPX (U/ml)	484.69±12.14	510.95±24.08	608.77±40.97	569.80±20.45	608.54±34.72	631.46±22.26	433.83±1.40	578.91±5.07
CAT (U/ml)	10.81±0.24*	15.65±0.52	17.79±2.42	15.88±0.86	14.05±0.87	17.98±1.47	18.39±1.71	15.12±1.32
GSH (mg/l)	0.34±0.00*	0.49±0.02	0.58±0.02	0.55±0.02	0.50±0.09	0.41±0.02	0.67±0.07	0.79±0.01
TAC (μmol/l)	268.46±30.36*#	322.95±12.64	386.01±16.85†	282.27±13.68	404.81±23.06†	259.17±16.99	314.09±14.27†	261.98±11.22
MDA (μmol/l)	4.51±0.23	3.74±0.64	3.98±0.18	3.71±0.17	3.69±0.28	3.53±0.11	4.26±0.13	4.03±0.24
Nitrite (μmol/l)	25.58±1.22	26.22±0.73	25.98±1.04	19.56±0.44	31.31±2.54	24.08±2.18	30.95±2.05	27.32±1.41

The groups received saline, losartan 10 mg/kg, angiotensin 1-7, 50 μg/kg, and angiotensin 1-7 + losartan in animals before IR. *Significant differences compared to sham group, #Significant differences compared to OV + E and OV groups, †significant differences compared to OV+E groups ($P \leq 0.05$). SOD: Superoxide dismutase, GPX: Glutathione peroxidase, CAT: Catalase activity, GSH: Glutathione, TAC: Total antioxidant capacity, MDA: Malondialdehyde, IR: Ischemia/reperfusion, OV + E: Ovariectomized + estradiol

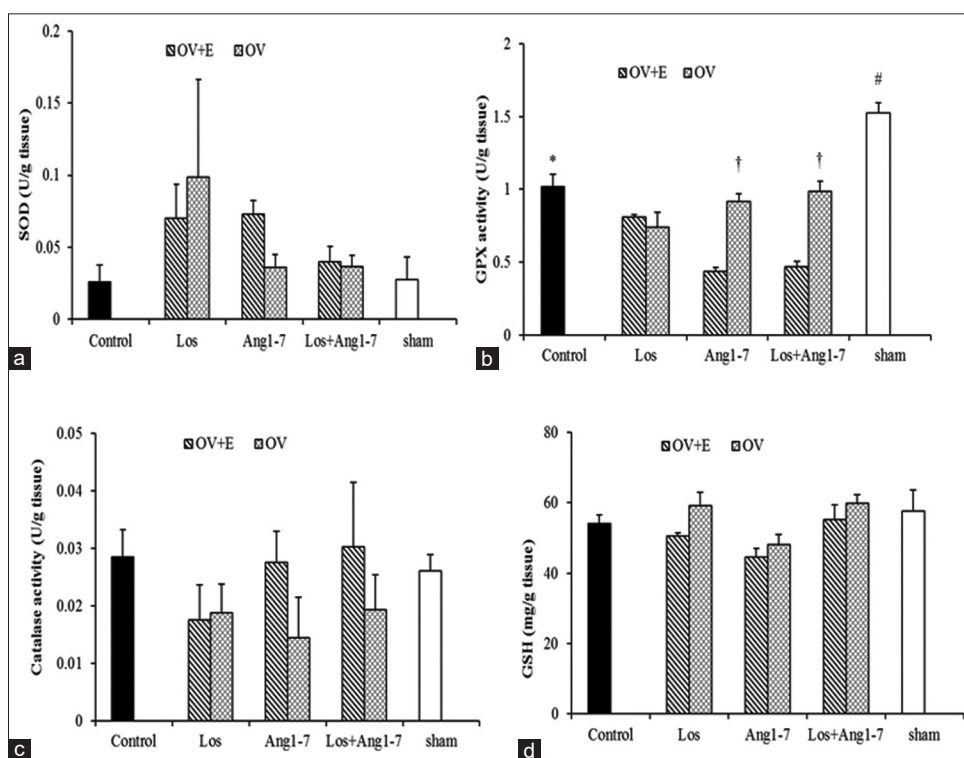


Figure 2: The evaluation of SOD (a), GPX (b), catalase activity (c), GSH (d) levels of kidney. The groups received saline, losartan, 10 mg/kg, angiotensin 1-7, 50 μg/kg, and angiotensin 1-7 + losartan in animals before IR. *Significant differences were compared to sham group, #Significant differences were compared to OV + E and OV groups; †Significant differences compared to OV + E groups; ($P \leq 0.05$). SOD: Superoxide dismutase, GPXS: Glutathione peroxidase, GSH: Glutathione, Los: Losartan, Ang: Angiotensin, IR: Ischemia/reperfusion

fact, in the absence of estradiol, administration of Ang 1-7 and its concomitant combination with losartan significantly increased GPX levels in OV groups compared to OV + E groups [Figure 2].

Based on the results, serum and renal nitrite levels in different groups were not significantly different [Table 2 and Figure 3], while the induction of IR has increased lipid peroxidation only in the kidneys, not in serum. In the control group, tissue level of MDA elevated in comparison with the sham group. Furthermore, the administration of estradiol did not affect its serum and tissue levels MDA in OV + E

groups [Table 2 and Figure 3]. Interestingly, treatment with Los, Ang 1-7, and Los + Ang 1-7 reduced kidney MDA level in both OV and OV + E groups [Figure 3].

Discussion

The most important findings of this study suggest that estrogen did not repair the IR damages. On the contrary, it exacerbated the injury. Losartan, Ang 1-7, and the combination of both in the absence of estrogen had a better effect on kidney tissue damage leading to the improvement of the kidney function.

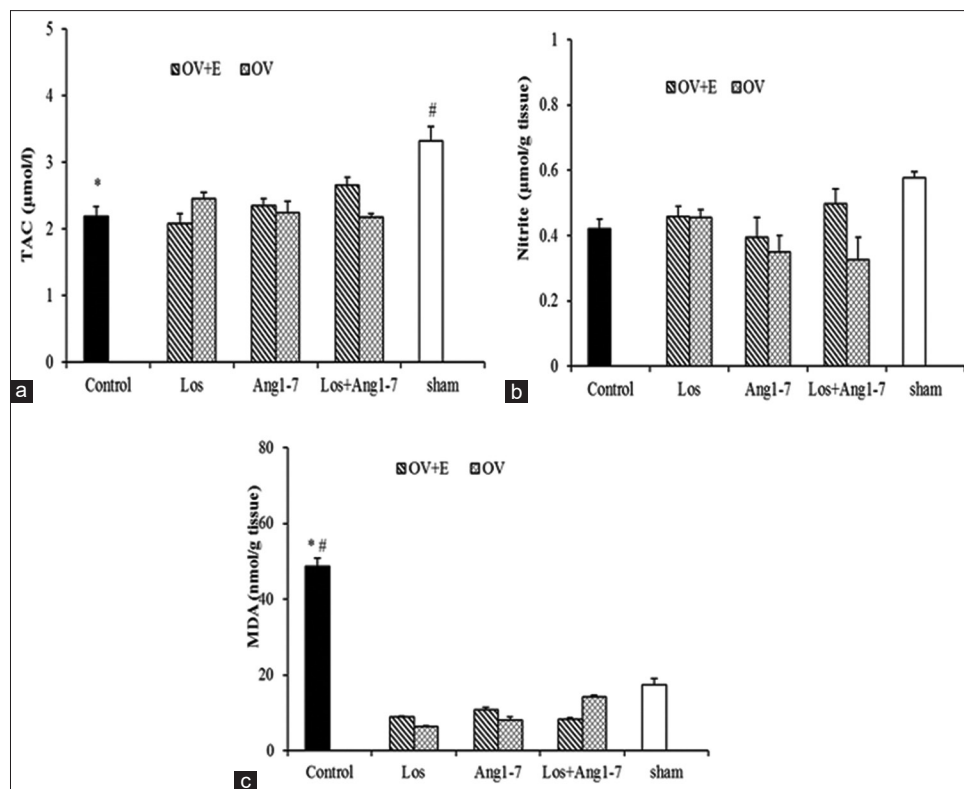


Figure 3: Evaluation of TAC (a), Nitrite (b) and MDA (c) levels of kidney. The groups received saline, losartan, 10 mg/kg, angiotensin 1–7, 50 µg/kg, and angiotensin 1–7 + losartan in animals before IR. *Significant differences were compared to sham group, #Significant differences were compared to OV + E and OV groups; ($P \leq 0.05$). TAC: Total antioxidant capacity; MDA: Malondialdehyde, Los: Losartan, Ang: Angiotensin, IR: Ischemia/reperfusion

Ang 1–7 is produced either by the ACE2 from Ang II or directly from Ang I by prolyl endopeptidase. The effect of Ang 1–7 is generally opposed to the vascular and proliferative effects of Ang II.^[16] This peptide has some complex effects on chronic kidney diseases and hypertension.^[17] Genetic deletion of the MasR increases blood pressure and reduces baroreflex function. Furthermore, it plays an important role in autonomic regulation of blood pressure.^[18]

Many studies have shown that after IR Ang II levels increase and Ang 1–7 levels decrease.^[19] It has also been argued that the ACE2 improves the damage in various disease models by increasing Ang 1–7 levels.^[20] The activation of the ACE2/Mas axis improves tissue damage caused by cardiac ischemia.^[21] In this regard, Malek and Nematbakhsh, have reported that DIZE as an endogenous activator of the ACE2 in male rats has improved kidney function and decreased levels of BUN, Cr, and renal damage, whereas such effect has not been seen in female rats. They consider different responses in male and female rats because downregulate the expression of mRNA ACE2 by ovarian hormones. Consequently, in the presence of these hormones in the female, the level of ACE2 in the female is reduced,^[22] which confirms the results of this study. Therefore, renal dysfunctioning and further tissue damages in estradiol-treated groups in this study may be due to this effect.

The study of Iran-Nejad *et al.* suggests the protective role of estradiol, as an antioxidant in IR injury in female rats, while it has not been shown to have a protective effect on the kidneys of the male rats.^[13] This protective effect of estrogen on the kidneys and the cardiovascular system is mediated by some effects on glomerular mesangial cells, smooth muscle, anti-inflammatory cytokines, and interleukin 6.^[23,24] It has also been reported that estradiol reduces albuminuria and glomerulosclerosis in hypertensive female rats^[25] by activating nitric oxide synthase and nitric oxide production and antioxidant effects.^[26] Another study has shown that estradiol improves IR injury with endothelin-1 suppression.^[27] Saberi *et al.* reported that estradiol improved renal blood flow (RBF) in response to Ang 1–7, and this effect is eliminated by blocking the MasR.^[28] Another study has shown estrogen therapy improved endothelial function in the arm arteries in women with high blood pressure after menopause.^[29] Lu *et al.* reported that the protective effects of Ang 1–7 on the kidney tissue by various mechanisms, including oxidative stress reduction, improve antioxidant status, reduce inflammation, and fibrosis.^[30] Fang *et al.* have shown that the deletion of ACE2 gene leads to an increase in cell inflammation, pro-inflammatory cytokines, and apoptosis in the IR model and exacerbates its damage.^[31] Regarding the effects of Ang 1–7, other studies have shown that increased Ang II/Ang 1–7 with increased inflammatory

factors such as tumor necrosis factor- α in the kidney tissue caused further damage and treatment with Ang 1–7 significantly reduced the amount of Ang II and the improvement of chronic kidney diseases.^[31] It has also been reported that ROS are responsible for activating the RAS and subsequently, increasing oxidative stress, inflammation, lipid peroxidation, cell death, and renal dysfunction.^[31]

Unlike the results of this study, Nematbakhsh and Safari have reported that the role of MasR and Ang 1–7 in the kidney in the female rats is stronger than that of male and attributes to the effects of estrogen onto the release of nitric oxide.^[32] Female sex hormones increase the AT 2 receptor,^[33] and the ratio AT2/AT1 is greater in female^[34] although more studies are needed on MasR and estrogen role. In the discussion of hormonal therapy with estradiol, estradiol in a high dose induces vascular contraction through AT2 dependent mechanisms and increases the risk of cardiovascular disease.^[10] Increasing tissue damage and decreasing kidney function in this study can be due to this phenomenon. Other studies have shown that IR damage to glomeruli and renal arteries can lead to reduced glomerular filtration rate and RBF. They have suggested that this effect is likely to be due to increased Ang II levels after IR and decreased nitric oxide activity and a change in vascular contraction. On the other hand, all of these effects have diminished after losartan use.^[35]

Conclusion

estrogen not only fails to improve renal functioning but also it can also exacerbate it. While blocking the AT1 receptor by losartan, Ang 1–7 administrations, and their combination in the absence of estradiol, it had a better effect on the kidney damages and improved its functions. It seems that estradiol causes unusual results with unknown mechanisms. Therefore, it can be concluded that estradiol neither reduces ischemic damages nor plays any observable role in preventing kidney damages as an antioxidant.

Acknowledgment

This research was supported by Zahedan University of Medical Sciences Grant NO: 8886.

Conflicts of interest

There are no conflicts of interest.

References

- Hassoun HT, Grigoryev DN, Lie ML, Liu M, Cheadle C, Tuder RM, *et al.* Ischemic acute kidney injury induces a distant organ functional and genomic response distinguishable from bilateral nephrectomy. *Am J Physiol Renal Physiol* 2007;293:F30-40.
- Robert R, Ghazali DA, Favreau F, Mauco G, Hauet T, Goujon JM. Gender difference and sex hormone production in rodent renal ischemia reperfusion injury and repair. *J Inflamm (Lond)* 2011;8:14.
- Sullivan JC. Sex and the renin-angiotensin system: Inequality

- between the sexes in response to RAS stimulation and inhibition. *Am J Physiol Regul Integr Comp Physiol* 2008;294:R1220-6.
- Fischer M, Baessler A, Schunkert H. Renin angiotensin system and gender differences in the cardiovascular system. *Cardiovasc Res* 2002;53:672-7.
- Chappell MC, Diz DI, Yunis C, Ferrario CM. Differential actions of angiotensin-(1-7) in the kidney. *Kidney Int Suppl* 1998;68:S3-6.
- de Groot H, Rauen U. Ischemia-reperfusion injury: Processes in pathogenetic networks: A review. *Transplant Proc* 2007;39:481-4.
- Slegtenhorst BR, Dor FJ, Rodriguez H, Voskuil FJ, Tullius SG. Ischemia/reperfusion injury and its consequences on immunity and inflammation. *Curr Transplant Rep* 2014;1:147-54.
- Owonikoko TK, Fabucci ME, Brown PR, Nisar N, Hilton J, Mathews WB, *et al.* *In vivo* investigation of estrogen regulation of adrenal and renal angiotensin (AT1) receptor expression by PET. *J Nucl Med* 2004;45:94-100.
- Borrás C, Gambini J, López-Grueso R, Pallardó FV, Viña J. Direct antioxidant and protective effect of estradiol on isolated mitochondria. *Biochim Biophys Acta* 2010;1802:205-11.
- Safari T, Nematbakhsh M, Evans RG, Denton KM. High-dose estradiol-replacement therapy enhances the renal vascular response to angiotensin II via an AT2-receptor dependent mechanism. *Adv Pharmacol Sci* 2015;2015:682745.
- Forte BL, Slosky LM, Zhang H, Arnold MR, Staatz WD, Hay M, *et al.* Angiotensin-(1-7)/Mas receptor as an antinociceptive agent in cancer-induced bone pain. *Pain* 2016;157:2709-21.
- Ghadirian F, Nematbakhsh M, Roozbehani S, Mazaheri S, Talebi A, Pezeshki Z, *et al.* Nonprotective role of losartan in cisplatin-induced nephrotoxicity in ovariectomized rat model treated with estradiol. *J Pharm Negat Results* 2015;6:2.
- Iran-Nejad A, Nematbakhsh M, Eshraghi-Jazi F, Talebi A. Preventive role of estradiol on kidney injury induced by renal ischemia-reperfusion in male and female rats. *Int J Prev Med* 2015;6:22.
- Miri S, Safari T, Komeili GR, Nematbakhsh M, Niazi AA, Jahantigh M, *et al.* Sex difference in gentamicin-induced nephrotoxicity: Influence of L-arginine in rat model. *Int J Prev Med* 2018;9:108.
- Safari T, Nematbakhsh M, Miri S, Ghofran O, Fereidooni F, Niazi AA, *et al.* Gender differences in response to Vitamin E and C in gentamicin induced nephrotoxicity in Wistar rats. *J Nephropathol* 2017;6:338-345.
- Saberi S, Dehghani A, Nematbakhsh M. Role of mas receptor in renal blood flow response to angiotensin-(1-7) in ovariectomized estradiol treated rats. *Res Pharm Sci* 2016;11:65-72.
- Xu P, Costa-Goncalves AC, Todiras M, Rabelo LA, Sampaio WO, Moura MM, *et al.* Endothelial dysfunction and elevated blood pressure in MAS gene-deleted mice. *Hypertension* 2008;51:574-80.
- Rabello Casali K, Ravizzoni Dartora D, Moura M, Bertagnolli M, Bader M, Haibara A, *et al.* Increased vascular sympathetic modulation in mice with mas receptor deficiency. *J Renin Angiotensin Aldosterone Syst* 2016;17:1-16.
- da Silveira KD, Pompermayer Bosco KS, Diniz LR, Carmona AK, Cassali GD, Bruna-Romero O, *et al.* ACE2-angiotensin-(1-7)-mas axis in renal ischaemia/reperfusion injury in rats. *Clin Sci (Lond)* 2010;119:385-94.
- Battle D, Wysocki J, Soler MJ, Ranganath K. Angiotensin-converting enzyme 2: Enhancing the degradation of angiotensin II as a potential therapy for diabetic nephropathy. *Kidney Int* 2012;81:520-8.
- Qi Y, Zhang J, Cole-Jeffrey CT, Shenoy V, Espejo A, Hanna M,

- et al.* Diminazene aceturate enhances angiotensin-converting enzyme 2 activity and attenuates ischemia-induced cardiac pathophysiology. *Hypertension* 2013;62:746-52.
22. Malek M, Nematbakhsh M. Renal ischemia/reperfusion injury; from pathophysiology to treatment. *J Renal Inj Prev* 2015;4:20-7.
 23. Dubey RK, Jackson EK. Estrogen-induced cardiorenal protection: Potential cellular, biochemical, and molecular mechanisms. *Am J Physiol Renal Physiol* 2001;280:F365-88.
 24. Li L, Ji H, Holloway C, Sandberg K, Ecelbarger C. Effects of 17 β -estradiol replacement in a model of renal ischemia in the ovariectomized female apolipoprotein E knockout mouse (1135.2). *FASEB J* 2014;28 Suppl 1:1135.2.
 25. Gross ML, Adamczak M, Rabe T, Harbi NA, Krttil J, Koch A, *et al.* Beneficial effects of estrogens on indices of renal damage in uninephrectomized SHRsp rats. *J Am Soc Nephrol* 2004;15:348-58.
 26. Mooradian AD. Antioxidant properties of steroids. *J Steroid Biochem Mol Biol* 1993;45:509-11.
 27. Takaoka M, Yuba M, Fujii T, Ohkita M, Matsumura Y. Oestrogen protects against ischaemic acute renal failure in rats by suppressing renal endothelin-1 overproduction. *Clin Sci (Lond)* 2002;103 Suppl 48:434S-7S.
 28. Saberi S, Dehghani A, Nematbakhsh M. Angiotensin 1-7 administration increases renal blood flow in the absence of bradykinin B2 receptor in ovariectomized estradiol treated rats: The role of mas receptor. *Acta Med Iran* 2019;57 (2):103-109.
 29. Higashi Y, Sanada M, Sasaki S, Nakagawa K, Goto C, Matsuura H, *et al.* Effect of estrogen replacement therapy on endothelial function in peripheral resistance arteries in normotensive and hypertensive postmenopausal women. *Hypertension* 2001;37:651-7.
 30. Lu W, Kang J, Hu K, Tang S, Zhou X, Yu S, *et al.* Angiotensin-(1-7) relieved renal injury induced by chronic intermittent hypoxia in rats by reducing inflammation, oxidative stress and fibrosis. *Braz J Med Biol Res* 2017;50:e5594.
 31. Fang F, Liu GC, Zhou X, Yang S, Reich HN, Williams V, *et al.* Loss of ACE2 exacerbates murine renal ischemia-reperfusion injury. *PLoS One* 2013;8:e71433.
 32. Nematbakhsh M, Safari T. Role of mas receptor in renal blood flow response to angiotensin (1-7) in male and female rats. *Gen Physiol Biophys* 2014;33:365-72.
 33. Armando I, Jezova M, Juorio AV, Terrón JA, Falcón-Neri A, Semino-Mora C, *et al.* Estrogen upregulates renal angiotensin II AT (2) receptors. *Am J Physiol Renal Physiol* 2002;283:F934-43.
 34. Silva-Antonialli MM, Tostes RC, Fernandes L, Fior-Chadi DR, Akamine EH, Carvalho MH, *et al.* A lower ratio of AT1/AT2 receptors of angiotensin II is found in female than in male spontaneously hypertensive rats. *Cardiovasc Res* 2004;62:587-93.
 35. Srisawat U, Kongrat S, Muanprasat C, Chatsudthipong V. Losartan and sodium nitroprusside effectively protect against renal impairments after ischemia and reperfusion in rats. *Biol Pharm Bull* 2015;38:753-62.