

## Diagnostic Performance of Ultrasonography in Detecting Fatty Liver Disease in Comparison with Fibroscan in People Suspected of Fatty Liver

### Abstract

**Background:** Fatty liver disease is a common hepatic disorder that remains undiagnosed due to the high number of asymptomatic patients and lack of a proper noninvasive diagnostic tool. Liver biopsy, the gold standard of liver steatosis diagnosis, is an invasive method that can be replaced by fibroscan. Fibroscan can detect liver steatosis with high sensitivity and specificity, but it is not accessible around the world. In this study, we compared ultrasonography (US) as a cheap and accessible device with fibroscan method in detecting patients with liver steatosis. **Materials and Methods:** We enrolled 77 patients in this study. US and fibroscan were done in each patient at a single day. Liver steatosis stages were recorded using US and fibroscan. The diagnostic performance of US was calculated, using fibroscan as the reference method. **Results:** The sensitivity and specificity of US in detecting fatty liver disease using fibroscan as a standard method were 73% and 69%, respectively. **Conclusion:** Based on sensitivity and specificity achieved from US, this study suggests that ultrasound is a suitable method for detecting patients with liver steatosis obviating liver biopsy and fibroscan.

**Keywords:** Diagnostic performance, fatty liver disease, fibroscan, ultrasonography

### Introduction

Fatty liver disease is the most common chronic liver dysfunction in the world with the prevalence of nearly 25%, with the highest prevalence in the Middle East and South America.<sup>[1]</sup> Nonalcoholic fatty liver disease (NAFLD) is the presence of fat accumulation in hepatocytes when no secondary cause like heavy alcohol consumption is present. It is seen in two types including NAFL and nonalcoholic steatohepatitis (NASH).<sup>[2]</sup> NASH is more common in patients with risk factors such as hyperlipidemia, diabetes mellitus, pregnancy, and long-term use of drugs. Fatty liver may progress to cirrhosis and fibrosis.<sup>[3]</sup> Most patients with NAFLD are asymptomatic, and the disease may be diagnosed incidentally by elevation of hepatic enzymes or accidental hepatic steatosis finding on imaging.<sup>[4]</sup> The gold standard diagnostic test of fatty liver disease is liver biopsy. Liver biopsy is an invasive procedure and cannot be used as a screening method because of its complications.<sup>[5]</sup> A potentially noninvasive method used as an alternative to liver biopsy for diagnosis

of fibrosis and hepatic steatosis is the measurement of liver stiffness using transient elastography with sensitivity of 83%, 88%, and 99% for a diagnosis of mild-to-moderate fibrosis, severe fibrosis, and cirrhosis, respectively.<sup>[6,7]</sup> However, it is not used extensively because of its inaccessibility.

Ultrasonography (US) is a cheap and an accessible method and is the most commonly used imaging method in diagnosis of NAFLD.<sup>[8]</sup> There are many studies on sensitivity and specificity of US in detecting NAFLD. In a meta-analysis of 49 studies from 1967 to 2010, the sensitivity and specificity of ultrasound were 84.8% and 93.6%, respectively.<sup>[9]</sup> However, there is no study comparing the ability of US with transient elastography in detecting fatty liver disease.

Because of high prevalence of fatty liver disease and a large number of undiagnosed patients, due to lack of an appropriate diagnostic method, we designed a study to investigate the sensitivity and specificity of US in detecting fatty liver disease in comparison with fibroscan (the elasticity

Leila Kamali,  
Atoosa Adibi,  
Shadi Ebrahimian,  
Fahime Jafari,  
Mohsen Sharifi<sup>1</sup>

Departments of Radiology and  
<sup>1</sup>Gastroenterologist, Isfahan  
University of Medical Sciences,  
Isfahan, Iran

*Address for correspondence:*  
Prof. Atoosa Adibi,  
Department of Radiology,  
Isfahan University of Medical  
Sciences, Isfahan, Iran.  
E-mail: [a\\_adibi@med.mui.ac.ir](mailto:a_adibi@med.mui.ac.ir)

#### Access this article online

Website: [www.advbiores.net](http://www.advbiores.net)

DOI: 10.4103/abr.abr\_114\_19

#### Quick Response Code:



**How to cite this article:** Kamali L, Adibi A, Ebrahimian S, Jafari F, Sharifi M. Diagnostic performance of ultrasonography in detecting fatty liver disease in comparison with fibroscan in people suspected of fatty liver. *Adv Biomed Res* 2019;8:69.

**Received:** 16 May 2019; **Revised:** 09 July 2019;  
**Accepted:** 21 July 2019; **Published:** 27 November 2019.

This is an open access journal, and articles are distributed under the terms of the Creative Commons Attribution-NonCommercial-ShareAlike 4.0 License, which allows others to remix, tweak, and build upon the work non-commercially, as long as appropriate credit is given and the new creations are licensed under the identical terms.

For reprints contact: [reprints@medknow.com](mailto:reprints@medknow.com)

imaging technique) and find the diagnostic performance of US using fibroscan as a standard method. The study aimed to detect whether the US can be used as an alternative to fibroscan and liver biopsy in diagnosis of fatty liver disease.

## Materials and Methods

It was a cross-sectional study done on 77 patients suspected of having fatty liver disease referred to Seyedolshohada Hospital, Isfahan, Iran, from October 2016 to 2017. The approval of the study was received from Isfahan University of Medical Sciences. The informed consent was signed by each patient, and the purpose of the study was explained to them. The demographic data including age and sex of the patients were recorded.

$$n = \frac{\left( Z_{1-\frac{\alpha}{2}} + Z_{1-\beta} \right)^2}{d^2} (p(1-p))$$

$$\alpha = 0.05 \rightarrow Z_{1-\frac{\alpha}{2}} = 1.96 \quad \%95$$

$$\beta = 0.02 \rightarrow Z_{1-\beta} = 0.84 \quad \%80$$

$$p = 0.84 \quad d = 0.12$$

$$N = \frac{(1.96 + 0.84)^2}{(0.12)^2} (0.84 \times 0.16) = \frac{1.054}{(0.12)^2}$$

$$N = 74$$

## Ultrasonography examination

Patients underwent US using a Samsung H60 device made in Korea, by a curvilinear multifrequency (3–5 MHz) probe. All ultrasounds were performed by one radiologist, and all fibroscans were performed by another radiologist who was blind about the ultrasound result.

The grading of steatosis by US was based on liver echogenicity: grade 0: “being normal;” Grade 1: mild steatosis “a slight increase in hepatic parenchymal echogenicity with normal visualization of diaphragm and intrahepatic vessel margin;” Grade 2: moderate steatosis “moderate increase of echogenicity and slightly impaired visualization of intrahepatic vessels and diaphragm;” and Grade 3: severe “a marked increase of echogenicity with poor or no visualization of intrahepatic vessel borders, diaphragm, and posterior portion of the right lobe of the liver.”<sup>[10]</sup> Different grades of liver steatosis are shown in Figure 1.

When judging ultrasound echogenicity, transmit power, gain, “time gain compensation” sliders, frequency, focal depth, and all other parameters were held constant to facilitate the comparison.

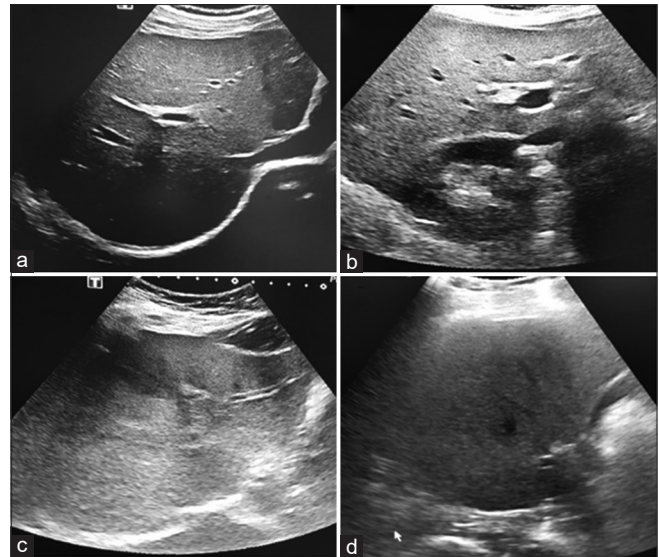


Figure 1: Ultrasonography in patients with different liver steatosis grades: (a) Grade 0, (b) Grade 1, (c) Grade 2, (d) Grade 3

## Fibroscan examination

The transient elastography was done by an expert radiologist blind to the liver ultrasonographic results with TOUCH502 Fiber Scanner, built in France, using M-probe.

Imaging was performed with the patient lying in the supine position with his right arm abducted and the forearm under the head. The right side of the body was bare to examine the liver and was slightly elevated.

The tip of the probe, covered with ultrasound gel, was placed on the intercostal space over the right liver lobe. The operator located a portion of the liver that was at least 6-cm thick and free of any large vascular structure, using A-mode images provided by fibroscan device. Then, the operator pressed the probe button for image acquisition. The measurement depth ranged from 25 to 45 mm.

Ten validated measurements were performed in each patient. The success rate was calculated by dividing the number of validated measurements by the total number of measurements. Procedures with 10 validated measurements and a success rate of at least 60% were considered reliable.<sup>[11]</sup>

The values of hepatic fibrosis using fibroscan measurement were expressed in kilopascal (kPa). To determine the amount of hepatic steatosis, the controlled attenuation parameter (CAP) test was used, and the results were reported in decibel/meter (dB/m). CAP cutoff values indicated liver steatosis and ranged from S0 indicating no steatosis (S) to S3 indicating severe steatosis. CAP values indicating  $S \geq 1$  ranged from 237.0 to 259.0 dB/m, from 259.0 to 291.0 dB/m for  $S \geq 2$ , and from 291.0 to 400.0 dB/m for  $S \geq 3$ .<sup>[12]</sup>

Cutoff values for fibrosis diagnosis were <5.5 for fibrosis stage F0 (no fibrosis), 5.5–8.0 for F1 (mild fibrosis),

8.0–10.0 for F2 (moderate fibrosis), 11.0–16.0 for F3 (severe fibrosis), and >16.0 for F4 (cirrhosis). F grading system is the output of fibroscan equipment by itself quantitatively by 0–4.

Measurement was reliable when the interquartile range (IQR) for liver stiffness measurement (LSM) was ≤30%. IQR more than 30% and LSM >7.1 Kpa were considered poorly reliable.<sup>[13]</sup>

Patients who did not have proper measurements were excluded from the study.

### Data analysis

Using fibroscan examinations and CAP values, patients were divided into two groups including patients with fatty liver disease (Grades 1, 2, and 3) and patients without fatty liver disease (Grade 0).

To analyze data, patients with stages F = 1, 2, or 3 were considered to have fibrotic liver. Moreover, those with F = 0 were classified as patients with normal liver.

Diagnostic performance of US in determining patients with fatty liver disease was evaluated using receiver operating characteristic (ROC) curve. Sensitivity, specificity, positive predictive value (PPV), and negative predictive value (NPV) were calculated in patients with and without hepatic fibrosis.

To analyze the differences between portal vein diameter in patients with fibrotic liver and nonfibrotic liver, Mann–Whitney U-test was used. All analyses were performed using SPSS version 24 for Windows (SPSS Inc., Chicago, IL, USA).

## Results

### Descriptive studies

In this study, 77 individuals including 54 males (70.1%) and 23 females (29.9%) who were suspected to have fatty liver disease were enrolled. US assessment revealed that 33 (42.9%), 19 (24.7%), 15 (19.5%), and 10 (13.0%) patients had fatty liver Grade 0, 1, 2, and 3, respectively. These frequencies were 29 (37.7%), 7 (9.1%), 16 (20.8%), and 25 (32.5%) for fatty liver assessment using fibroscan.

Fibrosis grading using fibroscan revealed that 29 (37.7%) individuals had normal liver parenchyma (F0) and 19 (24.7%), 10 (13.0%), 6 (7.8%), and 13 (16.9%) had stage F1, F2, F3, and F4, respectively.

These data are summarized in Tables 1-3.

In this study, fibroscan revealed fatty liver disease in 48 of 77 patients (62.3%). Of 48, 35 patients were detected to have fatty liver disease (72.9%) using US. Moreover, of 29 patients who had normal liver using fibroscan, 20 patients (68.9%) did not have fatty liver disease using US.

**Table 1: Prevalence of fatty liver diagnosis by ultrasonography and fibroscan**

Fatty liver	Fibroscan	
	Positive count	Negative count
Sono		
Positive	35	9
Negative	13	20

**Table 2: Comparison of fatty liver diagnosis by ultrasound and fibroscan in people with fibrosis and without fibrosis**

Fibroscan	Fatty liver	Fibro		Total
		Positive	Negative	
Negative	Sono			
	Positive	10	3	13
	Negative	5	11	16
	Total	15	14	29
Positive	Sono			
	Positive	25	6	31
	Negative	8	9	17
	Total	33	15	48
Total	Sono			
	Positive	35	9	44
	Negative	13	20	33
	Total	48	29	77

### Diagnostic accuracy of ultrasonography

The sensitivity, specificity, PPV, and NPV of US in detecting fatty liver disease was 73%, 69%, 80%, and 61%, respectively. Using ROC curve for detecting fatty liver disease, the area under the curve (AUC) (95% confidence interval [CI]) was 0/709 (0/587–0/832) ( $P < 0.01$ ).

In patients with liver fibrosis, the diagnostic performance of US in detecting fatty liver disease was 75% and 60% for sensitivity and specificity with PPV and NPV 80% and 52%, respectively. The AUC was 0.679 (90.0–509.849) with  $P < 0.05$ . Moreover, sensitivity, specificity, PPV, NPV, and AUC (95% CI) at ROC curve in patients without fibrosis were 66%, 78%, 76%, 68%, and 0.726 (0.536–0.916), respectively, with  $P < 0.05$ . We compared sonographic fatty liver with steatosis score in fibroscan and also we compared the presence of fibrosis in fibroscan in two groups of patients (fatty and nonfatty according to ultrasound).

No significant correlation was found between the degree of fatty liver disease and liver fibrosis stages. This finding suggested that patients with higher grades of fatty liver do not necessarily have higher degrees of liver fibrosis.

### The relation between fibrosis stages and portal vein diameter using ultrasonography and fibroscan

The mean ± standard deviation of portal vein diameter was  $9.87 \pm 1.74$  mm. Using the Mann–Whitney test, portal vein diameter in individuals with no fibrosis ( $9.35 \pm 1.25$  mm)

**Table 3: Comparison of fatty liver diagnosis by ultrasound and fibroscan and evaluation of sensitivity, specificity, positive predictive value, negative predictive value, ACC, area under the curve, and P value**

Fatty liver	Sensitivity	Specificity	PPV	NPV	ACC	AUC (95% CI)	P
Negative	0/667	0/786	0/769	0/687	0/724	0/726 (0/536-0/916)	0/038
Positive	0/757	0/600	0/806	0/529	0/708	0/679 (0/509-0/849)	0/049
Total	0/729	0/689	0/795	0/606	0/714	0/709 (0/587)	0/002

NPV: Negative predictive value, accuracy (ACC), PPV: Positive predictive value, CI: Confidence interval

was not significantly different from those who had hepatic fibrosis ( $10.19 \pm 1.93$  mm) ( $P = 0.335$  and  $P > 0.05$ , respectively).

## Discussion

The aim of this study was to determine the sensitivity and specificity of US in detecting fatty liver infiltration, using fibroscan as a reference method. We also evaluated the correlation between the degree of fibrosis with fatty liver disease and portal vein diameter.

The gold standard for the diagnosis of liver steatosis and fibrosis is liver biopsy.<sup>[14]</sup> This method is too invasive and has many complications.<sup>[15]</sup> Fibroscan is a new device which can replace liver biopsy.<sup>[16]</sup> Despite its advantages, it is an expensive and inaccessible device around the world, especially in Iran.

Previous studies showed that the diagnostic performance of transient elastography using CAP in detecting liver steatosis is very high with sensitivity and specificity of nearly 90%.<sup>[17]</sup> Furthermore, it was reported as a suitable method for screening hepatic steatosis because of its high NPV.<sup>[18]</sup> In this study, the sensitivity obtained for detecting hepatic steatosis was 73% showing that ultrasound can detect up to 73% of patients with fatty liver according to fibroscan reports. Based on the *P* value detected in this study, the US can be a good alternative for the fibroscan.

We also found that US can detect up to 76% and 67% of fatty liver diseases in patients with liver fibrosis and without liver fibrosis, respectively. The results suggest that US is a suitable method of diagnosis and follow-up of fatty liver disease, regardless of the liver fibrotic changes.

We also evaluated the relation between hepatic fibrosis and portal vein diameter and found that portal vein diameter was not significantly higher in those with hepatic fibrosis than those without signs of fibrosis. Our findings are not compatible with other studies reporting that fibroscan can predict portal hypertension using LSM. Furthermore, the chance of portal hypertension increases by an increase in liver fibrosis stages.<sup>[19,20]</sup>

No correlation was seen between liver steatosis and fibrosis staging in this study, and analysis showed that liver steatosis is not affected by liver fibrosis. The same results were detected in a study done by Asselah *et al.* on patients with chronic hepatitis C. They found no significant relationship between liver fibrosis and steatosis.<sup>[21]</sup> Contrary to the mentioned

results, some authors proposed the association between steatosis and fibrosis and suggested that controlling metabolic factor, overweight, and lifestyle can play an important role in managing hepatic fibrosis caused by hepatitis C virus.<sup>[22,23]</sup> Different results obtained may be due to different individual characteristics such as weight, body mass index, and type of underlying disease in studied populations.

Lack of histological data is the limitation of this study. Liver biopsy was not indicated in most of the participants in this study, and because of the invasive nature of liver biopsy, it was not done on the patients. Furthermore, the small number of individuals with severe hepatic steatosis and liver fibrosis was another limitation. Hence, further studies are needed to evaluate the diagnostic performance of US and to compare the hepatic fibrosis stages and steatosis grades obtained from US and fibroscan.

## Conclusion

According to the results of this study, US is an acceptable method in detecting fatty liver disease. In patients with liver fibrosis, the diagnostic performance of US in detecting fatty liver disease is acceptable also. No significant correlation was found between the degree of fatty liver disease and liver fibrosis stages.

## Acknowledgment

This project was the thesis of Leila Kamali (resident of radiology in Isfahan University of Medical Sciences).

## Financial support and sponsorship

Nil.

## Conflicts of interest

There are no conflicts of interest.

## References

1. Younossi ZM, Koenig AB, Abdelatif D, Fazel Y, Henry L, Wymer M, *et al.* Global epidemiology of nonalcoholic fatty liver disease-meta-analytic assessment of prevalence, incidence, and outcomes. *Hepatology* 2016;64:73-84.
2. Contos MJ, Sanyal AJ. The clinicopathologic spectrum and management of nonalcoholic fatty liver disease. *Adv Anat Pathol* 2002;9:37-51.
3. Rashid M, Roberts EA. Nonalcoholic steatohepatitis in children. *J Pediatr Gastroenterol Nutr* 2000;30:48-53.
4. Newton JL. Systemic symptoms in non-alcoholic fatty liver disease. *Dig Dis* 2010;28:214-9.
5. Afdhal NH. Biopsy or biomarkers: Is there a gold standard for

- diagnosis of liver fibrosis? *Clin Chem* 2004;50:1299-300.
6. de Lédinghen V, Vergniol J. Transient elastography (FibroScan). *Gastroenterol Clin Biol* 2008;32:58-67.
  7. Yoneda M, Yoneda M, Fujita K, Inamori M, Tamano M, Hiriishi H, *et al.* Transient elastography in patients with non-alcoholic fatty liver disease (NAFLD). *Gut* 2007;56:1330-1.
  8. Gomercić M, Duvnjak M, Barsić N. Ultrasonography in the diagnosis of nonalcoholic fatty liver disease. *Acta Med Croatica* 2009;63:1-3.
  9. Hernaez R, Lazo M, Bonekamp S, Kamel I, Brancati FL, Guallar E, *et al.* Diagnostic accuracy and reliability of ultrasonography for the detection of fatty liver: A meta-analysis. *Hepatology* 2011;54:1082-90.
  10. Rumack CM, Levine D. *Diagnostic Ultrasound E-Book*. Philadelphia, PA: Elsevier Health Sciences; 2018.
  11. Sandrin L, Fourquet B, Hasquenoph JM, Yon S, Fournier C, Mal F, *et al.* Transient elastography: A new noninvasive method for assessment of hepatic fibrosis. *Ultrasound Med Biol* 2003;29:1705-13.
  12. Mikolasevic I, Orlic L, Franjic N, Hauser G, Stimac D, Milic S, *et al.* Transient elastography (FibroScan®) with controlled attenuation parameter in the assessment of liver steatosis and fibrosis in patients with nonalcoholic fatty liver disease where do we stand? *World J Gastroenterol* 2016;22:7236-51.
  13. Roulot D, Czernichow S, Le Clésiau H, Costes JL, Vergnaud AC, Beaugrand M, *et al.* Liver stiffness values in apparently healthy subjects: Influence of gender and metabolic syndrome. *J Hepatol* 2008;48:606-13.
  14. Sebastiani G, Halfon P, Castera L, Pol S, Thomas DL, Mangia A, *et al.* SAFE biopsy: A validated method for large-scale staging of liver fibrosis in chronic hepatitis C. *Hepatology* 2009;49:1821-7.
  15. Seeff LB, Everson GT, Morgan TR, Curto TM, Lee WM, Ghany MG, *et al.* Complication rate of percutaneous liver biopsies among persons with advanced chronic liver disease in the HALT-C trial. *Clin Gastroenterol Hepatol* 2010;8:877-83.
  16. Roulot D, Costes JL, Buyck JF, Warzocha U, Gambier N, Czernichow S, *et al.* Transient elastography as a screening tool for liver fibrosis and cirrhosis in a community-based population aged over 45 years. *Gut* 2011;60:977-84.
  17. Mi YQ, Shi QY, Xu L, Shi RF, Liu YG, Li P, *et al.* Controlled attenuation parameter for noninvasive assessment of hepatic steatosis using fibroscan®: Validation in chronic hepatitis B. *Dig Dis Sci* 2015;60:243-51.
  18. Sasso M, Tengher-Barna I, Ziol M, Miette V, Fournier C, Sandrin L, *et al.* Novel controlled attenuation parameter for noninvasive assessment of steatosis using fibroscan®: Validation in chronic hepatitis C. *J Viral Hepat* 2012;19:244-53.
  19. Vizzutti F, Arena U, Romanelli RG, Rega L, Foschi M, Colagrande S, *et al.* Liver stiffness measurement predicts severe portal hypertension in patients with HCV-related cirrhosis. *Hepatology* 2007;45:1290-7.
  20. Lemoine M, Katsahian S, Ziol M, Nahon P, Ganne-Carrie N, Kazemi F, *et al.* Liver stiffness measurement as a predictive tool of clinically significant portal hypertension in patients with compensated hepatitis C virus or alcohol-related cirrhosis. *Aliment Pharmacol Ther* 2008;28:1102-10.
  21. Asselah T, Boyer N, Guimont MC, Cazals-Hatem D, Tubach F, Nahon K, *et al.* Liver fibrosis is not associated with steatosis but with necroinflammation in French patients with chronic hepatitis C. *Gut* 2003;52:1638-43.
  22. Leandro G, Mangia A, Hui J, Fabris P, Rubbia-Brandt L, Collredo G, *et al.* Relationship between steatosis, inflammation, and fibrosis in chronic hepatitis C: A meta-analysis of individual patient data. *Gastroenterology* 2006;130:1636-42.
  23. Hourigan LF, Macdonald GA, Purdie D, Whitehall VH, Shorthouse C, Clouston A, *et al.* Fibrosis in chronic hepatitis C correlates significantly with body mass index and steatosis. *Hepatology* 1999;29:1215-9.