

Effects of *Cyperus rotundus* Extract on Spatial Memory Impairment and Neuronal Differentiation in Rat Model of Alzheimer's Disease

Abstract

Background: Alzheimer's disease (AD) is one of the most common neurodegenerative diseases in the older population and characterized by progressive memory and cognitive impairment. *Cyperus rotundus*, a traditional medicinal herb, has analgesic, sedative, and anti-inflammatory effects and also used to increase memory in Islamic traditional medicine. This study was designed to consider the effects of *C. rotundus* extract on memory impairment and neurogenesis in the Beta-Amyloid rats' model. **Materials and Methods:** Forty-two male Wistar rats were randomly divided into six groups ($n = 7$) for the evaluation of baseline training performance in the Morris water maze test. Then, amyloid-beta ($A\beta_{1-42}$) was injected in animal hippocampal CA1 bilaterally in four groups. The first probe trial was performed 21 days after $A\beta$ injection. Then, 250, 500, and 750 mg/kg of *C. rotundus* extract were administered to three $A\beta$ -injected groups for 1 month; after that, the second probe trial was performed, and rats were sacrificed after 28 days of the second probe trial. The neurogenesis was detected in the hippocampus, by immunohistochemical staining. **Results:** This study showed that spatial memory increased in the behavioral test in AD treated group with *C. rotundus* extract, compared with the AD group ($P = 0.02$). Immunohistochemical staining revealed that neuronal differentiation has been occurred in the hippocampus in the AD-treated group with *C. rotundus* extract compared with the AD group ($P = 0.01$). **Conclusions:** This study showed that *C. rotundus* extract, repaired spatial memory impairment in the $A\beta$ rats, through increased neurogenesis in the hippocampus, which could be related to the flavonoid components in the extract.

Keywords: *Cyperus rotundus*, neuronal differentiation, spatial memory

Zeinab Shakerin,
Ebrahim Esfandiari,
Shahnaz Razavi,
Hojjatallah
Alaei¹, Mustafa
Ghanadian²,
Gholamreza Dashti

From the Departments of
Anatomical Sciences and
Physiological Sciences, Isfahan
University of Medical Sciences,
²Department of Pharmacognosy,
Faculty of Pharmacy, Isfahan
University of Medical Sciences,
Isfahan, Iran

Introduction

Alzheimer's disease (AD) is the most popular form of dementia in elderly people, affecting more than 30 million people in the world since it was discovered.^[1] This disease is a progressive neurodegenerative disorder^[2] and has become a main medical and social problem in developing countries.^[3] The major neuropathological features of AD are extracellular deposition of amyloid-beta ($A\beta$) plaque, intracellular formation of neurofibrillary tangles,^[4] degeneration, and loss of neurons and synaptic dysfunction in the hippocampus and brain cortex.^[5]

It was reported that the administration of $A\beta$ causes long-term potentiation to be changed in the hippocampus, which leads to impairment of cognitive function and memory loss in rodents.^[6] Deposition of

$A\beta$ leads to oxidative stress, formation of reactive oxygen species (ROS), reduction in activity of antioxidant enzymes, and consequently neuronal death.

It was shown that neurogenesis is remarkably decreased during aging in the rodent brain.^[7] Furthermore, most studies using transgenic animal models of AD reported a reduction in hippocampal neurogenesis.^[8] This reduction has an important role during the onset and progression of the disease. The formation of toxic $A\beta$ peptides associated with a decrease in neurogenesis.^[9] However, some other works on transgenic animals have reported that amyloid deposition increases neurogenesis.^[10] However, the most general view in the field is that AD associated with

Address for correspondence:
Dr. Ebrahim Esfandiari,
Department of Anatomical
Sciences, Isfahan University of
Medical Sciences, Isfahan, Iran.
E-mail: Esfandiari@med.mui.ac.ir

This is an open access journal, and articles are distributed under the terms of the Creative Commons Attribution-NonCommercial-ShareAlike 4.0 License, which allows others to remix, tweak, and build upon the work non-commercially, as long as appropriate credit is given and the new creations are licensed under the identical terms.

For reprints contact: WKHLRPMedknow_reprints@wolterskluwer.com

How to cite this article: Shakerin Z, Esfandiari E, Razavi S, Alaei H, Ghanadian M, Dashti G. Effects of *Cyperus rotundus* extract on spatial memory impairment and neuronal differentiation in rat model of Alzheimer's disease. *Adv Biomed Res* 2020;9:17.

Received: 10 August 2019;
Revised: 04 September 2019;
Accepted: 26 February 2020;
Published: 22 April 2020

Access this article online

Website: www.advbiores.net

DOI: 10.4103/abr.abr_173_19

Quick Response Code:



a decrease in hippocampal neurogenesis and consequence impairment of cognitive function.^[11]

Evidence suggests that consuming external antioxidants can improve brain damages and related cognitive performance.^[12] Several therapeutic strategies have been developed to treat AD, including anti-inflammatory, anti-oxidant, and anti-amyloid approaches. Recently, herbal treatments have been tested in animals^[13] and cellular^[14] models of AD and clinical trials with AD subjects.^[15]

Cyperus rotundus, a sedge of the *Cyperaceae* family, is used widely in traditional medicine as nervine tonic, sedative, antispasmodic, antimalarial, and to relieve diarrhea.^[16] *C. rotundus* rhizome extracts revealed the presence of β -sitosterol, cyperene, cyperol, flavonoids, sesquiterpenoids, ascorbic acid, and polyphenols.^[17] Several studies have reported that flavonoids may cause to modulate the immune cell functions, against inflammation, and stress oxidative.^[18]

Lots of evidence showed that dietary flavonoids have significant neuroprotective effects such as neurogenesis and neuronal regeneration that lead to improve learning and memory performance.^[19-22]

The purpose of this study is to consider and assess the therapeutic effects of *C. rotundus* rhizome extract on memory impairment and neurogenesis in the hippocampus in the A β rats' model.

Materials and Methods

Herbal extract preparation

Fresh rhizomes of *C. rotundus* (10 kg) were prepared from Iraq. The rhizomes were confirmed by Dr. Ghanadian, Pharmacognosy Department, Isfahan University of Medical Sciences, Iran, according to the voucher specimen number 2262 deposited there and was shade, dried, and powdered. After sieving, ethanol was added and the mixture was poured into a percolator. After 3 days, the extract was discharged with a flow rate of 4 mL/min from the bottom tap through cotton wool. The obtained extract was vaporized by a rotary vacuum evaporator (Büchi-Labortechnik, Germany) at 45°C and 10 mbar. After that, the extract was suspended in a mixture of water (1000 mL) and chloroform (500 mL), and then the chloroform and aqueous parts were detached. The chloroform part rich in oil, fat, and nonpolar compounds. The defatted aqueous part was filtered, and evaporated under reduced pressure and stored at 4°C until use.

Extract standardization through measurement of total flavonoid compounds

A volume of 100 μ L of the extract was poured into the tested tube (three replications were performed). After that, 100 μ L AlCl₃ 20% solution and 50 μ L of acetic acid glacial were added to each tested tube, and finally, methanol was

added up to 3 mL. They were left, then, at room temperature for 40 min and absorbance was read at 415 nm.

Animals

Forty-two male Wistar rats weighing 230–250 g were obtained from Isfahan University of Medical Sciences and housed in a 12-h light-dark cycle (22°C–24°C) with food and water available *ad libitum*. The Ethics Committee for Animal experiments (IR. MUI. REC.393476, revised 1985) at Isfahan University of Medical Sciences approved the study and all experiments were conducted with the international guiding principles for animals. Animals were randomly divided into six groups ($n = 7$) for baseline training performance measurement in Morris test,^[23] after which, animals were grouped as:

Control: Without any surgery and treatment

Sham: operated group, received 5 μ L normal saline into CA1 bilaterally and administered 1 mL distill water orally for 30 days after the surgery.

AD: received 5 μ g/ μ L A β 1-42 into CA1 bilaterally, and 1 mL distilled water orally for 30 days after the surgery.

AD+CR (250, 500, and 750 mg/kg) groups, received 5 μ g/ μ L A β 1-42 into CA1 bilaterally, and oral administration of extract in three different doses of 250, 500, and 750 mg/kg for 30 days after the surgery. The protocol of the experimental design is summarized in Figure 1.

Morris water maze test

Spatial learning and memory were evaluated through Morris test modified for use in rats.^[24] This test was run in a circular pool (diameter, 183 cm; height, 60 cm), was filled with water (22°C \pm 1°C). This pool was separated into four quadrants of North West, North East, South West, and South East (SE). An invisible platform (diameter, 10 cm) was located 2 cm below the water surface in the SE quadrant (target quadrant). There was a video camera at 1.4 m above the center of the pool, which recorded the swimming trials. Rats were trained for four trials per day (with an intertrial interval of 5 min). The training was performed for 4 days. During each trial, rats were placed in a different quadrant of the pool and allowed to find the platform within 60 s. All rats were allowed to spend 30 s on the platform for training. When rats failed to find the platform within the set time, they were conducted to the platform. In the probe trial, the platform was removed, and the rats were allowed to swim for 60 s. The average time rats spent in the target quadrant for searching the platform was recorded to measure spatial memory ability with Neurovision 1.1 software. (Tajhizgostar Iranian, Iran)

Stereotaxic surgery

Rat A β 1-42 (Sigma, St. Louis, MO, USA) was solubilized in sterile normal saline (0.9%), at a concentration of 1 μ g/ μ L, and were stored at –20°C until use. Before surgery, the A β

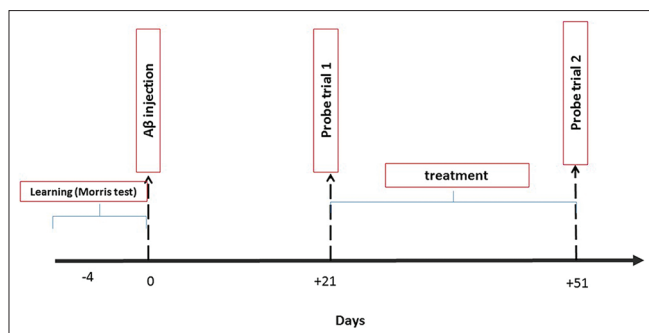


Figure 1: Diagram of the experimental timeline during the study

solution was incubated at 37°C for 5 days.^[25,26] Rats were anesthetized with chloral hydrate (350 mg/kg) and placed in a stereotaxic device (Stoelting, Kiel, WI, USA). The scalp was incised in the midline, and the area surrounding bregma was cleaned and dried. Two small holes were drilled into the skull above the CA1. The A β (5 μ g/5 μ l) was injected using microinjection and 10 Hamilton syringe in CA1 region bilaterally (anterior-posterior = -3.36 mm, medial-lateral = \pm 1.6 mm from the bregma and dorsal-ventral = 3.2 mm from top of the skull according to Paxinos atlas [Figure 2]).^[27]

After injection, the needle was kept in CA1 for 5 min to allow complete diffusion of the drug. Sham group, was received normal saline. After surgery, each animal was allowed to recover for 5–7 days. Moreover, the histological evaluation was run to assess the correct injected area. Twenty-one days after surgery, the first probe trial of Morris test was run for finding memory impairment.^[23]

Treatment

After the first probe trial of the Morris test, *C. rotundus* was solubilized in distilled water and administered orally at 250, 500, and 750 mg/kg/day doses for 30 days. The sham and AD groups received only distilled water.

For selection safe doses, acute toxicity and LD₅₀ study were done. The extract was found to be nontoxic up to 1000 mg/kg and in the limited dose of 5000 mg/kg. It showed that LD₅₀ was >5000 mg/kg. Therefore, according to experience in our laboratory and similar studies, 5%, 10%, and 15% lethal doses equal to 250, 500, and 750 mg/kg were selected for the main study.

Histological study

Twenty-eight days after probe trial 2, all rats were sacrificed transcardially with 4% paraformaldehyde. The brain tissue including the hippocampus was removed and postfixed in the same fixative solution overnight at 4°C. After that, the hippocampus was separated, dehydrated with an ascending ethanol series, cleared with xylene, and embedded in paraffin for 3–6 h and then blocked. For histological studies, a series of coronal serial sections with 3- μ m thickness and 500 μ m intervals were prepared from the hippocampus by a rotary

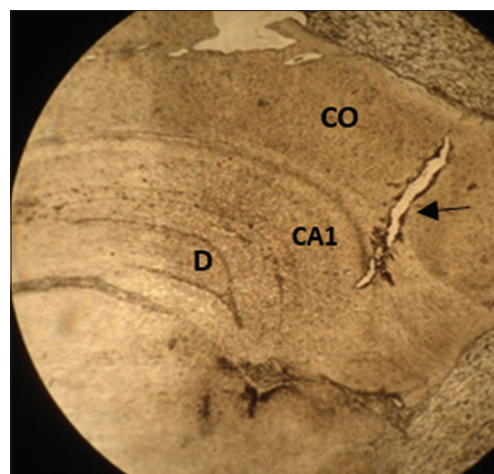


Figure 2: Coronal photomicrograph of lateral microinjection site in the CA1 area. Arrow: Needle path, CO: Cortex, D: Dentate gyrus (\times = 25)

microtome (Leica, Vienna, Austria). After deparaffinization, the sections were incubated in 2XSSC formamide (for DNA denaturation), were rinsed with 2XSSC 10 min, incubated in H₂O₂ and methanol for 20 min, incubated with 2N HCl for 30 min, rinsed in 0.1 M boric acid, pH 8.5, and washed in TBS. Then, the sections were incubated with TBS 3% goat serum and 0.3% Triton X (TBS++) and incubated overnight at 4°C for staining with a primary antibody, mouse anti-neuron-specific nuclear protein (NeuN) (UK) Catalog No. MAB377 [2:200]. The next day, the sections were rinsed with TBS and incubated with a secondary antibody, goat anti-mouse Alexa Fluor 488 (catalog No. A-11001 (green; 2:150)) for 1 h and washed with TBS. Nuclear counterstaining was performed with 4',6'-diamidino-2-phenylindole dihydrochloride hydrate (Sigma) for 3 min. The sections were considered with a fluorescence microscope and photographed digitally (Zeiss, Germany).^[23]

Statistical analysis

All data were expressed as mean \pm standard error of the mean and analyzed in SPSS 24 software (Chicago: SPSS Inc. IBM Corp.). The one-way ANOVA *post hoc* Least significant difference and Kruskal–Wallis test were run for a one-way comparison. For observing frequencies in alternative times, the generalized linear models (GLM) tests were conducted. The statistical significance in all run tests is $P < 0.05$.

Results

Result of measurement of total flavonoid compounds

The calibration curve was plotted by linear regression in the concentration of 0.13, 0.66, 3.33, and 16.66 μ g/mL. The regression equation was expressed as: $Y = 0.0709x - 0.0086$. y-axis shows absorption and x-axis shows flavonoid concentration in sample (μ g/mL) with the correlation factor of $r^2 = 0.999$. The mean percentage of flavonoid in total extract is 0.17% \pm 0.02% quercetin equivalent in dry weight [Figure 3].

Effect of *Cyperus rotundus* extract on memory

The GLM test showed no significant difference in the mean of traveled distance for finding invisible platform in all animal groups during 4 days spatial acquisition phase before the surgery ($P = 0.81$), but this statistical analysis indicated significant differences in traveled distance between days 1 and 4 in all groups ($P < 0.001$), revealing that the improvement of learning performance in all groups. The Kruskal–Wallis showed no significant difference between the measured groups on the first day ($P = 0.6$), second day ($P = 0.18$), third day ($P = 0.61$), and the last day ($P = 0.19$) [Figure 4].

The LSD analysis of probe trial showed a significant difference in the mean percentage of time in probe1 between all groups ($P = 0.003$) as: control with AD ($P = 0.004$), control with AD + CR 250 ($P = 0.004$), control with AD + CR 500 ($P = 0.003$), and control with AD + CR 750 ($P = 0.004$). Furthermore, the statistical analysis showed a significant difference in the mean percentage of time in probe1 between sham with AD ($P = 0.01$), sham with AD + CR 250 ($P = 0.01$), sham with AD + CR500 ($P = 0.008$), and sham with AD + CR 750 ($P = 0.009$).

In second probe trial (probe2) that was done after treatment, statistical analysis indicated a significant increase in the mean percentage of spending time in target quadrant among six groups ($P = 0.02$) as: AD with control ($P = 0.008$), AD with sham ($P = 0.01$), AD with AD + CR 500 ($P = 0.004$), AD with AD 250 ($P = 0.4$), and AD with AD 750 ($P = 0.06$) and also significant difference between AD + CR 250 with AD + CR 500 groups ($P = 0.03$) [Figure 5].

Effect of *Cyperus rotundus* extract on neuron-specific nuclear protein expression

The Kruskal–Wallis analysis for assessing NeuN-positive cells in dentate gyrus indicated that there existed significant differences between six groups ($P = 0.01$). These significant differences existed among the AD + CR500 group with AD and AD + CR250 groups and also among control groups with AD and AD + CR250 groups ($P < 0.05$) [Figure 6].

Discussion

The propose of this experimental study was the evaluation of the neuroprotective effect of *C. rotundus* on memory impairment in A β -injected rats. Aggregation and deposition of A β in the hippocampus and brain lead to an increase in acetylcholinesterase activity, induction of oxidative stress, inflammation, and impairment of learning and memory.^[28]

A β accumulation is toxic to neurons and inhibits neuronal differentiation and also causes neuroinflammation in the brain.^[9] Neuroinflammation leads to suppression of neurogenesis in the hippocampus.^[29] Furthermore, A β causes oxidative stress and an increase of ROS activity. ROS activity stimulates cell death and leads to alteration

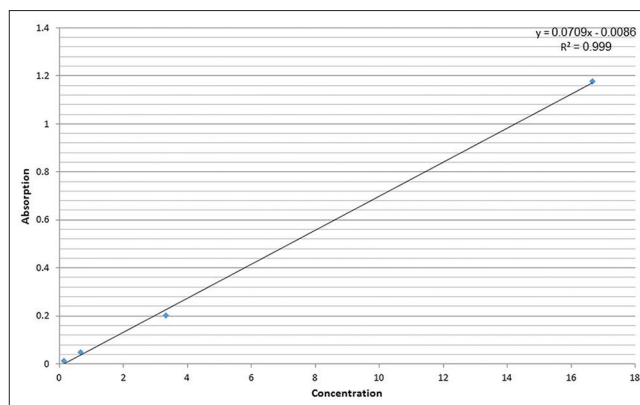


Figure 3: Calibration curve of total flavonoid for *Cyperus rotundus* extract

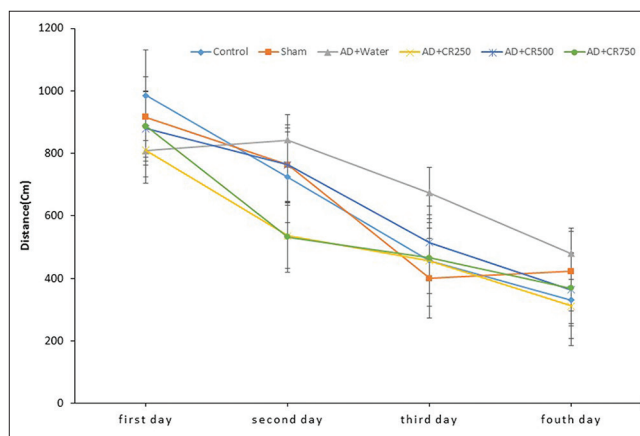


Figure 4: Travelled distance for finding platform in Morris test in experimental groups in four training days before surgery

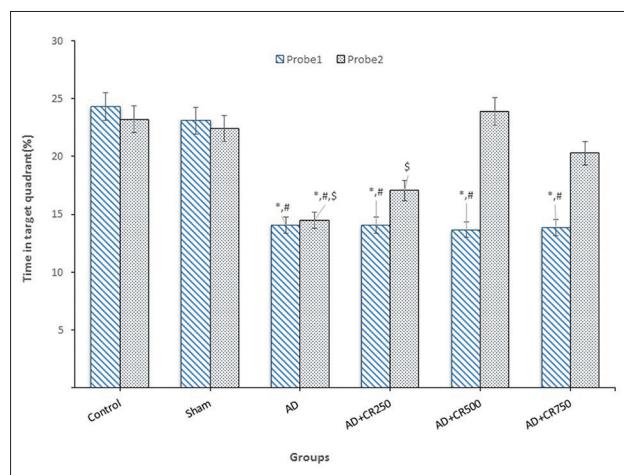


Figure 5: Probe 1 and probe 2. Blue bar shows animal swimming in the target quadrant 21 days after amyloid-beta injection. Gray bar shows animal swimming in target quadrant after treatment. *Significant difference with the control group, #Significant difference with the sham group, \$Significant difference with AD + CR500 group ($P < 0.05$)

in adult neurogenesis. In oxidative stress conditions, deficiency of antioxidant enzymes like SOD induces a reduction in the production of new neurons in the SGZ of the hippocampal dentate gyrus.^[30]

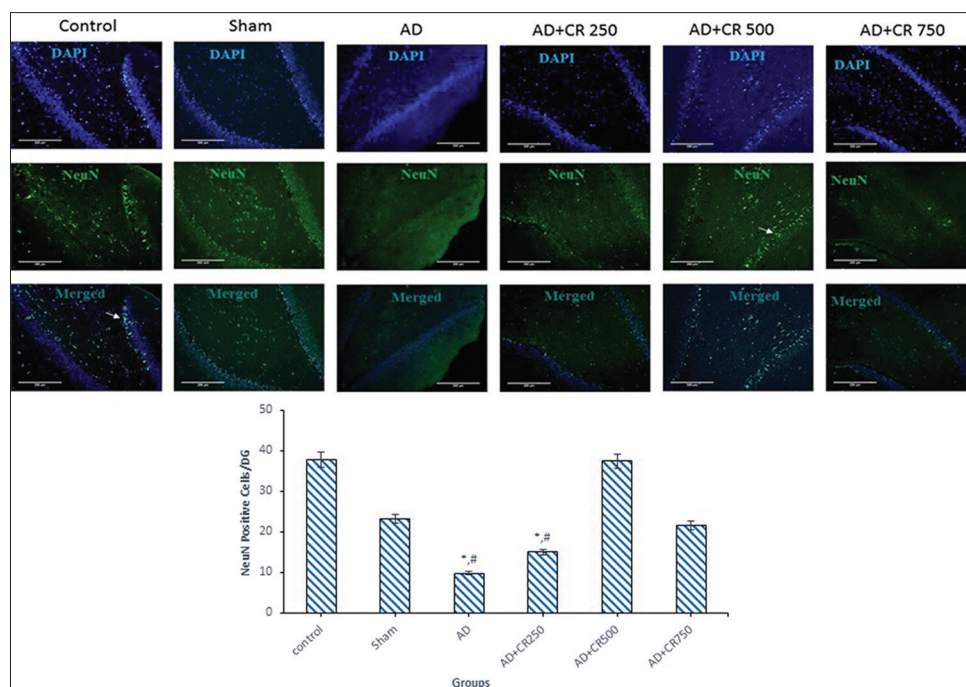


Figure 6: Immunofluorescence staining for neuron-specific nuclear protein in experimental groups, arrow new differentiated neurons ($\times 200$). *Significant difference with the Alzheimer's disease + CR500 group, #Significant difference with control group ($P < 0.05$)

In a previous study, it was reported that $A\beta$ plaque aggregate in synaptic spaces, 21 days after $A\beta$ injection into the hippocampus.^[23] Therefore, in this study, memory impairment was detected in the first probe trial, by decreasing in mean percentage of time spent in the target quadrant between AD groups with control and sham groups. *C. rotundus* is a traditional medicinal herb that has anti-inflammatory and antioxidant effects.

Mehdizadeh *et al.* showed the protective effect of *C. rotundus* on memory impairment in $A\beta$ injected rat only in the behavioral test.^[31] Our finding in Morris test was confirmed with this study. Ardestani *et al.* showed decrease oxidative damage, antioxidant, and metal chelating effects of *C. rotundus*.^[32] Antioxidant and lipid peroxidation effects of this plant also were considered during *in vitro* studies.^[32] Dang *et al.* investigated the anti-inflammatory effect of this plant in animal models.^[33] There were not many studies about the effect of *C. rotundus* on neurogenesis. Therefore in this study, we considered the effect of this plant on the loss of memory impairment through increasing neurogenesis by expression of NeuN. The generation of new neurons is the main property of the adult brain that was occurred in the hippocampus and subventricular zone.^[34]

NeuN is localized in nuclei and perinuclear cytoplasm of the neurons in the central nervous system of mammals that marks post-mitotic and mature neurons.^[35] Monoclonal antibodies to the NeuN protein have been actively used in the immunohistochemical staining of neuronal differentiation to evaluate the functional status of neurons in normal and pathological states for more than 20 years.

This protein has not been detected in glial cells and tissues other than nervous, which suggests it is a specific neuronal marker.^[36]

Behavioral studies indicated that the hippocampus plays a critical role in learning and memory and hippocampal neurogenesis play an important role in the memory performance.^[37] In this study, dose 500 mg/kg *C. rotundus* significantly increased neurogenesis and consequently increased the percentage of time spent in the target quadrant in the Morris test.

According to the anti-inflammatory and anti-oxidant effects of this plant in the previous studies, *C. rotundus* extract may be through the reduction of neuroinflammation and oxidative stress lead to increase of neurogenesis.

Aggregation and deposition of $A\beta$ in the brain lead to a degeneration process in neurons, which interfere with the electrolyte barrier function of the nerve cell membrane, which ultimately causes brain edema and inflammation. The treatment with *C. rotundus* extract may through $A\beta$ depletion from the brain tissue causing a regeneration process in which neurons refine their normal function during 4 weeks and this leads to brain recovery from edema and inflammation. Meanwhile, this treatment will stimulate neurogenesis, which had been stopped as a result of the toxic effect of deposition of $A\beta$ in the brain, especially in the hippocampus, later on.

The analysis of *C. rotundus* extract revealed the presence of flavonoid compound in this extract. Flavonoid compounds represent different biological activities through interaction

with specific signaling pathways^[38] and also cause increased neurotrophins such as Brain Derive Neurotrophic Factors^[39] and Nerve Growth Factors.^[40] Expression of these factors stimulates the production of new neurons in the brain.^[41] Lee *et al.* investigated the neuroprotective role of *C. rotundus* in an *in vitro* model of Parkinsonism.^[42] Sunil *et al.* demonstrated total oligomeric flavonoids of *C. rotundus* extract have neuroprotective effects against the ischemic-reperfusion-induced neurodegeneration in rats.^[43] The present study showed useful effects of *C. rotundus* extract on neurogenesis and behavioral disturbance in Alzheimer rats model.

Conclusions

This experimental study showed that *C. rotundus* extract, repaired spatial memory impairment in A β rat model, through increased neurogenesis in the hippocampus. This effect most probably is related to the flavonoid components in the extract.

Financial support and sponsorship

Nil.

Conflicts of interest

There are no conflicts of interest.

References

1. Brookmeyer R, Corrada MM, Curriero FC, Kawas C. Survival following a diagnosis of Alzheimer disease. *Arch Neurol* 2002;59:1764-7.
2. Bignante EA, Heredia F, Morfini G, Lorenzo A. Amyloid β precursor protein as a molecular target for amyloid β – Induced neuronal degeneration in Alzheimer's disease. *Neurobiol Aging* 2013;34:2525-37.
3. Ishrat T, Hoda MN, Khan MB, Yousuf S, Ahmad M, Khan MM, *et al.* Amelioration of cognitive deficits and neurodegeneration by curcumin in rat model of sporadic dementia of Alzheimer's type (SDAT). *Eur Neuropsychopharmacol* 2009;19:636-47.
4. Moreira PI, Carvalho C, Zhu X, Smith MA, Perry G. Mitochondrial dysfunction is a trigger of Alzheimer's disease pathophysiology. *Biochim Biophys Acta* 2010;1802:2-10.
5. Arendt T. Synaptic degeneration in Alzheimer's disease. *Acta Neuropathol* 2009;118:167-79.
6. Shankar GM, Li S, Mehta TH, Garcia-Munoz A, Shepardson NE, Smith I, *et al.* Amyloid-beta protein dimers isolated directly from Alzheimer's brains impair synaptic plasticity and memory. *Nat Med* 2008;14:837-42.
7. Hollands C, Bartolotti N, Lazarov O. Alzheimer's disease and hippocampal adult neurogenesis; exploring shared mechanisms. *Front Neurosci* 2016;10:178.
8. Mu Y, Gage FH. Adult hippocampal neurogenesis and its role in Alzheimer's disease. *Mol Neurodegener* 2011;6:85.
9. Haughey NJ, Nath A, Chan SL, Borchard AC, Rao MS, Mattson MP. Disruption of neurogenesis by amyloid beta-peptide, and perturbed neural progenitor cell homeostasis, in models of Alzheimer's disease. *J Neurochem* 2002;83:1509-24.
10. Yu Y, He J, Zhang Y, Luo H, Zhu S, Yang Y, *et al.* Increased hippocampal neurogenesis in the progressive stage of Alzheimer's disease phenotype in an APP/PS1 double transgenic mouse model. *Hippocampus* 2009;19:1247-53.
11. Martinez-Canabal A. Reconsidering hippocampal neurogenesis in Alzheimer's disease. *Front Neurosci* 2014;8:147.
12. Khodamoradi N, Komaki A, Salehi I, Shahidi S, Sarihi A. Effect of Vitamin E on lead exposure-induced learning and memory impairment in rats. *Physiol Behav* 2015;144:90-4.
13. Chu S, Gu J, Feng L, Liu J, Zhang M, Jia X, *et al.* Ginsenoside Rg5 improves cognitive dysfunction and beta-amyloid deposition in STZ-induced memory impaired rats via attenuating neuroinflammatory responses. *Int Immunopharmacol* 2014;19:317-26.
14. Limpeanchob N, Jaipan S, Rattanakaruna S, Phrompittayarat W, Ingkaninan K. Neuroprotective effect of *Bacopa monnieri* on beta-amyloid-induced cell death in primary cortical culture. *J Ethnopharmacol* 2008;120:112-7.
15. Esfandiary E, Abdolali Z, Omranifard V, Ghanadian M, Bagherian-Sararoud R, Karimipour M, *et al.* Novel effects of *Rosa damascena* extract on patients with neurocognitive disorder and depression: A clinical trial study. *Int J Prev Med* 2018;9:57.
16. Meena A, Yadav A, Niranjana U, Singh B, Nagariya A, Verma M. Review on *Cyperus rotundus*-A potential herb. *Int J Pharm Clin Res* 2010;2:20-2.
17. Sonwa MM, König WA. Chemical study of the essential oil of *Cyperus rotundus*. *Phytochemistry* 2001;58:799-810.
18. Dhillon R, Singh S, Kundra S, Basra A. Studies on the chemical composition and biological activity of essential oil from *Cyperus rotundus* Linn. *Plant Growth Regul* 1993;13:89-93.
19. Keli SO, Hertog MG, Feskens EJ, Kromhout D. Dietary flavonoids, antioxidant vitamins, and incidence of stroke: The Zutphen study. *Arch Intern Med* 1996;156:637-42.
20. Lee Y, Jeon SJ, Lee HE, Jung IH, Jo YW, Lee S, *et al.* Spinosin, a C-glycoside flavonoid, enhances cognitive performance and adult hippocampal neurogenesis in mice. *Pharmacol Biochem Behav* 2016;145:9-16.
21. Yoo DY, Choi JH, Kim W, Nam SM, Jung HY, Kim JH, *et al.* Effects of luteolin on spatial memory, cell proliferation, and neuroblast differentiation in the hippocampal dentate gyrus in a scopolamine-induced amnesia model. *Neurol Res* 2013;35:813-20.
22. Sawamoto A, Okuyama S, Yamamoto K, Amakura Y, Yoshimura M, Nakajima M, *et al.* 3,5,6,7,8,3',4'-Heptamethoxyflavone, a citrus flavonoid, ameliorates corticosterone-induced depression-like behavior and restores brain-derived neurotrophic factor expression, neurogenesis, and neuroplasticity in the hippocampus. *Molecules* 2016;21:541.
23. Esfandiary E, Karimipour M, Mardani M, Alaei H, Ghanadian M, Kazemi M, *et al.* Novel effects of *Rosa damascena* extract on memory and neurogenesis in a rat model of Alzheimer's disease. *J Neurosci Res* 2014;92:517-30.
24. Rabiei Z, Hojjati M, Rafieian-Kopaeia M, Alibabaei Z. Effect of *Cyperus rotundus* tubers ethanolic extract on learning and memory in animal model of Alzheimer. *Biomed Aging Pathol* 2013;3:185-91.
25. Geng Y, Li C, Liu J, Xing G, Zhou L, Dong M, *et al.* Beta-asarone improves cognitive function by suppressing neuronal apoptosis in the beta-amyloid hippocampus injection rats. *Biol Pharm Bull* 2010;33:836-43.
26. Hajipour S, Sarkaki A, Farbood Y, Eidi A, Mortazavi P, Valizadeh Z. Effect of gallic acid on dementia type of alzheimer disease in rats: Electrophysiological and histological studies. *Basic Clin Neurosci* 2016;7:97-106.
27. George P, Charles W. The Rat Brain In Stereotaxic Coordinates.

- 6th ed. Elsevier Science: Spiral-bound; 2007.
28. Jhoo JH, Kim HC, Nabeshima T, Yamada K, Shin EJ, Jhoo WK, *et al.* Beta-amyloid (1-42)-induced learning and memory deficits in mice: Involvement of oxidative burdens in the hippocampus and cerebral cortex. *Behav Brain Res* 2004;155:185-96.
 29. Deng W, Aimone JB, Gage FH. New neurons and new memories: How does adult hippocampal neurogenesis affect learning and memory? *Nat Rev Neurosci* 2010;11:339-50.
 30. Taupin P. A dual activity of ROS and oxidative stress on adult neurogenesis and Alzheimer's disease. *Cent Nerv Syst Agents Med Chem* 2010;10:16-21.
 31. Mehdizadeh M, Hashem Dabaghian F, Shojaee A, Molavi N, Taslimi Z, Shabani R, *et al.* Protective effects of *Cyperus rotundus* extract on amyloid β -peptide (1-40)-induced memory impairment in male rats: A behavioral study. *Basic Clin Neurosci* 2017;8:249-54.
 32. Ardestani A, Yazdanparast R. *Cyperus rotundus* suppresses AGE formation and protein oxidation in a model of fructose-mediated protein glycoxidation. *Int J Biol Macromol* 2007;41:572-8.
 33. Dang GK, Parekar RR, Kamat SK, Scindia AM, Rege NN. Antiinflammatory activity of *Phyllanthus emblica*, *Plumbago zeylanica* and *Cyperus rotundus* in acute models of inflammation. *Phytother Res* 2011;25:904-8.
 34. Ehninger D, Kempermann G. Neurogenesis in the adult hippocampus. *Cell Tissue Res* 2008;331:243-50.
 35. Mullen RJ, Buck CR, Smith AM. NeuN, a neuronal specific nuclear protein in vertebrates. *Development* 1992;116:201-11.
 36. Gusel'nikova VV, Korzhhevskiy DE. NeuN as a neuronal nuclear antigen and neuron differentiation marker. *Acta Naturae* 2015;7:42-7.
 37. Caroni P, Donato F, Muller D. Structural plasticity upon learning: Regulation and functions. *Nat Rev Neurosci* 2012;13:478-90.
 38. Kilani-Jaziri S, Neffati A, Limem I, Boubaker J, Skandrani I, Sghair MB, *et al.* Relationship correlation of antioxidant and antiproliferative capacity of *Cyperus rotundus* products towards K562 erythroleukemia cells. *Chem Biol Interact* 2009;181:85-94.
 39. Rendeiro C, Vauzour D, Rattray M, Waffo-Tégou P, Mérillon JM, Butler LT, *et al.* Dietary levels of pure flavonoids improve spatial memory performance and increase hippocampal brain-derived neurotrophic factor. *PLoS One* 2013;8:e63535.
 40. Ola MS, Aleisa AM, Al-Rejaie SS, Abuohashish HM, Parmar MY, Alhomida AS, *et al.* Flavonoid, morin inhibits oxidative stress, inflammation and enhances neurotrophic support in the brain of streptozotocin-induced diabetic rats. *Neurol Sci* 2014;35:1003-8.
 41. Spencer JP, Vauzour D, Rendeiro C. Flavonoids and cognition: The molecular mechanisms underlying their behavioural effects. *Arch Biochem Biophys* 2009;492:1-9.
 42. Lee CH, Hwang DS, Kim HG, Oh H, Park H, Cho JH, *et al.* Protective effect of *Cyperus rotundus* rhizoma against 6-hydroxydopamine-induced neuronal damage. *J Med Food* 2010;13:564-71.
 43. Sunil AG, Kesavanarayanan KS, Kalaivani P, Sathiyaa S, Ranju V, Priya RJ, *et al.* Total oligomeric flavonoids of *Cyperus rotundus* ameliorates neurological deficits, excitotoxicity and behavioral alterations induced by cerebral ischemic-reperfusion injury in rats. *Brain Res Bull* 2011;84:394-405.