

## A Modified Approach for Single-Port Laparoscopic Repair of Inguinal Hernias in Children

### Abstract

**Background:** Although traditional open groin incision repair has been used routinely for decades, the benefit of the minimally invasive surgery has challenged the traditional open method. Nowadays, laparoscopic herniorrhaphy has evolved to making it more minimally invasive from 3 to 2 and now single port and from intracorporeal to extracorporeal knotting. This study aimed to evaluate a new modification of single port laparoscopic herniorrhaphy in children with congenital inguinal hernia. **Materials and Methods:** In this single-institution randomized case-control study 190 children who suffered from congenital inguinal hernia were divided into two groups randomly: Group 1 ( $N = 73$ ) undergone a single-port modified extracorporeal purse-string sutures (laparoscopic surgery [LS]) and Group 2 ( $N = 117$ ) undergone open surgery (OS). **Results:** The mean age of the patients at operation time was  $28.79 \pm 11.45$  months. Overall, three patients (1.57%) had intraoperative retroperitoneal hemorrhage. The duration of anesthesia and operation for those undergoing bilateral operation were significantly shorter in LS group. There was no statistically significant difference in individual postoperative complication rates between the groups. The proportion of overall post-operative complications was 4 (5.4%) in LS and 13 (11.1%) in OS group ( $P = 0.18$ ). Proportion of trapped cryptorchidism was significantly higher in the OS group. **Conclusion:** In conclusion for children with inguinal hernia, we had found the benefits of single-port modified extracorporeal purse-string for reduction the operative time, trapped testes and better cosmetics and parents' satisfaction.

**Keywords:** *Hernia, hernia repair, laparoscopy, sutureless surgical procedures*

### Introduction

Congenital inguinal hernia is the most prevalent inguinal-scrotal disorders in neonates and children that occurs because of failure of closure of processus vaginalis.<sup>[1]</sup> Although traditional open groin incision repair with dissecting the hernia sac from the spermatic cord and suture ligating of its base has been used routinely for decades, during recent years, the benefit of the minimally invasive surgery to decrease access trauma and operative time and ability to assess the contralateral side has challenged the traditional open method.<sup>[2-5]</sup> However, current trends in pediatric hospitals continue to favor the use of open technique, especially so, in developing countries with limited access to tertiary facilities and low-volume hospitals for inguinal hernia. Laparoscopic approach in inguinal herniorrhaphy in children is the method of choice, because it has lower risks for testicular atrophy, surgical site infection

(SSI), secondary undescended testis (UDT) and bladder damage. Laparoscopic approach also provides the possibility of exploration of the contralateral inguinal canal and furthermore therapeutic actions.<sup>[6]</sup>

Nowadays, with improvement in diagnostic and technical methods in surgical and anesthetic practices, laparoscopic herniorrhaphy has evolved to make it more minimally invasive from 3 to 2 and now single port and from intracorporeal to extracorporeal knotting. In a meta-analysis conducted by Lo *et al.*<sup>[7]</sup> which has compared the results of multi-port and single-port laparoscopic hernia repair techniques, it was shown that in unilateral hernias, the average duration of surgery in single-port method is greater than multi-port, although in bilateral hernias there was no difference.

The first report of single-port technique was introduced by Ozgediz *et al.*<sup>[8]</sup> in 2005 and in 2013 Kumar and Ramakrishnan.<sup>[9]</sup> was used this technique without the use of Tuohy

Ali Fazeli,  
Heidar Ali Davari<sup>1</sup>,  
Mehrdad  
Hosseinpour

*Department of General Surgery, Imam Hossein Children Hospital, Isfahan University of Medical Sciences, <sup>1</sup>Department of General Surgery, Al Zahra Hospital, Isfahan University of Medical Sciences, Isfahan, Iran*

**Address for correspondence:**  
Dr. Mehrdad Hosseinpour,  
Department of General Surgery,  
Imam Hossein Children  
Hospital, Isfahan University of  
Medical Sciences, Isfahan, Iran.  
E-mail: meh\_hosseinpour@  
yahoo.com

**Received:** 13 April 2020  
**Revised:** 20 June 2020  
**Accepted:** 12 July 2020  
**Published:** 30 October 2020

#### Access this article online

**Website:** www.advbiores.net

**DOI:** 10.4103/abr.abr\_80\_20

#### Quick Response Code:



**How to cite this article:** Fazeli A, Davari HA, Hosseinpour M. A modified approach for single-port laparoscopic repair of inguinal hernias in children. *Adv Biomed Res* 2020;9:63.

This is an open access journal, and articles are distributed under the terms of the Creative Commons Attribution-NonCommercial-ShareAlike 4.0 License, which allows others to remix, tweak, and build upon the work non-commercially, as long as appropriate credit is given and the new creations are licensed under the identical terms.

For reprints contact: WKHLRPMedknow\_reprints@wolterskluwer.com

needle, however, the major limitations of these techniques are difficulty or inability to curve the needle to encircle the large hernia sacs.

Therefore, we conducted a single-institution, randomized, case-control study to evaluate a new modification of single-port laparoscopic herniorraphy in children with congenital inguinal hernia undergoing hernia repair.

## Materials and Methods

This is a prospective case-control study, carried out in the department of pediatric surgery, Isfahan University of Medical Sciences (IUMS), from July 2017 to 2018. After obtaining the approval of the Ethical research committee of IUMS and obtaining of written consent from all parents of patients, we prospectively included children (aged between 3 months and 10 years of age) with symptomatic congenital inguinal hernia that referred to our center for operation. Patients with past history of connective tissue disorders, ascites, age <9 months, previous abdominal surgery, emergency admissions and patients with noncongenital hernia were excluded. Patient eligibility included the age between 3 months and 10 years, an elective hernia repair and parental consent.

One hundred and ninety patients who suffered from congenital inguinal hernia were divided into two groups randomly using a random-number table sequence. Opaque sequentially numbered sealed envelopes were used to allocate: Group 1 ( $N = 73$ ) undergone single-port laparoscopic surgery (LS) and Group 2 ( $N = 117$ ) undergone open surgery (OS).

In order to evaluate the satisfaction level of the patients in both study groups, a questionnaire form was given to the parents. The results were obtained based on a number between 0 and 5 chosen by the parents with a description written beside the number. 0 was described as “bad,” 1 as “Moderate,” 2 as “Good,” 3 as “Very good,” 4 as “Excellent” and 5 was described as “Very Excellent.”

## Technique

The preferred method in laparoscopic herniorraphy in children is extracorporeal method. In this method, the ligation of inguinal canal's internal ring is approached extraperitoneally. Intracorporeal method is not used in children.<sup>[10]</sup>

## Laparoscopic surgery group

Under general anesthesia and intubation, in Trendelenburg's position, a 5 mm port was introduced exactly through the umbilicus by open method. Pneumoperitoneum was created and pressure kept between 10 and 12 mm of Hg. A 5 mm, 30° laparoscope was introduced through the umbilical port to view the patent processus vaginalis (PPV) bilaterally.

After localizing the internal ring with a 26 G needle, a 2 mm stab incision was made on the skin. Then a large bore lumbo peritoneal shunt needle was introduced through the one corner of stab incision and encircled the half of the

peritoneum of the neck of inguinal sac after skipping over the spermatic cord and the vas coalescence and introduced into the abdominal cavity. Second, large bore needle was introduced through the opposite side of stab incision to encircle opposite half of the hernia sac and introduced in to the abdominal cavity. A percutaneous endoscopic gastrostomy (PEG) wire which is a catheter with a circular head introduced through one of the needles [Figure 1], and a needleless 3-0 polydioxanone (PDS) suture was introduced through the other needle and pass through the circle of PEG wire [Figure 2a]. By pulling out of wire through the first needle the end of the PDS string was brought out of the stab incision [Figure 2b]. Then needles were removed and the suture knotted extracorporeally [Figure 3].

## Open surgery group

Open herniotomy was performed using a skin low crease incision. High ligation of the sac was performed using 3-0 PDS suture. The distal sac was slit to prevent postoperative hydrocele formation.

The database included the patient's age, sex, body weight, and preoperative laterality. Primary end point data collected included the SSI, bleeding, peritonitis or peritoneal abscess, postoperative ileus, respiratory complications, size of scar, postoperative hydrocele, occult patent process vaginalis (PPV), postoperative pain, improvement of hernia symptoms recurrence of hernia, vas-deferens (Visual Analog Scale) injury, bladder injury, intestinal injury, umbilical hernia, and iatrogenic UDT.

To measure the severity of pain of the patient, if possible, the child scored her/his pain from zero to ten according to the Wong baker's criterion.<sup>[11]</sup>

The assessment of the symptoms in patients was performed by senior author of the study (A.F) daily during hospitalization and then every 3 months in the follow-up clinic. Recurrence was defined as reoperation on the preoperative symptomatic side.

Wound infections were diagnosed according to the following criteria:

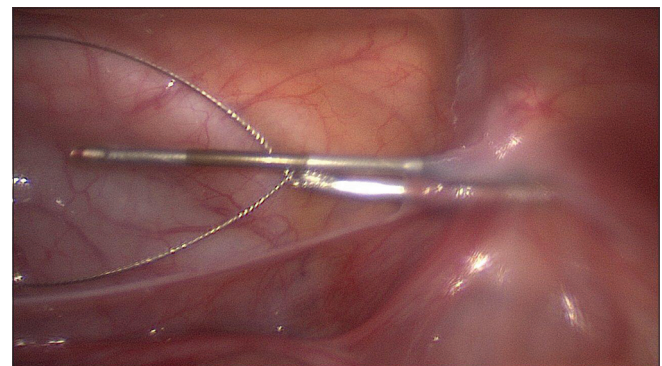
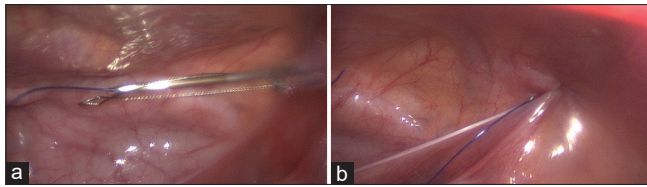


Figure 1: Introduction of percutaneous endoscopic gastrostomy wire through one of the needles



**Figure 2:** (a) Introduction of needleless 3-0 polydioxanone suture through the other needle to pass through the circle of percutaneous endoscopic gastrostomy wire (b) Pulling out of wire through the first needle to bring out of 3-0 polydioxanone suture from stab incision

1. Infection occurs within 30 days of the surgery<sup>[12]</sup>
2. Infection involves only the skin and subcutaneous tissue
3. At least one of the following is present:
  - a. Purulent discharge from a superficial infection
  - b. Organisms isolated from aseptically obtained wound culture.
4. At least one of the following signs of infection is present:
  - a. Pain or tenderness
  - b. Localized swelling
  - c. Redness or heat.

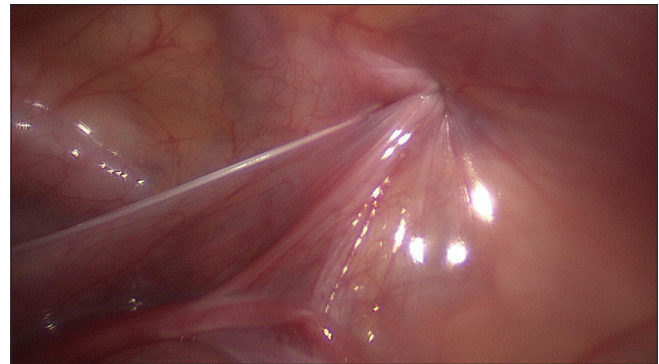
The secondary end points of the study were hospital length of stay (LOS), parents or patient satisfaction, and umbilical hernia at the site of port insertion.

Patients were followed to 6 months. In cases, the patients did show for the follow-up visits, we called to remind them of coming to the clinic. The Statistical Package for the Social Sciences (SPSS 22, Chicago, IL, USA) software was used for the data analysis. Mean  $\pm$  standard deviation (SD) was used to express the quantitative data. Frequency and percentage were used to express qualitative data. Categorical variables were compared by the Chi-square and Fisher's exact test. Variables were not normally distributed. The Mann-Whitney was used to determine any differences in the mean scores of groups. Data were expressed as mean  $\pm$  SD  $P$  value  $<0.05$  was considered significant. Based on the preliminary study results,  $\alpha = 0.05$  and  $1-\beta = 0.80$ , sample size was sufficient.

## Results

In this study, a total of 190 infants with 245 hernia defects were enrolled as two groups: Group 1 (LS) including 73 patients with 95 hernia defects and Group 2 (OS) including 117 patients with 150 hernia defects. One hundred and forty-three (75.2%) patients were male and 47 (24.7%) were female. The mean age of patients at operation time was  $28.79 \pm 11.45$  months. Seventy-five (39.4%) patients had right inguinal hernia, 60 (31.5%) patients had left inguinal hernia and in 55 (28.95) cases, it was bilaterally. The mean LOS was  $1.3 \pm 0.2$  days. Baseline demographics did not differ between the groups [Table 1].

Table 2 shows intraoperative variables in groups. Overall, 3 patients (1.57%) had intraoperative retroperitoneal



**Figure 3:** Knotting of the suture extracorporeally to close the ring

variables	LS	OS	<i>P</i>
<i>n</i> (%)	73 (38.4)	117 (61.6)	
Sex, <i>n</i> (%)			
Male	56 (76.7)	87 (74.4)	0.715
Female	17 (23.3)	30 (25.6)	
Age (months)	28.77 $\pm$ 11.23	28.80 $\pm$ 11.20	0.980
Body weight preoperative laterality, <i>n</i> (%)			
Right	31 (42.5)	44 (37.6)	0.612
Left	20 (27.4)	40 (34.2)	
Bilateral	22 (30.1)	33 (28.2)	
Length of stay	1.4 $\pm$ 0.35	1.2 $\pm$ 0.12	0.81

LS: Laparoscopic surgery, OS: Open surgery

hemorrhage which managed by observation. The duration of anesthesia and operation for those undergoing bilateral operation were significantly shorter in LS group. Five (6.84%) patients in LS group had umbilical hernia at the site of port insertion. Pain control starts immediately after the surgery and continues for 24 h. There was no statistically significant difference in individual postoperative complication rates between the groups [Table 3]. The proportion of overall postoperative complications was 4 (5.4%) in LS and 11 (11.1%) in OS group ( $P = 0.18$ ). There was no significant difference between the LS groups ( $4.5 \pm 1.3$ ) and OS group ( $4.3 \pm 1.1$ ) ( $P = 0.2$ ) in occurrence of chronic pain. However, the proportion of trapped cryptorchidism was significantly higher in the OS group. We have no peritonitis or peritoneal abscess, postoperative ileus and respiratory complications in our patients. Size of scar was  $4.6 \pm 0.2$  mm in LS and  $24.3 \pm 3.2$  mm in OS group ( $P = 0.0001$ ). Mann-Whitney test showed higher rate of parents' satisfaction in LS group as compared with OS [Table 4].

## Discussion

Although OS is a conventional accepted method as the first choice treatment for inguinal hernia of children, its inherent problems such as access trauma due to dissection of the vas and vessels, large groin incision and inability to assess the contralateral side<sup>[13]</sup> make the LS as an attractive alternative



**Table 2: Comparison of intraoperative variables in groups**

variables	LS	OS	P
Injury to VAS and vessels	0	0	-
Injury to intestine	0	0	-
Bleeding (hematoma)	2 (2.7)	1 (0.8)	0.4
Conversion to open surgery	0	Nil	
PPV	14 (19.1)	Nil	
Duration of anesthesia			
Unilateral operation (min)	45.1.3±10.3	42.3±12.4	0.1
Bilateral operation (min)	51.2±15.7	63.8±14.4	<0.0001
Operative time			
Unilateral operation (min)	16.2±4.3	16.8±2.9	0.2
Bilateral operation (min)	22.4± 5.8	32.8±7.4	<0.0001

LS: Laparoscopic surgery, OS: Open surgery, PPV: Patent process vaginalis, VAS: Visual Analog Scale

**Table 3: Comparison of postoperative variables in groups**

variables	LS (%)	OS (%)	P
Hydrocele	2 (2.7)	1 (0.85)	0.31
Recurrence	2 (2.7)	2 (1.7)	0.6
Trapped UDT	0	8 (6.8)	0.02
SSI	0	0	-

LS: Laparoscopic surgery, OS: Open surgery, SSI: surgical site infection, UDT: undescended testis

**Table 4: Comparison of postoperative satisfaction in groups**

variables	LS (%)	OS (%)	P
Very excellent	1 (1.4)	3 (2.6)	0.001
Excellent	20 (27.4)	9 (7.7)	
Very good	31 (42.5)	34 (29.1)	
Good	11 (15.1)	54 (46.2)	
Moderate	10 (13.7)	13 (11.1)	
Bad	0 (0.0)	4 (3.4)	

LS: Laparoscopic surgery, OS: Open surgery

method for repairing inguinal hernia in children. On the other hand, there are several cohort studies, randomized controlled trials and meta-analysis studies established the benefits of LS for ability to assess the contralateral side and cosmetic results.<sup>[14-17]</sup>

As highlighted by Fujiogi *et al.*,<sup>[18]</sup> there are conflicting results regarding postoperative complications, operative time postoperative pain, and recurrence following LS and OS.

While traditionally laparoscopic herniorrhaphy involves three separate skin incisions for ports, advancing technology has made single site laparoscopic herniorrhaphy possible. The first report of single-port technique was introduced by Ozgediz *et al.*<sup>[8]</sup> in 2005. In 2013, Kumar and Ramakrishnan.<sup>[9]</sup> were used this technique without the use of Tuohy needle; however, the major limitations of these techniques are difficulty or inability to curve the

needle to encircle the large hernia sacs. Limited studies in the utilization of single-port LS (SPLS) for inguinal hernia prevents one from drawing conclusions about the benefit of this technique in children. Although few pilot studies on SPLS benefits in inguinal hernia in children have been published,<sup>[19-22]</sup> but for obtaining a powered multi-center study, we need more pilot studies in children.

The present study was designed to report a modified single-port laparoscopic approach for pediatric inguinal hernia repair using PEG guidewire technique and its clinical outcomes. We selected PEG guidewire to (i) its retractable circular head and (ii) the availability of PEG guidewire.

One of the aims of SPLS in hernia would be reduce the anesthesia and operative time. Our results showed that SPLS was associates with a reduction in duration of anesthesia in bilateral operation; however, in unilateral hernia, there were no significant differences in anesthesia duration. In Fujiogi *et al.*'s study,<sup>[18]</sup> the duration of anesthesia was more in unilateral hernia in comparison of OS. It seems that by reducing the number of port insertion in SPLS, we can reduce the operating and anesthetic time and this may be one of the most important benefits of SPLS in children. The median reported time for 3 port technique was around 20 min.<sup>[23]</sup> In other study, od SPLS of inguinal hernia in children was 13–15 min for unilateral hernia and 20–25 min for bilateral hernia.<sup>[24]</sup>

The second finding of this study shows the proportion of 19.1% for occult PPV. This is another significant advantage of LS in hernia. The reported rates of occult PPV are 23%–37%<sup>[8,25]</sup> which is compatible with the finding of the present study, but in some studies<sup>[11]</sup> in evaluation of older children it was reduced, because up to 40% of PPV are closed by 2 months and 60% by 2 years of age.

In this study, we have eight cases of postoperative trapped cryptorchidism in which the testis was trapped in scar tissue above the dependent scrotum. These patients need re-operation surgery for orchidopexy.

In all the meta-analysis, difference in recurrence was insignificant between LS and OS,<sup>[15]</sup> which is compatible with our results. The reported recurrence rat for open herniotomy, 3 port laparoscopy, and SPLS was 2%–6%, 0%–5%, and 0%–4%, respectively, in children.<sup>[20,21,18]</sup>

Our results must be interpreted with caution, given the relatively small number of study participants. Moreover, we did not include postoperative testicular atrophy in our series, because it need longer follow-up; however, to limit this possible bias, we will rechecked the patients on regular basis in future.

In conclusion, for children with inguinal hernia who scheduled for operation, we had found the benefits of single-port laparoscopy for reduction the operative time, trapped testes and better cosmetics, and parents satisfaction.

However a multi-center study is needed to more definitely determine this technique for children with inguinal hernia.

### Acknowledgment

We should thank Miss. Poor jam for her cooperation in data collection. We also thank the vice chancellery of Isfahan university of Medical Sciences for cooperation in study designing.

### Financial support and sponsorship

Nil.

### Conflicts of interest

There are no conflicts of interest.

### References

- Poenaru D. Inguinal hernias and hydroceles in infancy and childhood: A consensus statement of the Canadian association of paediatric surgeons. *Paediatr Child Health* 2000;5:461-2.
- Takehara H, Yakabe S, Kameoka K. Laparoscopic percutaneous extraperitoneal closure for inguinal hernia in children: Clinical outcome of 972 repairs done in 3 pediatric surgical institutions. *J Pediatr Surg* 2006;41:1999-2003.
- Miyake H, Fukumoto K, Yamoto M, Nouso H, Kaneshiro M, Nakajima H, *et al.* Comparison of percutaneous extraperitoneal closure (LPEC) and open repair for pediatric inguinal hernia: Experience of a single institution with over 1000 cases. *Surg Endosc* 2016;30:1466-72.
- Saka R, Okuyama H, Sasaki T, Nose S, Yoneyama C. Safety and efficacy of laparoscopic percutaneous extraperitoneal closure for inguinal hernias and hydroceles in children: A comparison with traditional open repair. *J Laparoendosc Adv Surg Tech A* 2014;24:55-8.
- Koivusalo AI, Korpela R, Wirtavuori K, Piiparinen S, Rintala RJ, Pakarinen MP. A single-blinded, randomized comparison of laparoscopic versus open hernia repair in children. *Pediatrics* 2009;123:332-7.
- Geiger S, Bobylev A, Schädelin S, Mayr J, Holland-Cunz S, Zimmermann P. Single-center, retrospective study of the outcome of laparoscopic inguinal herniorrhaphy in children. *Medicine (Baltimore)* 2017;96:e9486.
- Lo CW, Yang SS, Tsai YC, Hsieh CH, Chang SJ. Comparison of laparoendoscopic single-site versus conventional multiple-port laparoscopic herniorrhaphy: A systemic review and meta-analysis. *Hernia* 2016;20:21-32.
- Ozgediz D, Roayaie K, Lee H, Nobuhara KK, Farmer DL, Bratton B, *et al.* Subcutaneous endoscopically assisted ligation (SEAL) of the internal ring for repair of inguinal hernias in children: Report of a new technique and early results. *Surg Endosc* 2007;21:1327-31.
- Kumar A, Ramakrishnan TS. Single port laparoscopic repair of paediatric inguinal hernias: Our experience at a secondary care centre. *J Minim Access Surg* 2013;9:7-12.
- Badia JM, Casey AL, Petrosillo N, Hudson PM, Mitchell SA, Crosby C. Impact of surgical site infection on healthcare costs and patient outcomes: A systematic review in six European countries. *J Hosp Infect* 2017;96:1-5.
- Garra G, Singer AJ, Taira BR, Chohan J, Cardoz H, Chisena E, *et al.* Validation of the Wong-Baker FACES pain rating scale in pediatric emergency department patients. *Acad Emerg Med* 2010;17:50-4.
- Liu Z, Dumville JC, Norman G, Westby MJ, Blazeby J, McFarlane E, *et al.* Intraoperative interventions for preventing surgical site infection: An overview of cochrane reviews. *Cochrane Database Syst Rev* 2018;2:CD012653.
- Harrison MR, Lee H, Albanese CT, Farmer DL. Subcutaneous endoscopically assisted ligation (SEAL) of the internal ring for repair of inguinal hernias in children: A novel technique. *J Pediatr Surg* 2005;40:1177-80.
- Alzahem A. Laparoscopic versus open inguinal herniotomy in infants and children: A meta-analysis. *Pediatr Surg Int* 2011;27:605-12.
- Yang C, Zhang H, Pu J, Mei H, Zheng L, Tong Q. Laparoscopic vs. open herniorrhaphy in the management of pediatric inguinal hernia: A systemic review and meta-analysis. *J Pediatr Surg* 2011;46:1824-34.
- Feng S, Zhao L, Liao Z, Chen X. Open versus laparoscopic inguinal herniotomy in children: A systematic review and meta-analysis focusing on postoperative complications. *Surg Laparosc Endosc Percutan Tech* 2015;25:275-80.
- Esposito C, St Peter SD, Escolino M, Juang D, Settimi A, Holcomb GW 3<sup>rd</sup>. Laparoscopic versus open inguinal hernia repair in pediatric patients: A systematic review. *J Laparoendosc Adv Surg Tech A* 2014;24:811-8.
- Fujiogi M, Michihata N, Matsui H, Fushimi K, Yasunaga H, Fujishiro J. Outcomes following laparoscopic versus open surgery for pediatric inguinal hernia repair: Analysis using a national inpatient database in Japan. *J Pediatr Surg* 2019;54:577-81.
- Chang YT, Wang JY, Lee JY, Chiou CS, Hsieh JS. One-trocar laparoscopic transperitoneal closure of inguinal hernia in children. *World J Surg* 2008;32:2459-63.
- Shalaby RY, Fawy M, Soliman SM, Dorgham A. A new simplified technique for needlescopic inguinal herniorrhaphy in children. *J Pediatr Surg* 2006;41:863-7.
- Chang YT, Lee JY, Tsai CJ, Chiu WC, Chiou CS. Preliminary experience of one-trocar laparoscopic herniorrhaphy in infants and children. *J Laparoendosc Adv Surg Tech A* 2011;21:277-82.
- Li S, Tang ST, Aubdoollah TH, Li S, Li K, Tong QS, *et al.* A modified approach for inguinal hernias in children: hybrid single-incision laparoscopic intraperitoneal ligation. *J Laparoendosc Adv Surg Tech A* 2015;25:689-93.
- Schier F, Montupet P, Esposito C. Laparoscopic inguinal herniorrhaphy in children: A three-centre experience with 933 repairs. *J PediatrSurg* 2002;37:395-7.
- Bharathi RS, Dabas AK, Arora M, Baskaran V. Laparoscopic ligation of internal ring-three ports versus single-port technique: Are working ports necessary? *J Laparoendosc Adv Surg Tech A* 2008;18:891-4.
- Wulkan ML, Wiener ES, VanBalun N, Vescio P. Laparoscopy through the open ipsilateral sac to evaluate presence of contralateral hernia. *J Pediatr Surg* 1996;31:1174-6.