

Inflammatory Pseudotumor: A 20-Year Single Institutional Experience

Abstract

Background: Inflammatory pseudotumor (IPT) is a relatively rare benign disease. The aim of the study was to demonstrate the demographic distribution, clinical presentation, and histomorphological characteristics of IPT while highlighting its associated diagnostic challenges. **Materials and Methods:** A retrospective cross-sectional review of all the IPT diagnosed in our institution between January 1999 and December 2018 was conducted. The samples were received from within and outside the hospital facility. The demographic data, clinical history, and histologic reports were reviewed. **Results:** A total of 25 cases of histologically confirmed IPT were seen. Patients' age ranges from 7 to 74 years with a mean age of 38.96 years and standard deviation \pm 17.94 years. There was a bimodal peak occurrence in the third and fifth decades. Most of the patients were adults (23, 92%), whereas only 2 (8%) were children. There was a female preponderance with a male-to-female ratio of 1:2.6. The head and neck had the highest number of cases (44%), followed by the gastrointestinal tract (GIT) (40%). Eight (73%) of head and neck cases occurred in the orbit. The presenting complaints depended on the site of the lesion with pain and swelling being the commonest symptoms irrespective of the site of the lesions. Two cases of bilateral IPT were observed. Immunohistochemistry was used in a certain condition of diagnostic dilemma. **Conclusion:** This study showed a female preponderance of IPT with the head and neck and GIT being the most common location. It is important to rule out other differentials in the diagnosis of IPT.

Keywords: Head and neck, histomorphology, Ibadan, inflammatory pseudotumor, Nigeria

Introduction

Inflammatory pseudotumor (IPT) is a relatively rare benign disease which dated back to 1939 when it was first described by Bunn.^[1] Different names have been used to describe this entity in the literature, and this is a pointer to the heterogeneity and complexity of the lesion. Some of these include plasma cell granuloma, inflammatory myofibroblastic tumor, xanthomatous pseudotumor, solitary mast cell granuloma, and inflammatory fibrosarcoma just to mention a few.^[2]

Although IPT has been reported to commonly involve the lung and orbit, the involvement of other sites has also been documented in the literature, and these include omentum, mesentery, liver, urinary bladder, ovary, and almost all the organs of the body.^[3,4] The lesion is said to commonly affect children and adolescents with female preponderance.^[5]

The pathogenesis of IPT is unclear. This lesion is characterized by a mixture of

myofibroblasts, fibroblasts, lymphocytes, plasma cells, eosinophils, and histiocytes in varying proportions. These variations are not only limited to various parts of the tumor but also from one tumor to another.^[6] These histological features relate to the differences in phases of the lesion's development at the time the patient present.^[7]

The clinical symptoms depend on the location and size of the tumor as well as the involved organ or tissue. Patients may be asymptomatic sometimes and can as well present with pain, dyspnea (lung involvement), intestinal obstruction (intestinal involvement), or compression on adjacent structures, especially organs within the confined cavity such as the orbit. Clinical syndromes such as fever, malaise, weight loss, and anemia occur in a third of patients.^[8]

This lesion may mimic malignancy, especially lymphoma in certain presentations, and immunohistochemistry

Mustapha Akanji Ajani^{1,2}, Ebenezer O. Fatunla¹, Francis A. Onakpoma¹, Ayodeji A. Salami^{1,2}

¹Department of Pathology, University College Hospital,

²Department of Pathology, College of Medicine, University of Ibadan, Ibadan, Oyo State, Nigeria

Address for correspondence:

Dr. Mustapha Akanji Ajani, Department of Pathology, College of Medicine, University of Ibadan and University College Hospital, Ibadan, Oyo State, Nigeria.
E-mail: ajanimustapha42@gmail.com

Received: 03 March 2020

Revised: 26 July 2020

Accepted: 08 September 2020

Published: 28 November 2020

Access this article online

Website: www.advbiores.net

DOI: 10.4103/abr.abr_48_20

Quick Response Code:



How to cite this article: Ajani MA, Fatunla EO, Onakpoma FA, Salami AA. Inflammatory pseudotumor: A 20-year single institutional experience. *Adv Biomed Res* 2020;9:68.

This is an open access journal, and articles are distributed under the terms of the Creative Commons Attribution-NonCommercial-ShareAlike 4.0 License, which allows others to remix, tweak, and build upon the work non-commercially, as long as appropriate credit is given and the new creations are licensed under the identical terms.

For reprints contact: WKHLRPMedknow_reprints@wolterskluwer.com

may be needed to ascertain the diagnosis.^[9] IPT shows diffuse positivity for vimentin, muscle-specific actin, and smooth muscle actin in the spindle cell, while desmin is focally positive. Myogenin, myoglobin, and S-100 are usually negative.^[8] In this study, we describe the clinicopathological characteristics of IPT with a special discussion on the differential diagnosis in certain case scenarios.

Materials and Methods

We carried out a retrospective review of all IPT diagnosed in the Department of Pathology, University College Hospital, Ibadan, Nigeria, between January 1999 and December 2018. The samples were received from within and outside the teaching hospital.

The surgical daybooks of the department within the study period were searched through for cases with a diagnosis of IPT. Demographic data of these cases which included variables such as age, sex, hospital number, histology number, sites of the lesion, and presenting symptoms were extracted from the surgical daybooks using data extraction form. The surgical daybook of the department contains all the clinicopathological details of all the histologically diagnosed cases in the hospital.

The hematoxylin and eosin-stained slides of the cases were retrieved from the departmental archives and where necessary, new slides were made from the stored paraffin-embedded tissue blocks. Two pathologists independently looked at the histological slides to ascertain the diagnosis of IPT.

The inclusion criteria included cases with clinicopathological data, retrievable slides, and or formalin-fixed paraffin-embedded tissue blocks. Cases without these aforementioned attributes were excluded from the study.

There was no direct contact or effect on the participants of this study since it was a retrospective descriptive study. The analysis was carried out using the Statistical Package for the Social Sciences Chicago, Illinois State (SPSS) software version 23 (IBM Corporation, SPSS Statistics Inc., USA, 2014) The Chi-squared test was used to measure the level of association between the categorical variables. The level of significance was set as $P < 0.05$.

Results

A total of 25 cases of histologically confirmed IPT were reported in the department of pathology over the study period. The age of the patients ranged from 7 to 74 years with a mean age of 38.96 years and standard deviation (SD) ± 17.94 years. Children accounted for 8.0% ($n = 2$), whereas adult accounted for 92% ($n = 23$). There was a bimodal peak distribution of the lesion with patients in the third and fifth decades of life having higher

occurrence [Table 1]. There was a female preponderance with 18 females and 7 males and a male-to-female ratio of 1:2.6 [Figure 1].

The head and neck ($n = 11$, 44%) and the gastrointestinal area ($n = 10$, 40%) were the most frequently affected areas [Figure 2]. Only two pediatric cases occurred in the head and neck regions. The head and neck were also the most frequently affected sites in young adults, whereas in the middle-aged patients, the gastrointestinal tracts (GITs) were more frequently involved [Table 2]. There was no statistical significance between the age and the location of the lesion ($P = 0.069$).

The head and neck were the most commonly involved area in the two genders. The mesentery ($n = 2$) and the omentum ($n = 2$) were both eight percent each, and the two omental cases described in this study occurred in females only [Table 3]. There was no statistical significance between the gender and the location of the lesion ($P = 0.622$).

The orbital IPT constituted eight (73%) of the head and neck cases with age range from 7 years to 58 years, mean age of 30 years, SD ± 18.44 years, and male-to-female ratio of 1:3 with no statistically significant association ($P = 0.273$) [Table 4].

The age range of the gastrointestinal IPT was 36 years to 74 years with a mean age of 48.5 years, SD ± 23.79 years, and male-to-female ratio of 1:2.3 with no statistical significance ($P = 0.432$) [Table 5]. Large intestine cases constituted 50% ($n = 5$) of the gastrointestinal IPT.

Symptoms of the lesion are mostly nonspecific and differ according to the affected area [Table 6]. The commonest

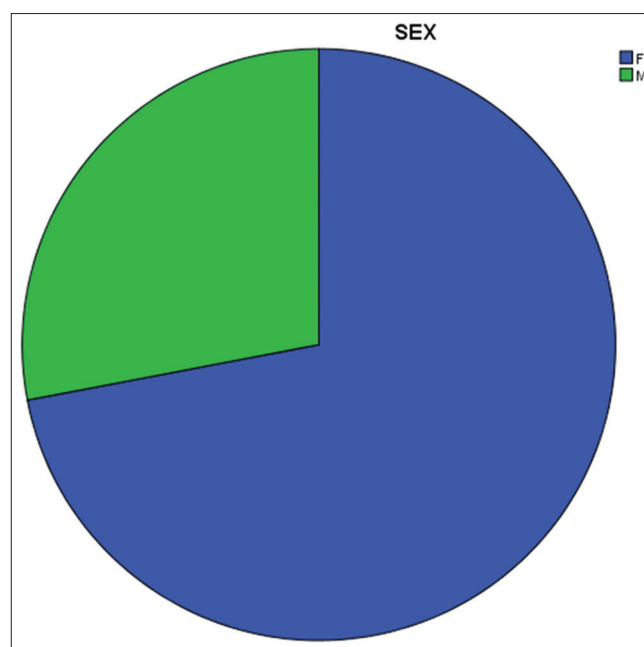


Figure 1: Pie chart showing the sex distribution of inflammatory pseudotumor

Table 1: Age and sex distribution of inflammatory pseudotumor

Age (years)	Sex	Total (%)	
		Male	Female
0-9	0	2	2 (8)
10-19	0	0	0 (0)
20-29	1	6	7 (28)
30-39	3	0	3 (12)
40-49	1	6	7 (28)
50-59	1	1	2 (8)
60-69	0	2	2 (8)
70-79	1	1	2 (8)
Total	7	18	25 (100)

Table 2: Distribution of inflammatory pseudotumor by location and age

Age (years)	GIT	H and N	Mesentery	Omentum	Total (%)	P
0-9	0	2	0	0	2 (8)	
10-19	0	0	0	0	0 (0)	
20-29	0	5	0	2	7 (28)	
30-39	1	1	1	0	3 (12)	
40-49	6	1	0	0	7 (28)	
50-59	1	1	0	0	2 (8)	
60-69	1	1	0	0	2 (8)	
70-79	1	0	1	0	2 (8)	
Total	10 (40)	11 (44)	2 (8)	2 (8)	25 (100)	0.069

P value set at <0.05. GIT: Gastrointestinal tract, H and N: Head and neck

Table 3: Distribution of inflammatory pseudotumor by location and sex

Sex	GIT	H and N	Mesentery	Omentum	Total (%)	P
Female	7	8	1	2	18 (72)	
Male	3	3	1	0	7 (28)	
Total	10 (40)	11 (44)	2 (8)	2 (8)	25 (100)	0.622

P value set at <0.05. GIT: Gastrointestinal tract, H and N: Head and neck

general symptoms were pain and swelling which accounted for 64% ($n = 16$) and 76% ($n = 19$) respectively. Proptosis accounted for the commonest (75%) presenting symptom of orbital IPT.

The inflammatory, myofibroblastic, and fibroblastic cellular components of the lesion were entirely the same irrespective of the location. The inflammatory infiltrates were both acute and chronic inflammatory cells, and these included mostly lymphocytes and plasma cells with some showing macrophages and neutrophil polymorphs. Occasional normal mitotic figures were seen in some lesions, while some do not have mitosis. There were variable areas of hemorrhage and calcification.

One of the patients with facial IPT had presented 8 years earlier with cervical and axillary lymphadenopathy and was

Table 4: Distribution of head and neck inflammatory pseudotumor

Sex	Location			Orbit	Total (%)	P
	Face	Larynx	Ear			
Female	0	1	0	2	3 (27)	
Male	1	0	1	6	8 (73)	
Total	1	1	1	8	11	0.273

P value was set <0.05

Table 5: Distribution of gastrointestinal inflammatory pseudotumor

Sex	Location			Total	P
	Stomach	Small intestine	Large Intestine		
Female	0	1	2	3 (30)	
Male	1	3	3	7 (70)	
Total	1	4	5	10	0.432

P value was set <0.05

Table 6: Frequency of symptoms of inflammatory pseudotumor by location

Location	Symptoms	Frequency (%)
Head and neck orbital (8)	Blurring of vision	5 (62.5)
	Proptosis	6 (75)
	Headache	3 (37.5)
GIT, omentum, and mesentery (14)	Weight	4 (28.6)
	Diarrhea	3 (21.4)
	Constipation	6 (42.9)
	Fever	2 (14.3)
General symptoms (25)	Pain	16 (64)
	Swelling	19 (76)

GIT: Gastrointestinal tract

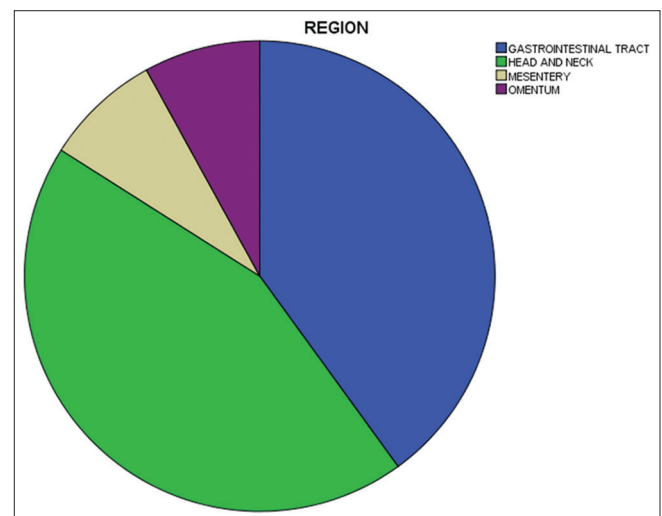


Figure 2: Pie chart showing location distribution of inflammatory pseudotumor

historically diagnosed of Rosai–Dorfman disease. One of the patients was earlier managed for well-differentiated adenocarcinoma of the colon and later developed IPT at

the surgical site. A 45-year-old woman with mesenteric IPT had a previous history of pelvic fracture that was managed conservatively.

A 21-year-old female with a previous diagnosis of bilateral chronic dacryoadenitis developed bilateral axial proptosis with no significant reduction in visual acuity and was subsequently diagnosed with bilateral IPT. This bilaterality was also seen in a 7-year-old girl who had IPT on both conjunctivas 4 months apart.

In another patient, an initial diagnosis of an orbital IPT was made. However, the chronic inflammatory infiltrates, especially the lymphocytes, showed some atypia with brisk mitosis. These features were suggestive of a malignant lesion, possibly lymphoid neoplasm, and immunohistochemistry was done which confirmed it as a B cell lymphoma.

Discussion

This study showed a female predominance of IPT with a male-to-female ratio of 1:2.6 in keeping with previous studies.^[3,5] Studies have shown that this lesion mostly affects children and adolescents, but this only represents 8.0% ($n = 2$) of the patients in this study.^[4,5,10] Majority of the patients in this study were in the third and fifth decades of life representing about three-fifth of all cases, affecting the head and neck and GITs predominantly. A similar modal presentation was documented in a study albeit affecting the lungs mostly.^[11]

IPT can occur anywhere in the body, but the lung and orbit are said to be the most commonly involved locations.^[9,11,12] However, all the cases in this study were extrapulmonary. This could be attributed to the low number of lung biopsies we receive in our center. Our study showed that head and neck were the most affected sites (44%, $n = 11$) in this study as observed by another study.^[4] Orbital lesion was about three-fourth (73%, $n = 8$) of the head and neck IPT and constituted approximately a third (32%) of all the cases in this study with a male-to-female ratio of 1:3. The age range for orbital IPT ranged from 7 years to 58 years with a mean age of 30 years. There is a correlation with a study done by Asadi-Amoli *et al.* on orbital IPT which reported a mean age of 31 years and female predominance with a male-to-female ratio of 1:2.^[7] A study done by Nwafor and Ekanem in Benin, Nigeria, reported 3 cases of orbital pseudotumor representing 8.8% of all the orbito-ocular lesions over a 9-year period.^[13] The central nervous system has also been documented as one of the head and neck locations, but none was observed in this study despite our hospital being a referral center for neurosurgical cases.^[14]

The first abdominal localization of the lesion was described in the liver.^[15] The most common documented extrapulmonary sites are the mesentery and omentum, and this does not correlate well with our finding as they constituted only 16% ($n = 4$) of all the index cases.^[16]

Various sites of involvement in the abdomen have been reported, and these include the stomach, small and large intestines, and Kidney.^[7,17,18] GIT involvement is said to be more common in females, a finding that agrees with a male-to-female ratio of 1:2.3 of GIT IPT in this study.^[4,5,19] In a study done by Huang *et al.*, it was reported that an extensive literature search of a 20-year period using the PubMed revealed only 18 documented cases of colonic IPT describing this location as extremely rare for the lesion.^[20] There were five colonic IPTs described in our study representing half of the gastrointestinal lesions and 20% of the total cases, making it relatively common as against the Yong study. Gastric IPTs in adults are extremely rare, and this was demonstrated in our study as only one gastric case was recorded.^[17]

The presenting symptoms and elicited signs in this condition depend on the location. While these constellations of symptoms and signs seem to be fairly the same for those of gastrointestinal tumor, the head and neck counterparts have varied presentations based on sites. The most common presenting symptoms in this study were pain and swelling representing over three-fifth and three-fourth of the cases, respectively, independent of the locations. Similar findings have been documented by a previous study.^[7] Proptosis has been described as the commonest symptom of IPT as was observed in our study.^[7]

The intestinal tumors mostly arose from the wall and protrude into the lumina causing obstruction. The omental and mesentery IPT were found to also cause features of intestinal obstruction. This could be explained by the fact that the tumor masses were grossly seen impinging on the intestine causing obstruction. The pain could be explained by the infiltration of the intestine in most of the cases, affecting the nerve plexuses in the wall.^[5,9] The speno-orbital IPT had an intracranial extension on imaging, and this could account for the complaint of headache by the patient.

One close differential of IPT which commonly pose a diagnostic challenge is lymphoma.^[3,18] A high index of suspicion and careful histological analysis with immunohistochemistry are sometimes needed to separate them. Such difficulty was encountered in one of the patients in this study where the initial diagnosis of IPT was later changed to a B cell lymphoma after immunohistochemistry was performed.

Two of the patients in this study had preceding histories of surgery and trauma, respectively, and subsequently developed IPT within the same region. Studies have shown that IPT could follow minor trauma or surgery.^[4,19]

A 21-year-old female had bilateral orbital IPT in this study following dacryoadenitis and the bilaterality of IPT has been previously reported by Yuen and Rubin. in a 10-year retrospective study where it was observed that a fourth of

the reviewed cases had bilateral involvement.^[21] Pediatric bilateral involvement in children has also been reported just as was also observed in this study.^[22]

Conclusion

IPT is a rare benign lesion which can occur at any site in the body, although the lung is said to be the commonest site of involvement. Interestingly, there was no single case of pulmonary IPT in this study which was in sharp contrast to published studies. Furthermore, most of the affected patients in this study were young adults as opposed to children and adolescents described in most studies. Common locations we observed included the orbit and the GIT. We also identified known risk factors such as trauma and surgery in some of the patients. Immunohistochemistry was used in certain circumstances of diagnostic dilemma.

Financial support and sponsorship

Nil.

Conflicts of interest

There are no conflicts of interest.

References

1. Garg PK. Inflammatory pseudotumor of urinary bladder: Beware lest we forget. *Urol Ann* 2014;6:390-1.
2. DiFiore JW, Goldblum JR. Inflammatory myofibroblastic tumour of the small intestine. *J Am Coll Surg* 2002;194:502-6.
3. Chan JK. Inflammatory pseudotumour: A family of lesions of diverse nature and etiologies. *Adv Anat Pathology* 1996;3:157-71.
4. Narla LD, Newman B, Spottswood SS, Narla S, Kolli R. Inflammatory pseudotumor. *Radiographics* 2003;23:719-29.
5. Alireza M, Khaleghnejad TA, Naser S, Siamak ST, Marina P, Leila M, *et al.* Abdominal inflammatory myofibroblastic tumor : Report on four cases and review of literature case presentation. *Iran J Pediatr* 2011;21:543-8.
6. Dehner LP. The enigmatic inflammatory pseudotumours: The current state of our understanding, or misunderstanding. *J Pathol* 2000;192:277-9.
7. Asadi-Amoli F, Azadbakht F, Jahanzad E, Sadeghie-Tari A, Akbarzadeh-Jahromi M. Inflammatory pseudotumor of the orbit: A histopathologic and immunohistochemical study of 32 cases. *Iran J Pathol* 2008;3:218-24.
8. World Health Organization Classification of Tumours Pathology and Genetics of Tumours of Soft Tissue and Bone. In: Fletcher CD, Unni K, Mertens F, editors. *Inflammatory Myofibroblastic Tumour*. 4th ed.. Lyon: IARC Press; 2002.
9. Groenveld RL, Raber MH, Oosterhof-Berkas R, Eijken E, Klaase JM. Abdominal inflammatory myofibroblastic tumor. *Case Rep Gastroenterol* 2014;8:67-71.
10. Butrynski JE, D'Adamo DR, Hornick JL, Dal Cin P, Antonescu CR, Jhanwar SC, *et al.* Crizotinib in ALK-rearranged inflammatory myofibroblastic tumor. *N Engl J Med* 2010;363:1727-33.
11. Demirhan O, Ozkara S, Yaman M, Kaynak K. A rare benign tumor of the lung: Inflammatory myofibroblastic tumor – Case report. *Respir Med Case Rep* 2013;8:32-5.
12. Kim JH, Cho JH, Park MS, Chung JH, Lee JG, Kim YS, *et al.* Pulmonary inflammatory pseudotumor – A report of 28 cases. *Korean J Intern Med* 2002;17:252-8.
13. Nwafor C, Ekanem VJ. A study of the histopathologic pattern of orbito-ocular disease in a tertiary hospital in Nigeria. *Sahel Med J* 2014;17:60-4.
14. Jeon YK, Chang KH, Suh YL, Jung HW, Park SH. Inflammatory myofibroblastic tumor of the central nervous system: Clinicopathologic analysis of 10 cases. *J Neuropathol Exp Neurol* 2005;64:254-9.
15. Bjelovic M, Micev M, Spica B, Babic T, Gunjic D, Djuric A, *et al.* Primary inflammatory myofibroblastic tumor of the stomach in an adult woman: A case report and review of the literature. *World J Surg Oncol* 2013;11:35.
16. Chaudhary T, Singh SK, Harsh M. Jejunal inflammatory myofibroblastic tumor : A rare entity. *Int Surg J* 2017;4:2095-7.
17. Leon CJ, Castillo J, Mebold J, Cortez L, Felmer R. Inflammatory myofibroblastic tumor of the stomach: An unusual complication after gastrectomy. *Gastrointest Endosc* 2006;63:347-9.
18. Morar R, Bhayat A, Hammond G, Bruinette H, Feldman C. Inflammatory pseudotumour of the lung: a case report and literature review. *Case Rep Radiol*. 2012;2012:214528. doi:10.1155/2012/214528
19. Sedlic T, Scali EP, Lee WK, Verma S, Chang SD. Inflammatory pseudotumours in the abdomen and pelvis: A pictorial essay. *Can Assoc Radiol J* 2014;65:52-9.
20. Huang Y, Li LP, Wang J, Lun ZJ, Li W, Yang Z. Inflammatory pseudotumor of the colon causing intussusception: A case report and literature review. *World J Gastroenterol* 2015;21:704-10.
21. Yuen SJ, Rubin PA. Idiopathic orbital inflammation: Distribution, clinical features, and treatment outcome. *Arch Ophthalmol* 2003;121:491-9.
22. Shehibo A, Admassu F, Bekele T, Solomon M, Solomon L, Gordon DM. Bilateral orbital pseudotumor in a 3-year-old child: A case report. *J Trop Pediatr* 2018;64:241-4.