

# Comparison of the Effectiveness of Ultrasound-Guided Prolotherapy in Supraspinatus Tendon with Ultrasound-Guided Corticosteroid Injection of Subacromial Subdeltoid Bursa in Rotator Cuff-Related Shoulder Pain: A Clinical Trial Study

## Abstract

**Background:** Shoulder pain is the third most common type of musculoskeletal disorder and rotator cuff (RC) tendinopathy is the most frequent diagnosis. Ultrasound is the most preferable guidance tool for diagnostic and interventional purposes. The aim of this study is to compare the effectiveness of the prolotherapy injection with corticosteroid injection in patients with RC dysfunction. **Materials and Methods:** Thirty to sixty-five-year-old patients with chronic RC disease were divided into two groups. Ultrasound-guided dextrose prolotherapy of supraspinatus tendon was done for one group and ultrasound-guided corticosteroid injection in the subacromial bursa was done for the other groups. Visual analog scale (VAS) and Shoulder Pain and Disability Index (SPADI) were evaluated for both groups at baseline, 3 and 12 weeks after injections. **Results:** Thirty-three patients were included in the result. Both the groups showed significant improvement in VAS and SPADI scores in 3 and 12 weeks after injections compared with preinjection times with no difference between two groups neither in 3 weeks nor in 12 weeks after injections. **Conclusion:** Both ultrasound-guided dextrose prolotherapy and CS injections are effective in the management of RC-related shoulder pain in both short-term and long-term with neither being superior to the other. Therefore, prolotherapy may be a safe alternative therapy instead of corticosteroid injection due to lack of its side effects.

**Keywords:** Glucocorticoids, injections, prolotherapy, rotator cuff injuries

## Introduction

Shoulder pain is the third most common type of musculoskeletal disorder and rotator cuff (RC) dysfunction secondary to the supraspinatus tendinopathy is the most frequent diagnosis among multiple causes.<sup>[1-4]</sup> There is a significant increase in frequency of RC-related shoulder pain with aging process especially after 50 years.<sup>[5-8]</sup> The pathology of the RC is considered to be multifactorial from repetitive overuse injuries or acute trauma in younger individuals to degenerative process without a history of the previous trauma in older patients.<sup>[9-11]</sup> RC dysfunction can interfere with job performance and activity of daily living.<sup>[12,13]</sup> Mucoïd degeneration and angiofibroblastic hyperplasia including hypercellularity, neovascularization, and disorganization of the matrix without inflammation are findings in its histopathology.<sup>[14-18]</sup>

This is an open access journal, and articles are distributed under the terms of the Creative Commons Attribution-NonCommercial-ShareAlike 4.0 License, which allows others to remix, tweak, and build upon the work non-commercially, as long as appropriate credit is given and the new creations are licensed under the identical terms.

For reprints contact: [WKHLRPMedknow\\_reprints@wolterskluwer.com](mailto:WKHLRPMedknow_reprints@wolterskluwer.com)

Subacromial subdeltoid bursopathy is the most prevalent reported finding on diagnostic ultrasonography of the shoulder pain and many physicians use ultrasound for diagnostic and interventional aims about the shoulder.<sup>[19]</sup> It is safe, accurate, portable and low cost compared with magnetic resonance imaging.<sup>[6,19,20]</sup> It can detect subacromial bursopathy which defined as about more than 1 mm in thickness with anechoic fluid around the tendon visualized using a high frequency (>10 MHZ) linear array transducer placed long axis to the supraspinatus tendon fibers.<sup>[19,21,22]</sup> Nonoperative management is the first-line approach to treatment in RC tendinopathy.<sup>[1]</sup> Subacromial subdeltoid corticosteroid (CS) injection still remains one of the most common methods for the management of RC lesions.<sup>[4,23]</sup> Some studies support limitation in subacromial CS injection for the treatment of inflammatory conditions

**How to cite this article:** Nasiri A, Mohamadi Jahromi LS, Vafaei MA, Parvin R, Fakheri MS, Sadeghi S. Comparison of the effectiveness of ultrasound-guided prolotherapy in supraspinatus tendon with ultrasound-guided corticosteroid injection of subacromial subdeltoid bursa in rotator cuff-related shoulder pain: A clinical trial study. *Adv Biomed Res* 2021;10:12.

Aref Nasiri,  
Leila Sadat  
Mohamadi Jahromi,  
Mohammad Amin  
Vafaei,  
Reyhaneh Parvin,  
Maryam Sadat  
Fakheri,  
Shahram Sadeghi<sup>1</sup>

Department of Physical  
Medicine and Rehabilitation,  
Shiraz University of Medical  
Sciences, Shiraz, <sup>1</sup>Physical  
Medicine and Rehabilitation  
Research Center, Shahid  
Beheshti University of Medical  
Sciences, Tehran, Iran

## Address for correspondence:

Dr. Leila Sadat Mohamadi  
Jahromi,  
Department of Physical  
Medicine and Rehabilitation,  
Faghihi Hospital, Shiraz, Iran.  
E-mail: [mohamadil2668@gmail.com](mailto:mohamadil2668@gmail.com)

Received: 26 July 2020

Revised: 25 August 2020

Accepted: 07 September 2020

Published: 30 March 2021

## Access this article online

Website: [www.advbiores.net](http://www.advbiores.net)

DOI: 10.4103/abr.abr\_181\_20

## Quick Response Code:



instead of chronic RC tendinosis or tear due to degenerative disease.<sup>[2,1]</sup>

Prolotherapy with small volume of hyperosmolar dextrose is a type of regenerative injection therapy for chronic musculoskeletal pain.<sup>[5,3,24]</sup> It serves as an irritant agent which starts the inflammatory process that can increase the proliferation of fibroblasts, collagen tissue synthesis and healing.<sup>[5,23]</sup> At high concentration >10%, glucose increases the expression of transforming growth factor beta 1 and induces the proliferation of mesangial cells which can help tighten and heal the tendon or other tissues.<sup>[3]</sup> It may provide better results in the long term (over 24 weeks) in comparison with CS.<sup>[5]</sup>

Lin *et al.* evaluated the effects of an ultrasound-guided hypertonic dextrose injection for patients with chronic supraspinatus tendinopathy. The study was randomized double blind placebo-controlled trials. The group treated with one dose of an ultrasound-guided hypertonic dextrose 20% injection at the supraspinatus enthesis site compared with control patients received one dose of 5% saline through the same method. Thirty-one patients with chronic supraspinatus tendinopathy and shoulder pain for more than 6 months were included (15 patients in each group). The result showed a significant improvement in the visual analog scale (VAS), Shoulder Pain and Disability Index (SPADI), shoulder active range of motion of flexion and abduction compared with the control group at 2 weeks after the injections. However, the effect did not sustain until 6 weeks after the injection.<sup>[5]</sup>

Seven *et al.* evaluated the effectiveness of the prolotherapy under guide of sonography among 60 patients with chronic RC lesions and compared it with the effectiveness of physiotherapy for other 60 patients with the same problem as control group. The result showed dextrose prolotherapy decreased pain and improved shoulder function and patient satisfaction due to significant differences in VAS, SPADI, Western Ontario RC Index scales between two groups.<sup>[10]</sup>

Although many patients can be healed with traditional conservative methods such as subacromial corticosteroid injection, they may not be effective in some groups. Furthermore, CS injections have side effects and short-term benefits according to some studies. Hence, there is a need for new methods that provide tissue renewal and healing without any significant side effects and longer benefits in such patients.<sup>[5,10,25]</sup>

The present study aimed to compare dextrose prolotherapy injection in to the supraspinatus tendon with CS injection in to the subacromial subdeltoid bursa in patients with shoulder pain related to RC tendinopathy under guidance of ultrasonography as the most preferable tool for increased accuracy and efficacy of procedure and ensure correct location of the needle and delivery of the drug.<sup>[1,3,4]</sup>

## Materials and Methods

Each patient enrolled in this study signed an informed consent. The local Institutional Ethics Committee approval code is IR.SUMS.MED.REC.1397.186 and the Iranian Registry of Clinical Trials (IRCT) confirmation's code is IRCT20191129045542N1.

This is a randomized clinical trial (RCT) study which was performed on patients referring to physical medicine and rehabilitation units under supervision of Shiraz university of Medical Sciences in Shiraz city.

Between January 2018 and December 2019, this prospective RCT recruited 40 patients who were randomly allocated in two groups by Block Randomization Assignment and double blind methods to receive either prolotherapy or CS injections. Inclusion criteria were patients from 30 to 65-year-old with long lasting symptoms (including shoulder pain and loss of range of motion which induced shoulder dysfunction) of at list 6 months or refractory to at list 3 months of conservative methods with definitive clinical diagnosis of RC lesions which were confirmed by history, physical examination (including positive Jobe, Howkin's, Yocum or Neer tests), and ultrasonography (having RC lesions in forms of hypochoic areas defining as tendonitis or partial tear if the soft tissue or muscle fibers will not be completely disrupted) referring to physical medicine and rehabilitation units under supervision of Shiraz University of Medical Sciences in Shiraz.

Patients with rheumatic disease, diabetes mellitus, osteomyelitis, active infectious disease, history of chronic infections in the treatment area, positive history of previous operation of the involved shoulder, positive history of local injection at treatment area in previous 12 weeks, bleeding tendency, pregnancy, and frozen shoulder were excluded from this study.

A total of 33 patients out of 40 were included in the results due to lack of cooperation in follow-up. The primary characteristics of each patient such as age, sex, and side of injection (right or left shoulder) were identified and recorded.

Two kinds of questionnaires were filled for each patient before injection, 3 and 12 weeks after that through the researcher's verbal questioning from them. These questionnaires were VAS and SPADI scales. The first one contained zero to ten scores with zero for no pain and ten for the worst pain. The latter questionnaire was developed to measure current shoulder pain and disability in an outpatient setting. It contained 13 parameters that evaluate two domains: 5 parameters that measure pain and 8 parameters for measuring of disability.

For prolotherapy group, the injections were performed while the patient was positioned in lateral decubitus and the involved arms were behind their backs with internal

rotation and hyperextension of shoulder for supraspinatus view. Philips ultrasound device was used to identify the location and the depth of injection points. The probe was positioned perpendicular on the skin in short axis view of supraspinatus tendon and the needle was inserted with in plane method. Injections were applied under aseptic conditions using a 23 Gage needle with 40 mm in length as followed: 2 ml of prolotherapy solution (A mixture containing 1 ml of 50% hypertonic dextrose and 1 ml lidocaine 2% giving a final concentration of 25%) that was injected in the multiple points of the hypoechoic supraspinatus tendon.

For CS group, the injections were performed while the position of the shoulder and the probe of the ultrasonography were the same as the previous group. Injections were applied under aseptic conditions using a 23 Gage needle with 40 mm in length as followed: 2 ml CS solution (A mixture containing 1 ml of 40 mg of triamcinolone acetonide and 1 ml lidocaine 2%) which was injected in subacromial subdeltoid bursa using an injection site that is in posterolateral aspect of the acromion.

To reduce pain during injection of the main solution, the skin for patients in both groups and the subacromial bursa in prolotherapy group were injected by 1 ml lidocaine 2% with a 23 Gage needle and the main solutions were injected without removing this needle.

The researcher who filled the questionnaires by asking their questions from patients and patients themselves did not

know the type of substance which was injected for each of them. Furthermore, the solutions were prepared in another room out of view of them and the injections were done by the advisor who was expert for ultrasonography methods.

After the injections, patients were instructed to rest the injected shoulder for 3 days, avoid from any heavy lifting activity, apply cold packs for 20–30 min every 2 or 3 h for up to first 72 h and not to use anti-inflammatory drugs other than acetaminophen (if pain became severe, the patient was instructed to take 500 mg of acetaminophen up to 4 times per day). Patients were also warned to looking for medical attention as soon as possible if severe redness, hotness, and swelling of the site of injection in favor of infection were happened.

The patient enrolled in a home exercise program included pendulum and wall walking exercises doing 3 times a day for 5–10 times in each set starting after 1 day of injections and wall push-up exercise for purpose of scapular stabilizer muscles strengthening starting 3 weeks later.

The consort diagram is brought in Figure 1.

### Statistical analysis

Statistical analysis were conducted spss version 18 software (IBM Corp., 2011, IBM SPSS Statistics for windows, NY, EUA). THE study utilized three sets of analysis: basic descriptive statics, univariate analysis, and multivariate analyses.  $P < 0.05$  was considered statistically significant. Since the distribution of data before injections was normal

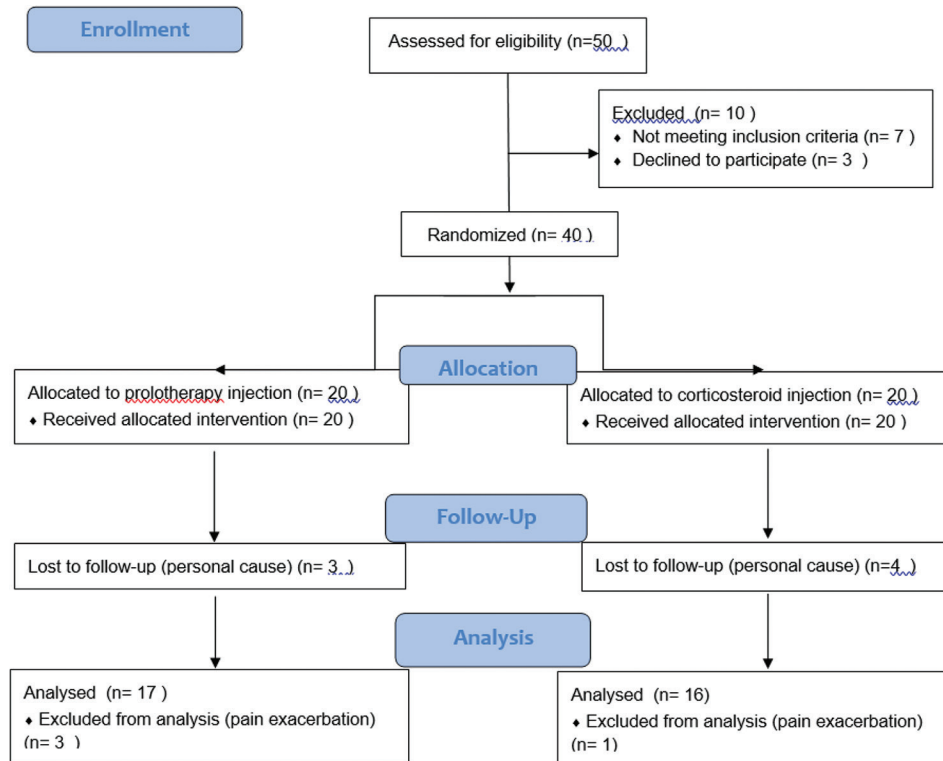


Figure 1: Consort diagram

and after 3 and 12 weeks, there were no serious deviations, we performed repeated measure analysis as a high power analytic method in order to investigate the effect of group and time simultaneously as well as paired sample *t*-test and independent sample *t*-test for each group. For the assessment of the relationship between two categorical variables, Chi-square test was also performed.

## Results

Among 40 patients, seven cases were excluded due to lack of cooperation for follow-up. Therefore, 33 patients (Prolotherapy group: *n* = 17, CS group: *n* = 16) were included in this study. Three patients were excluded from the results in prolotherapy group and one patient from CS group due to severe pain after injection and having to start other conservative managements. Demographic distribution of two groups including age, sex, and analgesic consumption after injections have been analyzed by Chi-square test.

For sex variable, 64.7% in prolotherapy group and 62.5% in CS group were female and 6 patients were male in the both groups which showed no remarkable difference between them according to *P* = 0.895. In prolotherapy group, 35.3% and in CS group, 12.5% of patients had analgesic consumptions after injection which showed no considerable difference between two groups according to *P* = 0.225.

The mean ages were 50.52 ± 9.08 and 47.06 ± 8.90 years in prolotherapy and CS groups respectively which showed no considerable difference between two groups (*P* = 0.277) [Table 1].

According to repeated measure analysis, the results were identified as below:

Both prolotherapy and CS injection groups achieved a significant improvement in the VAS and SPADI scores at three (time 2) and twelve (time 3) weeks after injections when compared to preinjection values (time 1) due to decreased pattern of mean values of the scores for each group individually [Figures 2 and 3].

There was no significant difference in the scores achieved from both questionnaires between two groups regardless of time or in other words, with respect to time in general (neither in 3 weeks nor in 12 weeks after injections) with *P* = 0.57 for VAS [Table 2] and 0.52 for total score of SPADI [Table 3].

For both groups, there was a significant relationship between preinjection time and 3 weeks after that and the time before injection and 12 weeks later (*P* < 0.001) but there was no significant relationship between 3 and 12 weeks after injection for both VAS and SPADI scales (*P* = 0.587 for VAS and 0.318 total score of SPADI [Tables 4 and 5].

In terms of complications, 3 out of 17 patients in prolotherapy group (18%) and 1 out of 16 patients in CS

**Table 1: Demographic variables**

Demographic variables	Dextrose	Corticosteroid	<i>P</i>
Mean age	50.52±9.08	47.06±8.90	0.277
sex	11 (64.7%): female 6 (35.3%): male	10 (62.5%): female 6 (37.5%): male	0.895
Analgesic consumption	6 (35.3%)	2 (12.5%)	0.225

**Table 2: Difference of visual analog scale score between corticosteroid and dextrose groups regardless of time by statistical test of between-subject effects**

Source	df	<i>P</i>
Difference between two groups regardless of time	1	0.573

**Table 3: Difference of shoulder pain and disability index score between corticosteroid and dextrose groups regardless of time by statistical test of between-subject effects**

Source	df	<i>P</i>
Difference between two groups regardless of time	1	0.523

**Table 4: Comparison of the visual analog scale scores in preinjection (time 1), 3 weeks (time 2), and 12 weeks (time 3) postinjection phases relative to each other for both corticosteroid and dextrose groups with pairwise comparison statistical test**

VAS	Time	<i>P</i>
Time 1	2	<0.001
	3	<0.001
Time 2	1	<0.001
	3	0.587
Time 3	1	<0.001
	2	0.587

VAS: Visual analog scale

**Table 5: Comparison of the shoulder pain and disability index scores in pre injection (time 1), 3 weeks (time 2), and 12 weeks (time 3) postinjection phases relative to each other for both corticosteroid and dextrose groups with pairwise comparison statistical test**

SPADI	Time	<i>P</i>
Time 1	2	<0.001
	3	<0.001
Time 2	1	<0.001
	3	0.318
Time 3	1	<0.001
	2	0.318

SPADI: Shoulder pain and disability index

group (6%) developed exacerbation of pain after injections and therefore, for receiving other managements they were excluded from the study, but due to Chi-square analysis, the difference between complications of two groups

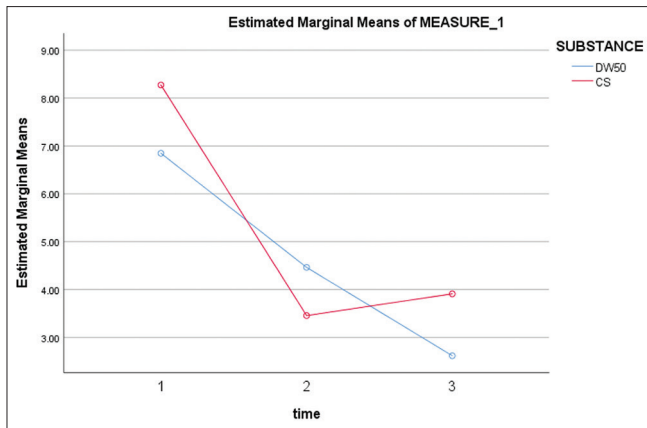


Figure 2: Comparison of estimated marginal means of measure of two groups due to visual analog scale

was not statistically significant ( $P < 0.60$ ). Apart from the mentioned cases, no other serious complication was observed in this study.

Furthermore, Independent sample *t*-test was done for both questionnaires and two groups were compared at baseline, 3 and 12 weeks individually after injections. The result showed no significant differences in baseline, 3, and 12 weeks after injections between two groups [Tables 6 and 7].

## Discussion

In this study, two major shoulder scores (VAS, SPADI) were investigated in the treatment of chronic RC tendinopathy. The results suggest that both CS and glucose prolotherapy injections, in combination with a home exercise therapy program are effective in the management of supraspinatus tendinopathy, with neither being superior to the other. Both the groups showed improvements from baseline for pain and function, although there was no significant difference between the groups at both short-term (3 weeks) and long-term (12 weeks) follow-ups.

RC tendinopathy is the main cause of shoulder pain in all ages.<sup>[10]</sup> Many nonoperative treatment methods have been recommended but optimal procedure continues to be controversial.<sup>[26]</sup> CS injections are the most used conventional procedures.<sup>[10,27]</sup> Most studies reported pain suppression and functional improvement in the treatment of RC tendinopathy, but steroids do not improve healing and have side effects, such as focal inflammation, necrosis, degradation of collagen fibers, rupture of tendons, and worsening of osteoarthritis.<sup>[27,28]</sup>

Prolotherapy has beneficial effects in the treatment of some musculoskeletal problems such as lateral epicondylitis, Achilles enthesopathy, and plantar fasciitis. Easy use, success of treatment and shortening of the duration of rehabilitation are some causes for the preference of this method in such conditions.<sup>[10]</sup> It also improves healing by stimulating extracellular matrix which causes to increase

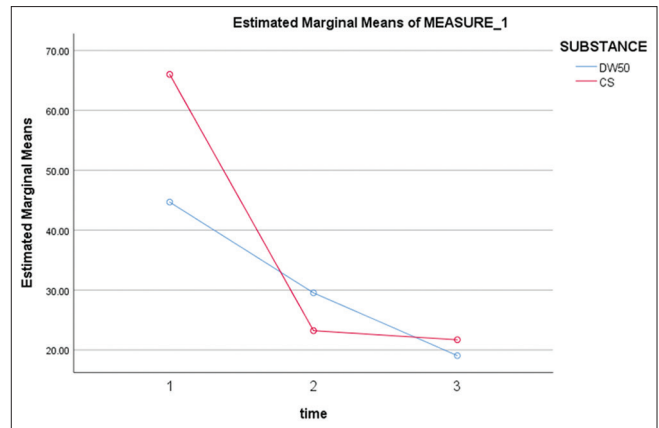


Figure 3: Comparison of estimated marginal means of measure of two groups due to Shoulder Pain and Disability Index

**Table 6: Comparison of the visual analog scale scores between corticosteroid and dextrose groups at each time (time 1: preinjection, time 2: 3 weeks' postinjection, time 3: 12 weeks' postinjection) by *t*-test**

Difference of VAS score	<i>P</i>
Difference of VAS score between two groups in time 1	0.102
Difference of VAS score between two groups in time 2	0.236
Difference of VAS score between two groups in time 3	0.406

VAS: Visual analog scale

**Table 7: Comparison of the shoulder pain and disability index scores of both corticosteroid and dextrose groups at each time (time 1: preinjection, time 2: 3 weeks' postinjection, time 3: 12 weeks' postinjection) by *t*-test**

Difference of SPADI score	<i>P</i>
Difference of SPADI score between two groups in time 1	0.106
Difference of SPADI score between two groups in time 2	0.291
Difference of SPADI score between two groups in time 3	0.834

SPADI: Shoulder pain and disability index, VAS: Visual analog scale

the stability of the joints by tightening and strengthening the ligaments and tendons.<sup>[29]</sup> Prolotherapy was done for the first time in 1950.<sup>[30]</sup> The effectiveness of this alternative therapy in patients with RC tendinopathy was also reported in the literature.<sup>[10]</sup> Proliferation therapy is the other name for this type of injection.<sup>[30]</sup>

Lin *et al.* evaluated the effectiveness of diverse injections including CS, hyaluronic acid, botulinum toxin, platelet-rich plasma (PRP), and prolotherapy in patients with RC tendinopathy. This study was a meta-analysis with searched studies published up to September 31, 2017. Among 1495 records, 18 RCTs were included. The result showed CS played a role in the short-term (3–6 weeks) but not in long-term (over 24 weeks) pain reduction and functional improvement. By contrast, PRP and prolotherapy may yield better outcomes in the long-term.<sup>[31]</sup> The result of this meta-analysis was somewhat different to the present study which might be due to small sample size in our study and

we did not have any longer follow-up more than 12 weeks to show any better effects of prolotherapy injection in longer term in comparison with CS injection.

Although it is believed in a number of previous studies that dextrose prolotherapy has better outcomes in the long term (over 24 weeks) in comparison with subacromial CS which has more benefit in short term (3 weeks),<sup>[5,25,31]</sup> Cole *et al.* performed a prospective RCT with 36 patients with supraspinatus tendinopathy that 17 patients received an ultrasound-guided injections of glucose (25%) in to the tendinopathic parts of the supraspinatus tendon and 19 others received an ultrasound-guided injections of CS in to the subacromial bursa and showed level of pain with overhead activities were significantly reduced at the 3 months' follow-up in the prolotherapy group and at 6 months' follow-up for both the prolotherapy and CS groups.<sup>[3]</sup> The result of this study was somewhat similar to those of our study probably because of almost the same sample size, use of ultrasound for guiding injection in both groups and perhaps similarity in glucose concentration. The difference between the results might be due to the smaller numbers of questionnaires which were evaluated for patients, short duration follow-up and only subjective evaluation of patients after injections in our study compared to this research and also other studies discussed above.

Although the rate of analgesic consumption and pain exacerbation after injections in prolotherapy group was more than CS group (six patients in prolotherapy group vs. 2 patients in CS group had analgesic consumptions and three patients in prolotherapy group and 1 patient in CS group had pain exacerbations), this difference was not significant statistically ( $P = 0.225$  for analgesic consumption and  $P < 0.60$  for pain exacerbation as a complication) which can be due to small sample size. Therefore, in order to be clinically important, more studies with larger sample size are needed.

A strength of this study was that all the injections were done by a single experienced researcher who was guided by an ultrasound technique, in order to reduce the variability of procedures between and within the groups. Another strength was the RCT design, with both patients and persons who evaluate the outcomes being blinded to group selection.

The shortcoming of this study was the absence of a placebo injection control group. Other limitations were its small sample size, relatively short duration of follow-up, low numbers of questionnaires for the evaluation of pain and functional improvement, low cooperation of some patients in following the instructions given in post injection follow-ups and only subjective evaluation of patients without doing ultrasonography for finding any changes in their follow-ups. Furthermore, prolotherapy treatment protocols in the literature include several injections over several months (every 2–6 weeks).<sup>[14]</sup> However, few

evidences for single injection instead of multiple injections were established.

In conclusion, prolotherapy is an easy and satisfying method in the treatment of partial RC disorders. It may be used as an alternative method to CS injection, although it does not have any additional advantages over CS injection in the short- and long-term but in the absence of CS side effects.

## Conclusion

Both corticosteroid and dextrose prolotherapy ultrasound-guided injections in conjunction with a home exercise program are effective in the management of RC-related shoulder pain in both short-term (3 weeks) and long-term (12 weeks) with neither being superior to the other. Therefore, prolotherapy can be an alternative injection to CS due to the lack of steroid's side effects. However, further studies with fewer limitations and larger sample size are recommended for better evaluation.

## Financial support and sponsorship

Shirza University of Medical Sciences.

## Conflicts of interest

There are no conflicts of interest.

## References

1. Chang KV, Hung CY, Wu WT, Han DS, Yang RS, Lin CP. Comparison of the effectiveness of suprascapular nerve block with physical therapy, placebo, and intra-articular injection in management of chronic shoulder pain: A meta-analysis of randomized controlled trials. *Arch Phys Med Rehabil* 2016;97:1366-80.
2. Parsons S, Breen A, Foster NE, Letley L, Pincus T, Vogel S, *et al.* Prevalence and comparative troublesomeness by age of musculoskeletal pain in different body locations. *Fam Pract* 2007;24:308-16.
3. Cole B, Lam P, Hackett L, Murrell GAC. Ultrasound-guided injections for supraspinatus tendinopathy: Corticosteroid versus glucose prolotherapy-a randomized controlled clinical trial. *Shoulder Elbow* 2018;10:170-8.
4. Ekeberg OM, Bautz-Holter E, Tveitå EK, Juel NG, Kvalheim S, Brox JI. Subacromial ultrasound guided or systemic steroid injection for rotator cuff disease: Randomised double blind study. *BMJ* 2009;338:a3112.
5. Lin CL, Huang CC, Huang SW. Effects of hypertonic dextrose injection in chronic supraspinatus tendinopathy of the shoulder: A randomized placebo-controlled trial. *Eur J Phys Rehabil Med* 2019;55:480-7.
6. Dogu B, Yucel SD, Sag SY, Bankaoglu M, Kuran B. Blind or ultrasound-guided corticosteroid injections and short-term response in subacromial impingement syndrome: A randomized, double-blind, prospective study. *Am J Phys Med Rehabil* 2012;91:658-65.
7. Taylor W. Musculoskeletal pain in the adult New Zealand population: Prevalence and impact. *N Z Med J* 2005;118:U1629.
8. Gschwend N, Ivosević-Radovanović D, Patte D. Rotator cuff tear-relationship between clinical and anatomopathological findings. *Arch Orthop Trauma Surg* 1988;107:7-15.

9. Oliva F, Piccirilli E, Bossa M, Via A, Colombo A, Chillemi C, *et al.* I.S.Mu.L.T-rotator cuff tears guidelines. *Mus Lig Ten J* 2016;13;5:227-63.
10. Seven MM, Ersen O, Akpancar S, Ozkan H, Turkkan S, Yildiz Y, *et al.* Effectiveness of prolotherapy in the treatment of chronic rotator cuff lesions. *Orthop Traumatol Surg Res* 2017;103:427-33.
11. Patte D. Classification of rotator cuff lesions. *Clin Orthop Relat Res* 1990;(254):81-6.
12. Bertrand H, Reeves KD, Bennett CJ, Bicknell S, Cheng AL. Dextrose prolotherapy versus control injections in painful rotator cuff tendinopathy. *Arch Phys Med Rehabil* 2016;97:17-25.
13. Burbank KM, Stevenson JH, Czarnecki GR, Dorfman J. Chronic shoulder pain: Part I. Evaluation and diagnosis. *Am Fam Physician* 2008;77:453-60.
14. Millar NL, Wei AQ, Molloy TJ, Bonar F, Murrell GA. Cytokines and apoptosis in supraspinatus tendinopathy. *J Bone Joint Surg Br* 2009;91:417-24.
15. Coombes BK, Bisset L, Vicenzino B. Efficacy and safety of corticosteroid injections and other injections for management of tendinopathy: A systematic review of randomised controlled trials. *Lancet* 2010;376:1751-67.
16. Khan KM, Cook JL, Kannus P, Maffulli N, Bonar SF. Time to abandon the "tendinitis" myth. *BMJ* 2002;324:626-7.
17. Rees J, Maffulli N, Cook J. Management of tendinopathy. *Am J Sports Med* 2009;37:1855-67.
18. Maffulli N, Testa V, Capasso G, Ewen SW, Sullo A, Benazzo F, *et al.* Similar histopathological picture in males with Achilles and patellar tendinopathy. *Med Sci Sports Exerc* 2004;36:1470-5.
19. Pourcho AM, Colio SW, Hall MM. Ultrasound-guided interventional procedures about the shoulder: Anatomy, indications, and techniques. *Phys Med Rehabil Clin N Am* 2016;27:555-72.
20. Finnoff JT, Smith J, Peck ER. Ultrasonography of the shoulder. *Phys Med Rehabil Clin N Am* 2010;21:481-507.
21. Lee DH, Hong JY, Lee MY, Kwack KS, Yoon SH. Relation between subacromial bursitis on ultrasonography and efficacy of subacromial corticosteroid injection in rotator cuff disease: A prospective comparison study. *Arch Phys Med Rehabil* 2017;98:881-7.
22. Draghi F, Scudeller L, Draghi AG, Bortolotto C. Prevalence of subacromial-subdeltoid bursitis in shoulder pain: An ultrasonographic study. *J Ultrasound* 2015;18:151-8.
23. Lee DH, Kwack KS, Rah UW, Yoon SH. Prolotherapy for refractory rotator cuff disease: Retrospective case-control study of 1-year follow-up. *Arch Phys Med Rehabil* 2015;96:2027-32.
24. Seenauth C, Inouye V, Langland JO. Dextrose prolotherapy for chronic shoulder pain: A case report. *Altern Ther Health Med* 2018;24:56-60.
25. Cook T, Minns Lowe C, Maybury M, Lewis JS. Are corticosteroid injections more beneficial than anaesthetic injections alone in the management of rotator cuff-related shoulder pain? A systematic review. *Br J Sports Med* 2018;52:497-504.
26. Bishay V, Gallo R. The evaluation and treatment of rotator cuff pathology. *Prim Care* 2013;40:889-910.
27. Tempfer H, Gehwolf R, Lehner C, Wagner A, Mtsariashvili M, Bauer H, *et al.* Effects of crystalline glucocorticoid triamcinolone acetate on cultured human supraspinatus tendon cells. *Acta Orthop* 2009; 80:357-62.
28. Scarpone M, Rabago D, Zgierska A, Arbogast G, Snell E. The efficacy of prolotherapy for lateral epicondylitis: A pilot study. *Clin J Sport Med* 2008;18:248-54.
29. Di Paolo S, Gesualdo L, Ranieri E, Grandaliano G, Schena F. High glucose concentration induces the over expression of transforming growth factor-beta through the activation of a platelet-derived growth factor loop in human mesangial cells. *Am J Pathol* 1996;149:2095-106.
30. Farpour HR, Fereydooni F. Comparative effectiveness of intra-articular prolotherapy versus peri-articular prolotherapy on pain reduction and improving function in patients with knee osteoarthritis: A randomized clinical trial. *Electron Physician* 2017;9:5663-9.
31. Lin MT, Chiang CF, Wu CH, Huang YT, Tu YK, Wang TG. Comparative effectiveness of injection therapies in rotator cuff tendinopathy: A systematic review, pairwise and network meta-analysis of randomized controlled trials. *Arch Phys Med Rehabil* 2019;100:336-49.e15.