

Case Report

Anaplastic Large Cell Lymphoma, Giant Cell-Rich, Involving a Nonimplant Breast: A Case Report and Review of the Literature

Abstract

Primary breast lymphomas are uncommon tumors and account for <1% of all malignant neoplasms of the breast. They are almost always of non-Hodgkin type, with B-cell lymphomas being the most common subtype. Anaplastic large cell lymphoma (ALCL) is a rare T-cell lymphoma that can involve the breast. Most of the articles in the literature describe ALCL in association with breast implants. We present a 48-year-old woman with a left breast enlargement and no history of an implant. Microscopic sections showed a high-grade CD30-positive lymphoid neoplasm with frequent giant cells, which turned out to be a primary ALCL of the breast, giant cell-rich pattern. To our knowledge, no cases of primary ALCL, giant cell-rich variant, have been reported in the breast in the absence of an implant making our case unique.

Keywords: Anaplastic large cell lymphoma, breast malignant neoplasms, giant cells, lymphoma

Introduction

Non-Hodgkin lymphomas (NHLs) are the most common nonepithelial neoplasms of the breast. Primary breast lymphomas (PBLs) represent <0.5% of all malignant breast neoplasms. They account for <1% of all NHLs and for about 2% of extranodal NHLs.^[1-4] Involvement of breast by lymphomas can occur as a primary presentation or as a secondary involvement from a systemic disease. The diagnostic criteria for the diagnosis of PBL were proposed by Wiseman and Liao^[3,5] in 1972. This criteria included the following: (1) adequate diagnostic pathological material; (2) the primary clinical site of lymphoma presentation is the breast; (3) history of previous primary systemic or widespread lymphoma should be absent at the time of diagnosis; (4) histological evidence of presence of the lymphomatous infiltrate in close association the breast parenchymal tissue; (5) radiological demonstration of lymphoma involving the breast tissue in cases of limited biopsy specimen; and (6) involvement of ipsilateral axillary lymph nodes was considered acceptable if they develop simultaneously with the primary breast (PB) tumor. The vast majority of PBLs shows B-cell

phenotype.^[1-3] PB T-cell lymphomas are extremely rare. Almost all T-cell lymphoma types have been reported in the breast.^[6,7] Anaplastic large cell lymphoma (ALCL) is a rare T-cell lymphoma that expresses the lymphocyte activation marker CD30. Most of the reported cases of PB-ALCL are seen in association with breast implants in women.^[2,6,7] The aim of this study is to present a rare case of PB-ALCL, exhibiting giant cell-rich pattern which occurred in the absence of breast implant and to give a brief review on PBLs, with emphasis on ALCL focusing on its morphological variants and types.

Case Report

A 48-year-old woman presented to the emergency department complaining of left breast enlargement and black discoloration of breast skin for 1 year. There was a history of fever, loss of appetite, and weight loss. She is a known case of diabetes mellitus and hypertension. She had no previous history of lymphoma or breast implant. No family history of breast cancer or lymphoma. On examination, the left breast was swollen with dark discoloration of about half of the skin. Multiple small punched-out ulcers, discharging purulent material, were seen all over her breast. The nipple was retracted. The breast was

**Rana Shaker
Al-Zaidi,
Nasir I. Al-Noor**

*Department of Laboratory
and Blood Bank, Anatomic
Pathology Section, King Faisal
Hospital, Makkah, Kingdom of
Saudi Arabia*

Address for correspondence:

*Dr. Rana Shaker Al-Zaidi,
Department of Laboratory
and Blood Bank, Anatomic
Pathology Section, King
Faisal Hospital, Makkah,
Kingdom of Saudi Arabia.
E-mail: angelysurgery@yahoo.com*

Received: 16 December 2020
Revised: 22 February 2021
Accepted: 21 April 2021
Published: 29 September 2021

Access this article online

Website: www.advbiores.net

DOI: 10.4103/abr.abr_298_20

Quick Response Code:



How to cite this article: Al-Zaidi RS, Al-Noor NI. Anaplastic large cell lymphoma, giant cell-rich, involving a nonimplant breast: A case report and review of the literature. *Adv Biomed Res* 2021;10:26.

This is an open access journal, and articles are distributed under the terms of the Creative Commons Attribution-NonCommercial-ShareAlike 4.0 License, which allows others to remix, tweak, and build upon the work non-commercially, as long as appropriate credit is given and the new creations are licensed under the identical terms.

For reprints contact: WKHLRPMedknow_reprints@wolterskluwer.com

tender, warm, and firm on palpation. A large palpable left axillary lymph node was found. Laboratory tests showed marked leukocytosis and prolongation of coagulation profile markers. Microbiological cultures from the wound and blood were positive for methicillin-resistant *Staphylococcus aureus* (MRSA) organism. Unfortunately, no radiological studies could be done. An emergency surgery was decided due to deterioration of the patient condition, and a simple mastectomy was performed. The patient died 2 days after the operation in the intensive care unit due to disseminated intravascular coagulation and septicemia secondary to MRSA. No autopsy study was performed. Grossly, a simple mastectomy specimen was received in 10% neutral-buffered formalin. It was covered on one surface by an ellipse of black ulcerated gangrenous skin with retracted nipple. Serial sectioning through the breast parenchyma revealed multiple randomly distributed firm tan-white focally necrotic solid tumor nodules, measured from 0.3 cm to 1 cm in greatest dimensions. Microscopic sections showed a nodular infiltrate comprised of discohesive large-giant highly atypical round tumor cells with ample eosinophilic to amphophilic cytoplasm [Figure 1]. There was a striking nuclear pleomorphism with mono-nucleated, bi-nucleated, multinucleated, and multilobated forms [Figure 2]. The neoplastic cells exhibited coarsely clumped chromatin pattern, irregular nuclear membrane, and one to several basophilic micro- and macronucleoli. A significant proportion of tumor cells exhibited eccentric, horseshoe-or kidney-shaped nuclei “hallmark cells” [Figure 3a and b]. A subset of tumor cells showed “wreath-like” appearance, bizarre nuclear shapes, mummified cells, and Reed–Sternberg cells-like morphology. Occasional cells showed engulfed intracytoplasmic neutrophils (emperipolesis). Brisk mitotic activity was noted with frequent atypical

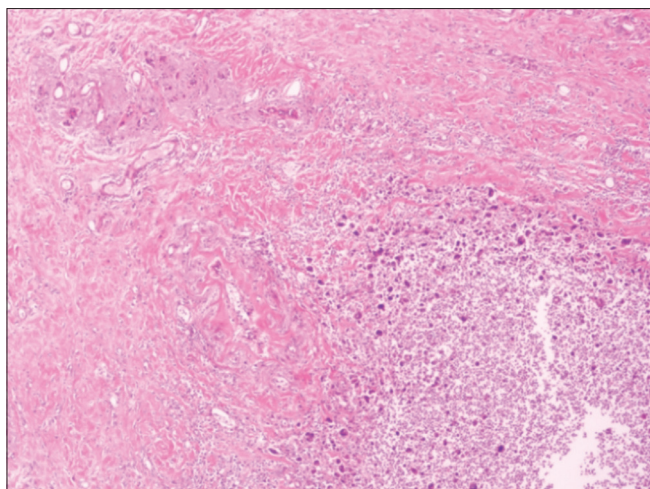


Figure 1: Anaplastic large cell lymphoma, giant cell-rich, tumor nodule comprised of sheets of large neoplastic cells with scattered giant cells in a background of mixed inflammatory cells. An atrophic mammary duct and lobule is present in the left upper corner (H and E stain, original magnification $\times 40$)

mitotic figures [Figure 4]. The background showed mixed inflammatory cell infiltrate. Focal perivascular distribution of tumor cells was noted. The adjacent breast parenchyma showed un-involved atrophic ducts and lobules. The epidermis showed focal ulcerations, but no epidermotropism was noted. The dermis is infiltrated by clusters and nodules of tumor cells. Perineural invasion was noted in the dermis as well. Immunohistochemistry, tumor cells showed uniform strong and homogenous immunoreactivity for CD30 on the cell membrane and in the Golgi region [Figure 5]. Strong positivity for CD45 (Leukocyte Common Antigen, LCA) [Figure 6], CD45RO, granzyme B, TIA-1, and vimentin was seen. Focal expression of CD4 [Figure 7], CD43, EMA, BCL-6, and BCL-2 was noted. There was loss of the other T-cell markers including CD1a, CD3, CD5, CD8, CD7, and CD2. All B-cell lineage markers including CD20, CD19, CD79a, and PAX-5 were negative. Anaplastic lymphoma kinase (ALK)-1, CD15, CD68, pancytokeratins, S100 protein, desmin, SMA, HMB-45, P63, and E. cadherin were completely negative. MIB-1 (Ki-67) labeling index was extremely high (95%) indicating a high-grade tumor. Based on the morphological features seen and the immunohistochemical results, we decided to sign out the case as (PB-ALCL, giant cell-rich pattern).

Discussion

PBLs are relatively uncommon neoplasms and account for 0.04%–0.5% of all malignant neoplasms of breast. This is attributed to the scarcity of the native lymphoid tissue in the breast. They constitute about 1.7%–2.2% of all extranodal lymphomas and 0.38%–0.7% of all NHLs.^[1-4,8] PBLs are heterogeneous disease. They occur almost exclusively in females and are exceedingly rare in males.^[1,7] The median age range at presentation is 60–70 years according to several series in the literature.^[1-4] Clinical presentation and

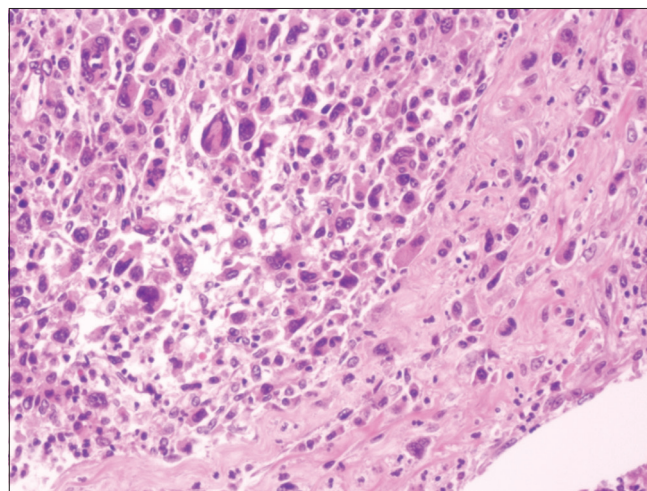


Figure 2: Various patterns of tumor cells are evident including hallmark cells, mononucleated, binucleated, and multinucleated giant tumor cells. (H and E stain, original magnification $\times 200$)

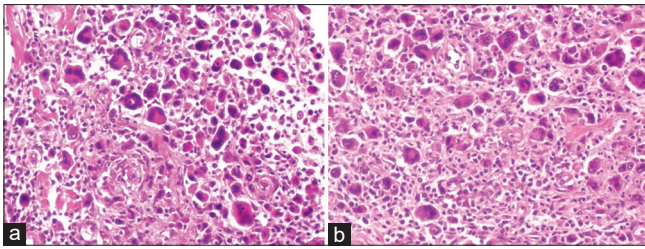


Figure 3: (a and b) Several hallmark cells and multinucleated giant cells with scattered mitotic figures (H and E stain, original magnification ×200)

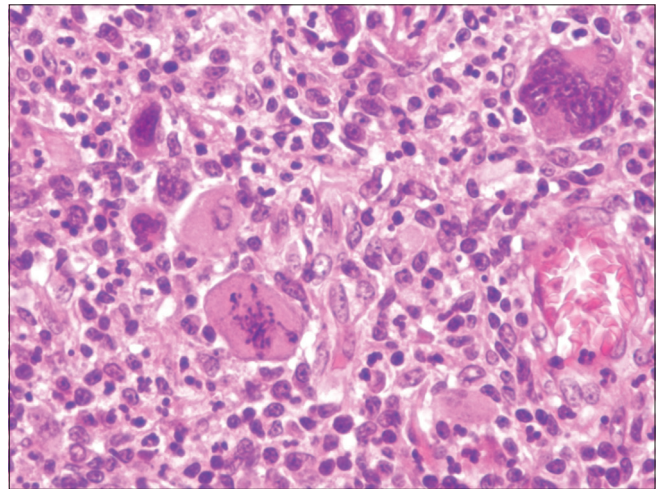


Figure 4: A multinucleated tumor giant cell, scattered mononuclear cells, and an atypical mitotic figure is evident in this field (H and E stain, original magnification ×400)

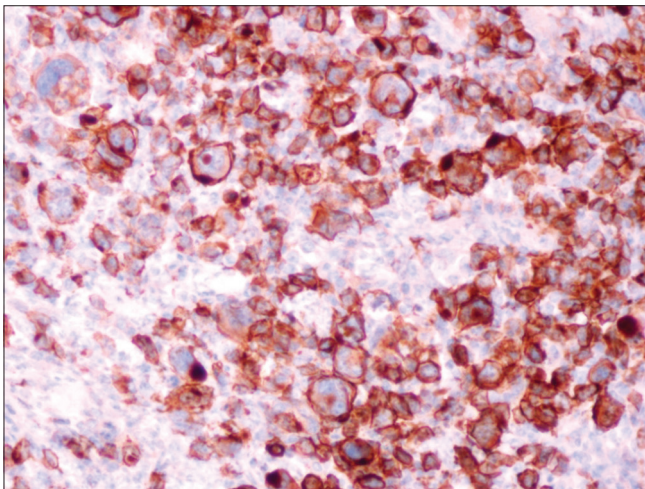


Figure 5: Immunohistochemical stain for CD30 shows diffuse strong immunoreactivity on the cell membrane and in the Golgi region (original magnification ×200)

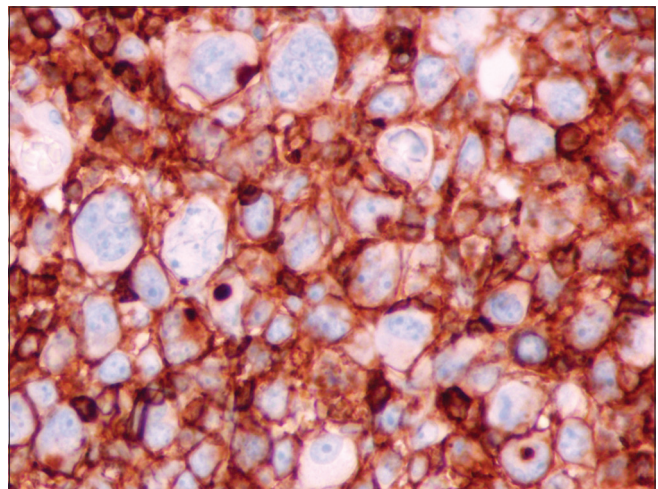


Figure 6: Immunohistochemical stain for CD45 (LCA) shows diffuse membranous staining (original magnification ×200)

radiological findings of PBLs are not so different from those of breast carcinoma. PBLs are usually present with palpable painless mass/masses, diffuse breast enlargement/hardening, violaceous skin over the lesion, and palpable axillary lymph nodes. However, in some cases, PBLs are diagnosed incidentally during radiologic screening for breast cancer.^[1,2,6,8] A recent study showed an equal incidence of PBLs in both right and left breasts.^[2] Radiologic features suggestive of PBLs include a well-circumscribed mass with regular smooth outline, thin perimeter radiolucency, and diffuse breast involvement with thickening of skin.^[1] Gross features of PBLs are analogous to those of breast carcinoma. Most commonly, they mimic medullary and lobular breast carcinomas.^[6] Histologic features include diffuse pattern of growth with periductal/perilobular infiltration. Single file or targetoid growth pattern around lobules resemble invasive lobular carcinoma can be seen. Lymphoepithelial lesions, cells exhibit signet ring features, starry-sky pattern, high mitotic rate/proliferative index, and tumor necrosis/apoptotic bodies have been described.^[6] The majority of PBLs exhibit B-cell lineage, the most frequent is DLBCL (40%–70%).^[1-4,8,9] T-cell lymphomas, whether primary or secondary, are exceptional in breast. Almost all subtypes of T-cell lymphomas have been described to involve the breast parenchyma.^[6,7] ALCL is a T-cell lymphoma that can involve the breast. It encompasses a

group of heterogeneous mature T-cell lymphoid neoplasms that share morphological and immunophenotypic features, namely strong CD30 expression as well as variable loss of T-cell markers. However, they display variable clinical presentation, molecular characteristics, and prognosis.^[10] It originates from activated cytotoxic T-lymphocytes. It comprises 1%–3% of all adult NHLs and shows a male predominance.^[10-12] The revised fourth (2016) edition of the WHO classification of hematopoietic and lymphoid neoplasm recognizes three major types of ALCL: namely, (1) ALCL, ALK positive (ALK + ALCL); (2) ALCL, ALK negative (ALK – ALCL); and (3) breast-implant associated ALCL.^[11,13] ALCL is a systemic disease that affects lymph nodes as well as extranodal sites including skin, bone, soft tissue, lung, liver, spleen, and bone marrow.^[10-12,14] It shows an aggressive behavior with rapid progression and systemic B-symptoms. Morphologically, it shows a significant heterogeneity with

a broad range of cytological features. It usually exhibits a sheet-like infiltrate of small to large-sized cells with ample eosinophilic cytoplasm and clear perinuclear zone corresponding to prominent Golgi region. Nuclei are large with open chromatin pattern and prominent nucleoli. The characteristic morphological feature that presents in all variants of ALCL is the presence of so-called “hallmark cells” which exhibit a variety of appearances including eccentric, horseshoe, or kidney-shaped nuclei depending upon the plane of sectioning through a given cell.^[10-12,14,15] Other cell types that can be found include “doughnut cells” with central nuclear pseudoinclusions, immunoblastic cells, large pleomorphic cells that sometimes have nuclei with a “wreath-like” appearance, cells with bizarre nuclear shapes, multinucleated cells, and Reed-Sternberg cells-like cells.^[15] The neoplastic cells of ALCL tend to have perivascular distribution.^[10,16] Five morphological patterns

of ALCL have been recognized in the latest edition of the WHO classification, based on the cytological and the architectural features of the infiltrate. (I) The common pattern (60%–70%) is characterized by the predominance of large pleomorphic cells with admixed “hallmark cells” and “doughnut cells.” (II) The small cell pattern (5%–10%) exhibits small to medium-sized neoplastic cells with clear cytoplasm and distinct cell borders giving a “fried-egg” appearance. The nuclei are horseshoe-shaped or round. The typical “hallmark cells” are rare and tend to form perivascular rosettes. Interestingly, this pattern does not occur in ALK – ALCL.^[10] (III) The lymphohistiocytic pattern (10%) shows small neoplastic cells admixed with abundant histiocytes. It is closely related to the small cell pattern as they can appear intermixed in the same tumor. (IV) The Hodgkin-like pattern (3%) with morphological features resembles those of nodular sclerosis classic Hodgkin lymphoma. (V) The composite pattern (15%) is designated when more than one pattern can be seen in the same tumor.^[10-12,14,15] Other rare morphological patterns such as sarcomatoid, giant cell-rich, and signet-ring cell pattern are also recognized in the WHO classification.^[11,14] Pereira *et al.*^[17] have reported a case of sarcomatoid variant of ALCL that was ALK negative and was mimicking a PB cancer. The giant cell-rich pattern is characterized by the presence of numerous multinucleated giant cells in addition to large cells with pleomorphic bizarre nuclei, cells with “wreath-like” nuclear appearance, and Reed-Sternberg cells-like cells, similar to the histological findings in our case.^[15,18] The triple-negative subtype of ALCL often exhibits cells with very large pleomorphic nuclei with occasional “wreath-like” appearance. No reported cases of ALCL, giant cell-rich pattern involving the breast, other extranodal sites, or the lymph nodes were found in the literature. Other uncommon

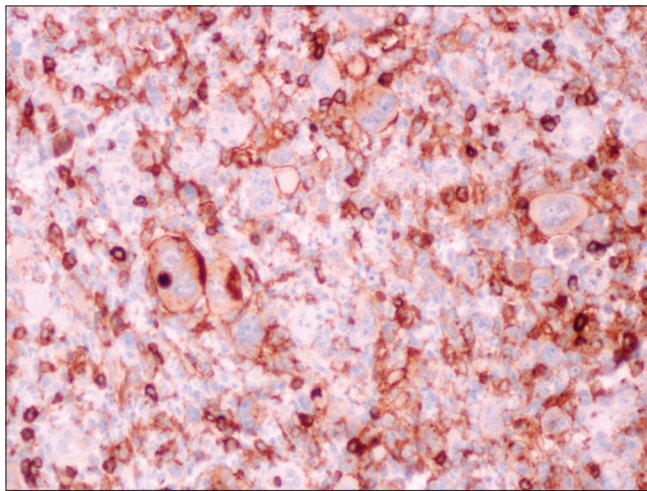


Figure 7: Immunohistochemical stain for CD4 shows diffuse membranous staining of tumor cells (original magnification ×200)

Table 1: The genetic and immunophenotypic characteristics of anaplastic large cell lymphoma types

ALCL type	Genetic profile	Immunophenotype	Negative prognostic markers
ALK + ALCL	t (2;5)(p23;q35) results in <i>NPM-ALK</i> gene fusion (80% of cases) ^[10]	CD30+, ALK+, EMA+, CD3-/+ , CD8-, CD4+/-, CD5+/-, CD7+/-, CD2+/-, CD15-, CD45 variable, CD45RO variable, *cytotoxic associated antigens+/-, MUM1+, BCL6-/+ , BCL2-[10,12,14-16]	CD56 ^[14,16] STAT3 activation ^[10,18] Survivin and SERPIN A-1 expression ^[10]
ALK – ALCL	Three genetic subtypes: i) <i>IRF4-DUSP22</i> -rearranged ALCL (30%) ii) <i>TP63</i> -rearranged ALCL (8%) iii) Triple-negative ALCL ^[10]	CD30+, ALK-, EMA+, CD3+/-, CD8-/+ , CD4+/-, CD5-/+ , CD7-/+ , CD2-/+ , CD15-, CD45 and CD45RO variable, *cytotoxic associated antigens +/- (except in <i>DUSP22</i> -rearranged cases where they are consistently -), MUM1+, BCL6-/+ , BCL2+[10,12,14-16]	CD56 ^[14,16] STAT3 activation ^[10,18]
BIA – ALCL	Activation of <i>JAK-STAT3</i> pathway Alterations of <i>ALK</i> , <i>DUSP22</i> , and <i>TP63</i> genes are absent (triple negative) ^[10,18]	CD30+, ALK-, EMA +, CD3-/+ , CD8-/+ , CD4+/-, CD5-/+ , CD7-/+ , CD2-/+ , CD15-, CD45+/-, *cytotoxic associated antigens-/+ , MUM1+, BCL6 N/A ^[10] , BCL2+[10,20]	N/A ^[10]

*Cytotoxic associated antigens such as TIA-1, Granzyme-B, perforin, and clusterin. +: Positive in >90% of cases, +/-: Positive in >50% of cases, -/+ : Positive in <50% of cases, -: Positive in <10% of cases, N/A: Not available, ALCL: Anaplastic large cell lymphoma, ALK: Anaplastic lymphoma kinase, BIA: Breast-implant associated, EMA: Epithelial membrane antigen, NPM: Nucleophosmin

patterns that are not recognized in the WHO classification and are described in several published case reports and reviews include alveolar growth pattern,^[19] neutrophil-rich pattern,^[16,19] hypocellular form, myxoid variant, and cases with exuberant granulomatous reaction.^[16] The genetic profile and the immunophenotypic features of the three types of ALCL are summarized in Table 1.

Conclusion

ALCL is an uncommon heterogeneous systemic disease with a spectrum of clinicopathological presentations, a wide range of morphological patterns, and variant genetic characteristics. It is important to recognize that all WHO subtypes of ALCL can involve the breast, including ALK-positive or ALK-negative ALCL. This type of T-cell lymphoma should be considered in evaluating breast tumors that show strong tumoral expression of CD30 immunohistochemical marker.

Acknowledgment

We would like to thank Mr. Mohammed AL-Juaed, the histotechnologist for his efforts in performing the immunohistochemical stains.

Declaration of patient consent

The authors certify that they have obtained all appropriate patient consent forms. In the form, the legal guardian has given his consent for images and other clinical information to be reported in the journal. The guardian understands that names and initials will not be published and due efforts will be made to conceal identity, but anonymity cannot be guaranteed.

Financial support and sponsorship

Nil.

Conflicts of interest

There are no conflicts of interest.

References

1. Raj SD, Shurafa M, Shah Z, Raj KM, Fishman MD, Dialani VM. Primary and secondary breast lymphoma: Clinical, pathologic, and multimodality imaging review. *Radiographics* 2019;39:610-25.
2. Thomas A, Link BK, Altekrose S, Romitti PA, Schroeder MC. Primary breast lymphoma in the United States: 1975-2013. *J Natl Cancer Inst* 2017;109 (6):djw294.
3. Zhang N, Cao C, Zhu Y, Liu P, Liu L, Lu K, *et al.* Primary breast lymphoma: A single center study. *Oncol Lett* 2017;13 (2):1014-8.
4. Picasso R, Tagliafico A, Calabrese M, Martinoli C, Pistoia F, Rossi A, *et al.* Primary and secondary breast lymphoma: Focus on epidemiology and imaging features. *Pathol Oncol Res* 2020;26:1483-8.
5. Wiseman C, Liao KT. Primary lymphoma of the breast. *Cancer* 1972;29:1705-12.
6. Talwalkar SS, Miranda RN, Valbuena JR, Routbort MJ, Martin AW, Medeiros LJ. Lymphomas involving the breast: A study of 106 cases comparing localized and disseminated neoplasms. *Am J Surg Pathol* 2008;32:1299-309.
7. Gualco G, Chioato L, Harrington WJ Jr., Weiss LM, Bacchi CE. Primary and secondary T-cell lymphomas of the breast: Clinic-pathologic features of 11 cases. *Appl Immunohistochem Mol Morphol* 2009;17:301-6.
8. Foo MY, Lee WP, Seah CM, Kam C, Tan SM. Primary breast lymphoma: A single-centre experience. *Cancer Rep (Hoboken)* 2019;2:e1140.
9. Wadhwa A, Senebouttarath K. Primary lymphoma of the breast: A case series. *Radiol Case Rep* 2018;13:815-21.
10. Montes-Mojarro IA, Steinhilber J, Bonzheim I, Quintanilla-Martinez L, Fend F. The pathological spectrum of systemic anaplastic large cell lymphoma (ALCL). *Cancers (Basel)* 2018;10:107.
11. Swerdlow SH, Campo E, Harris NL, Jaffe ES, Pileri SA, Stein H, *et al.* WHO Classification of Tumours of Hematopoietic and Lymphoid Tissues. 4th ed. Lyon: International Agency for Research on Cancer (IARC); 2017.
12. Hapgood G, Savage KJ. The biology and management of systemic anaplastic large cell lymphoma. *Blood* 2015;126:17-25.
13. Quintanilla-Martinez L. The 2016 updated WHO classification of lymphoid neoplasias. *Hematol Oncol* 2017;35 Suppl 1:37-45.
14. Tsuyama N, Sakamoto K, Sakata S, Dobashi A, Takeuchi K. Anaplastic large cell lymphoma: Pathology, genetics, and clinical aspects. *J Clin Exp Hematop* 2017;57:120-42.
15. King RL, Dao LN, McPhail ED, Jaffe ES, Said J, Swerdlow SH, *et al.* Morphologic features of ALK-negative anaplastic large cell lymphomas with DUSP22 rearrangements. *Am J Surg Pathol* 2016;40:36-43.
16. Falini B. Anaplastic large cell lymphoma: Pathological, molecular and clinical features. *Br J Haematol* 2001;114:741-60.
17. Pereira EM, Maeda SA, Reis-Filho JS. Sarcomatoid variant of anaplastic large cell lymphoma mimicking a primary breast cancer: A challenging diagnosis. *Arch Pathol Lab Med* 2002;126:723-6.
18. Oishi N, Miranda RN, Feldman AL. Genetics of breast implant-associated anaplastic large cell lymphoma (BIA-ALCL). *Aesthet Surg J* 2019;39:S14-20.
19. Yu G, Gao Z, Huang X. ALK-positive anaplastic large cell lymphoma with an unusual alveolar growth pattern. *Int J Clin Exp Pathol* 2014;7:9086-9.
20. Xu J, Wei S. Breast implant-associated anaplastic large cell lymphoma: Review of a distinct clinicopathologic entity. *Arch Pathol Lab Med* 2014;138:842-6.