

Diagnostic Accuracy of Magnetic Resonance Cholangiopancreatography to Detect Benign and Malignant Biliary Strictures

Abstract

Background: Magnetic resonance cholangiopancreatography (MRCP) is a noninvasive method to detect pancreaticobiliary strictures. In this study, we aimed to evaluate the diagnostic performance of MRCP and detect sensitive and specific radiologic features in distinguishing malignant and benign pathologies. **Materials and Methods:** In this study, 50 patients with biliary obstruction and a confirmed diagnosis using histopathology were included. The pathologies were evaluated using MRCP which were categorized into malignant and benign strictures. The etiology of strictures was detected using histopathology and endoscopic retrograde cholangiopancreatography. The diagnostic performance of MRCP was calculated using SPSS software. $P < 0.05$ was considered statistically significant. **Results:** Of 50 patients, 23 patients (46%) had malignant strictures based on MRCP and histopathology. The sensitivity and specificity of MRCP to detect malignancy were 95.7% and 96.3%, respectively. The most sensitive MRCP features to detect malignancy were upstream biliary duct dilation, abrupt tapering, and the presence of a solid mass with sensitivity 100%, 95.7%, and 78.2%, respectively. The malignancy rate was significantly higher in the strictures with length >11.5 mm or wall thickness >2.75 mm ($P < 0.05$). **Conclusion:** MRCP is a sensitive method to differentiate malignant lesions from benign pathologies. A long and thick stricture with the presence of a solid mass, upstream biliary duct dilation, and abrupt tapering is highly suggestive of malignancy.

Keywords: Biliary tract, Cholangiopancreatography, Magnetic Resonance, malignancy, pancreas

Introduction

Biliary obstruction has malignant and benign differential diagnosis. The most common cause of benign biliary obstruction is choledocholithiasis. However, cholangiocarcinoma, gallbladder carcinoma, or hepatocellular carcinoma are some causes of the malignant obstruction of biliary duct.^[1] Since both benign and malignant obstruction causes can lead to late complications, accurate and early detection of disease is so important. In patients with a suspicious biliary stricture, the gold standard method to differentiate malignant lesions from benign lesions is histopathology which is an expensive and invasive procedure. However, imaging can differentiate benign and malignant lesions using the morphologic features of strictures.^[2] Magnetic resonance cholangiopancreatography (MRCP) is a noninvasive technique which uses T2-weighted pulse sequences to detect pancreaticobiliary disorders. However, in

some cases, differentiating the etiology of stricture is difficult. Some benign strictures mimic malignant strictures by increasing wall thickness and obstructing the lumen.^[3,4]

There are some studies on the morphologic features of strictures in benign and malignant pathologies. Shorter, smoother, and symmetric strictures with tapered margin were more likely to have a benign cause.^[5] However, longer, thicker, asymmetric strictures with abrupt narrowing were suggestive of malignancy.^[6] However, the prognostic value of these features was not measured in these studies.

This study aimed to evaluate role of MRCP in differentiating the causes of strictures due to the radiologic features. Moreover, we aimed to detect the most sensitive and specific MRCP findings suggestive pancreaticobiliary malignancies.

Materials and Methods

It was a descriptive cross-sectional study which was performed from August 2018 to September 2019 on patients referred to

Niloufar Shabanikia,
Atoosa Adibi,
Shadi Ebrahimian

Department of Radiology,
Isfahan University of Medical
Sciences, Isfahan, Iran

Address for correspondence:

Dr. Shadi Ebrahimian,
Department of Radiology,
Isfahan University of
Medical Sciences, Hezar
Jerib Avenue, Isfahan, Iran.
E-mail: shadiebr2005@yahoo.com

Received: 07 June 2020
Revised: 13 January 2021
Accepted: 14 March 2021
Published: 26 November 2021

Access this article online

Website: www.advbiores.net

DOI: 10.4103/abr.abr_137_20

Quick Response Code:



How to cite this article: Shabanikia N, Adibi A, Ebrahimian S. Diagnostic accuracy of magnetic resonance cholangiopancreatography to detect benign and malignant biliary strictures. *Adv Biomed Res* 2021;10:38.

This is an open access journal, and articles are distributed under the terms of the Creative Commons Attribution-NonCommercial-ShareAlike 4.0 License, which allows others to remix, tweak, and build upon the work non-commercially, as long as appropriate credit is given and the new creations are licensed under the identical terms.

For reprints contact: WKHLRPMedknow_reprints@wolterskluwer.com

the MRI center of Al-ZahraHospital Isfahan University of Medical Sciences, Isfahan, Iran. Patients older than 18 years with biliary obstruction due to MRCP and a definite diagnosis using biopsy were included in the study. Individuals with poor quality of the images or the presence of more than one simultaneous mass in ducts were not included.

This study's aim was explained to all patients, and informed consent was signed by them. The ethical board of the Radiology Department of Radiology, Isfahan University of Medical Sciences, approved the study. MRCP was performed using a 1.5-T MRI scanner (Ingenia, Philips). MRCP protocol is shown in Table 1. Patients were fasted for 4 h before the study. No antiperistaltic agent was used.

Data collection including demographic information and imaging findings was done using designed forms. Imaging findings including length of stricture (in millimeter), asymmetrical or symmetrical narrowing, dilation of intrahepatic biliary radicle (IHBR), regular or irregular margin, abrupt or gradual tapering, partial or complete stricture, and presence or absence of other concomitant findings including mass, invasion to vessels, lymph node metastasis or organ spread, pancreatic parenchymal atrophy, and solid mass were recorded.

Irregular, long, asymmetric, or abrupt narrowing of the biliary and/or pancreatic duct were considered as malignant features. Besides, a narrow segment accompanied by solid mass, vascular and/or organ invasion, distal pancreatic parenchymal atrophy, distant metastases, or areas of low signal intensity in the pancreatic head on T1-weighted unenhanced images were considered as malignant stricture. Regular, short, and symmetric gradual tapering of the distal part of the duct with smooth contours and without total obstruction were used as the criteria for benignity.^[7]

A final report on the benignity or malignancy of narrowing lesions was reached by consensual agreement between two radiologists who were blinded to the final diagnosis of the patients.

The histopathology and endoscopic retrograde cholangiopancreatography (ERCP) were used as the gold standard to detect the diagnostic values of MRCP, including sensitivity, specificity, negative predictive value (NPV), and positive predictive value (PPV). A Chi-square test was used to analyze different MRCP features in malignant and benign pathologies. A threshold for stricture length and wall thickness was detected using receiver operating characteristic (ROC) curve analyses. All analyses were done by SPSS software (SPSS Inc., Chicago, IL, USA). $P < 0.05$ was considered statistically significant.

Results

Of 50 patients, 24 (48%) were female and 26 (52%) were male. History of the previous cholecystectomy was detected in 10 cases. Five patients had a history of non-pancreaticobiliary abdominal surgery. The most common site of strictures was the distal third of common bile duct (CBD) (19 cases). Other common locations were the porta hepatis (7 cases), the middle part of CBD (6 cases), the proximal part of CBD (4 cases), and the periampullary area (4 cases).

On MRCP, malignant appearing strictures were detected in 23 (46%) patients. Other 27 (54%) patients had benign appearing strictures using MRCP features. Histopathology revealed malignancy in 23 (46%) patients. 27 (54%) patients had benign mass using histopathology and ERCP findings as the gold standard. The most common etiologies of malignant strictures were pancreatic adenocarcinoma (39%) and cholangiocarcinoma (26%) [Figure 1]. Of 23 tumors with a definite malignancy diagnosis, 22 (95.7%) were correctly diagnosed on MRCP. Besides, MRCP could detect 26 of 27 (96.3%) benign lesions [Table 2]. The etiology of stricture in the patient with false-positive MRCP was postsurgical stricture.

The most common findings in MRCP were upstream biliary duct dilation (92%) and symmetrical dilation of the IHBR (86%). The frequency of other findings is shown in Table 3.

Table 1: Magnetic resonance imaging scan parameters

Parameters	BTFE axial	T2w SSH-SPIR axial	In/out axial	BTFE coronal	T2w SSH-SPIR coronal	SSH-MRCP rad	MRCP-3D
TR	3.3	12037	121	3.3	5799	8000	1942
TE	1.63	200	2.3	1.63	120	1039	600
Time of scan	19 s	24 s	20 s	25 s	12 s	1:36 m	18 s
Slice width	5	5	5	4	4	40	3
Number of sections	35	35	35	30	30	12	50
Field of view (mm)	371	371	371	377	377	300	350
Matrix size	196×176	184×170	152×109	188×207	172×152	288×266	240×155
Flip angle	90	90	80	90	90	90	90

MRCP: Magnetic resonance cholangiopancreatography, SSH: Single-shot, BTFE: Balanced turbo-field-echo, TR: Repetition time, TE: Time to echo

Irregular margin, abrupt tapering, the solid nature of the mass, invasion to surrounding tissue, presence of lymphadenopathy, upstream biliary duct dilation, and presence of duct penetrating sign were significantly more common in malignant tumors [Table 3]. Upstream biliary duct dilation, abrupt tapering, and solid mass presence were the most sensitive MRCP features in detecting malignancy with sensitivity 100%, 95.7%, and 78.2%, respectively [Table 4].

The mean of stricture length and wall thickness was 16.62 ± 12.51 and 4.36 ± 3.84 mm, respectively. Stricture length and wall thickness were significantly higher among patients with malignant tumors ($P < 0.05$). Using ROC curve analysis, malignancy was more frequent in strictures with length more than 11.5 mm ($P < 0.001$, area under the curve [AUC] = 0.88, 95% confidence interval [CI] = 0.79–0.97) and wall thickness more than

2.75 mm ($P < 0.001$, AUC = 0.98, CI = 0.95–1.00) [Figure 2]. Stricture length >11.5 mm was able to detect malignant lesions with a sensitivity of 87% and specificity of 75%. The sensitivity and specificity of wall thickness to detect the malignant lesions were 95% and 93%, respectively.

Discussion

This study was performed on 50 patients with abnormal MRCP and a confirmed diagnosis using histopathology and ERCP findings as the gold standard. The results of this study suggested MRCP as a sensitive and specific method to detect malignant strictures. Moreover, we found that among several radiologic features of strictures, margin irregularity, abrupt tapering, presence of solid mass, invasion to surrounding tissue, presence of lymphadenopathy, and upstream biliary duct dilation were more related to malignant lesions. Furthermore, stenosis length >11.5 mm and wall thickness >2.75 mm were more common among patients with malignant pathologies.

The reported sensitivity and specificity of MRCP to differentiate the benign and malignant lesions were 95.7% and 96.3%, respectively. The high sensitivity of MRCP to detect malignant strictures was reported in other studies.^[7,8] Suthar *et al.* reported a sensitivity of 85.7% and specificity of 96.3% for MRCP in detecting malignant strictures.^[7] Saxena *et al.*, in another study, found the sensitivity of 94%, the specificity of 94%, PPV of 97%, and NPV of 91%.^[9] Margin irregularity in MRCP for suggesting malignancy was reported in the study of Abdelrahman *et al.*^[10] However, they did not describe abrupt tapering as a cholangiographic criterion for malignancy diagnosis. Furthermore, in another study, abrupt ductal narrowing was seen in benign pathologies more commonly.^[11] This is

Table 2: Diagnostic performance of magnetic resonance cholangiopancreatography in differentiating malignant and benign lesions

MRCP finding	Histopathology finding		Total
	Malignant (%)	Benign (%)	
Malignant	22 (95.7)	1 (3.7)	23
Benign	1 (4.3)	26 (96.3)	27
Total	23	27	50

Sensitivity: TP/(TP + FN); Specificity: TN/(TN + FP).
MRCP: Magnetic resonance cholangiopancreatography, TP: True positive, FN: False negative, TN: True negative, FP: False positive

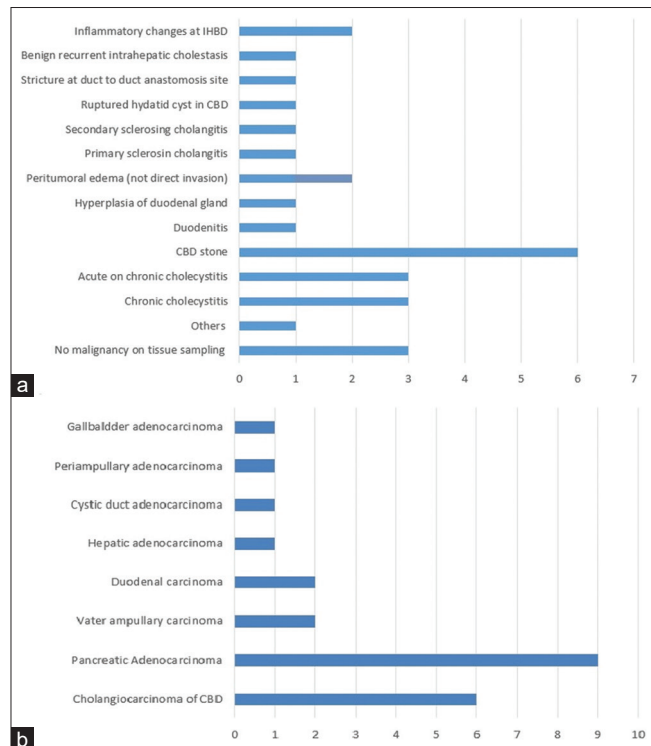


Figure 1: Frequency of benign (a) and malignant strictures' etiology (b) IHBD: Intrahepatic biliary duct, CBD: Common bile duct

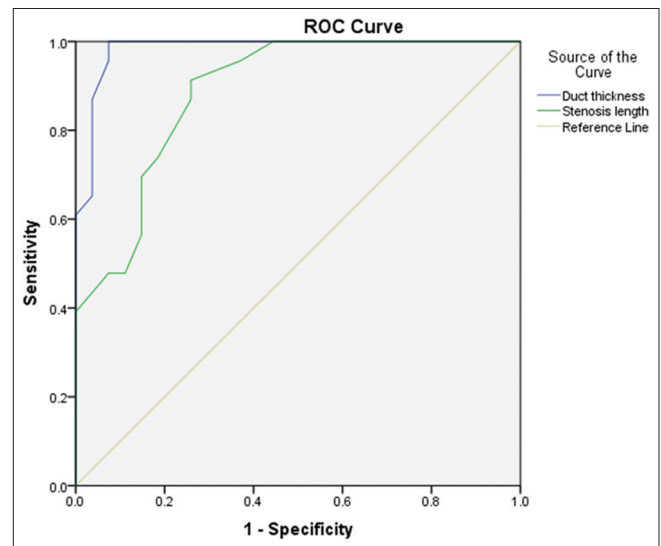


Figure 2: Receiver operating characteristic curve analysis for wall thickness and stenosis length in distinguishing malignant strictures from benign pathologies

while, in the present study, abrupt tapering was significantly more common among malignant lesions. Abrupt tapering was able to predict the malignancy with a sensitivity of 96% and specificity of 74%. Although it was not a specific criterion for malignancy and it was also present in benign lesions, abrupt tapering should be considered as a malignant MRCP feature.

In our study, the presence of a mass was highly suggestive of a malignant stricture. Since the most common growth pattern of intrahepatic cholangiocarcinoma is a mass formation, more investigations are needed if a mass is detected in MRCP. However, extrahepatic cholangiocarcinomas are more likely to grow in an

infiltrative pattern. Therefore, the absence of a mass does not rule out malignancy.^[12]

The results of this study showed a higher frequency of symmetrical dilation of IHBR among benign lesions than malignant strictures. However, the difference was not statistically significant ($P > 0.05$). Moreover, asymmetrical dilation of biliary radicals was reported as a related feature to malignancy in some studies which is not consistent with our results.^[7,13]

The correlation between the length and thickness of stricture and malignancy was reported in many studies. In a study performed by Yu *et al.*, the strictures were significantly thicker (4.4 mm) and longer (16.7 mm) in malignant lesions than benign pathologies.^[14] Strictures with long segment narrowing were more likely to have an infiltrative growth pattern.^[9] We detected a cutoff point 11.5 mm for the length of strictures which can predict the malignancy with a sensitivity of 87% and specificity of 75%. Furthermore, a wall thickness of more than 2.75 mm was highly suggestive of malignancy (sensitivity of 95% and specificity of 93%) in our study. Kim *et al.* also reported length <12 mm and thickness >3 mm as an indicator of malignancy which was similar to our results.^[15]

Furthermore, Yu *et al.* reported a larger dilation of the upstream CBD in malignant strictures (21 mm) than benign strictures (16 mm), suggesting this feature as an MRCP finding of malignancy.^[14] We measured the prognostic value of upstream dilation of the CBD and a sensitivity of 100% was detected. Although the sensitivity is high, the specificity was 15%, suggesting that the absence of upstream biliary duct dilation cannot rule out the malignancy.

In pancreatic duct stenosis, the absence of duct penetrating sign, the presence of complete stenosis, and the dilation of main or side branches of the pancreatic duct, were reported as a sign of adenocarcinoma.^[16] In our study, although all three cases with the presence of duct penetrating sign had malignancy and idiopathic pancreatitis was not diagnosed in any of them, the sensitivity of this feature was low. However, a specificity of 100% was reported which suggests the absence of duct penetrating sign as an imaging feature in ruling out benign etiologies of stricture. Moreover, we reported complete stenosis and dilation

Table 3: Frequency of different magnetic resonance cholangiopancreatography features of malignant and benign pancreaticobiliary strictures

Variable	Frequency (total=50), n (%)		P
	Malignant (total=23)	Benign (total=27)	
Asymmetrical narrowing	13 (34)	25 (66)	<0.001
Margin irregularity	12 (92)	1 (8)	<0.001
Tapering			
Abrupt	22 (79)	6 (21)	<0.001
Gradual	1 (6)	17 (94)	
Presence of solid mass	18 (90)	2 (10)	<0.001
Symmetrical dilation of IHBR	19 (42)	24 (58)	>0.05
Main pancreatic duct dilation before stenosis	6 (67)	3 (33)	>0.05
Complete blockage of the duct	15 (58)	11 (42)	>0.05
Pancreatic parenchymal atrophy	5 (71)	2 (29)	>0.05
Perihepatic fluid accumulation	7 (44)	9 (56)	>0.05
Invasion to surrounding tissue	12 (92)	1 (8)	<0.001
Distant metastasis	4 (80)	1 (20)	>0.05
lymphadenopathy	3 (100)	0	<0.05
Dilation of side branches of pancreatic duct	2 (40)	3 (60)	>0.05
Duct penetrating sign			
Present	3 (100)	0	<0.05
Absent	20 (42.6)	27 (57.4)	
Mural nodule	0	0	-
Upstream biliary dilation	23 (50)	23 (50)	<0.05

IHBR: Intrahepatic biliary radicles

Table 4: Diagnostic performance of magnetic resonance cholangiopancreatography features in detecting malignancy

Variable	Sensitivity (%)	Specificity (%)	TP	TN	FP	FN	PPV (%)	NPV (%)
Margin irregularity	52.1	96.2	12	26	1	11	92.3	70.2
Abrupt tapering	95.7	73.9	22	17	6	1	78.6	94.4
Solid mass	78.2	92.5	18	25	2	5	90	83.3
Invasion to surrounding tissue	52.1	96.2	12	26	1	11	92.3	70.3
Lymphadenopathy	13	100	3	27	0	20	100	57.4
Duct penetrating sign	13	100	3	27	0	20	100	57.4
Upstream biliary duct dilation	100	14.8	23	4	23	0	50	100

TP: True positive, TN: True negative, FP: False positive, FN: False negative, PPV: Positive predictive value, NPV: Negative predictive value

of the main pancreatic duct with a higher frequency in malignant strictures. However, the difference was not significant.

Nonenhancing mural nodule ≥ 10 mm was as a malignancy predictor of intraductal papillary mucinous neoplasm. Ultrasonography was reported as the best method for detecting mural nodules.^[17] However, MRCP was not sensitive enough in mural nodule detection.^[18] In the present study, no mural nodule was detected in the MRCP of participants. This may be due to the absence of intraductal papillary mucinous neoplasm as the etiology of pancreatic cancers or low sensitivity of MRCP in finding mural nodules.

Pancreatic parenchymal atrophy was detected with a higher frequency among patients with malignant lesions than benign pathologies. However, it was not statistically different. The results show that the atrophy of pancreatic parenchyma cannot be related to malignancy. In another study done on 178 patients, a high degree of pancreatic atrophy was not associated to the pancreatic ductal adenocarcinoma with intraductal papillary mucinous neoplasm.^[19] Since the degree of pancreatic parenchymal atrophy may vary among different types of cancers, more studies are needed to distinguish parenchymal changes in malignancies.

Conclusion

The results showed that the strictures with a length >11.5 mm and wall thickness >2.75 mm are highly suggestive for cholangiocarcinoma. We found upstream biliary duct dilation, abrupt tapering, and the presence of a solid mass as the most sensitive features. Lymphadenopathy, invasion to surrounding tissue, margin irregularity, and presence of a solid mass were the most specific findings to detect cholangiocarcinoma using MRCP. In addition, the absence of a duct penetrating sign was a specific radiologic feature in detecting pancreatic adenocarcinoma.

Acknowledgment

We would like to express our great thanks to Dr. Mohsen Hosseini because of his valuable consultation in doing the statistical analysis.

Financial support and sponsorship

The study was supported by Isfahan University of Medical Sciences.

Conflicts of interest

There are no conflicts of interest.

References

1. Fernandez Y, Viesca M, Arvanitakis M. Early diagnosis and management of malignant distal biliary obstruction: A review on current recommendations and guidelines. *Clin Exp Gastroenterol* 2019;12:415-32.
2. Rezvani M, Menias C, Sandrasegaran K, Olpin JD, Elsayes KM, Shaaban AM. Heterotopic pancreas: Histopathologic features, imaging findings, and complications. *Radiographics* 2017;37:484-99.
3. Oh I, Bates W, Estes T, Roda M, Moreno C, Mittal P. Benign and malignant biliary strictures: Diagnostic features from MRI and both diagnostic and therapeutic role of percutaneous intervention. *Eur Congr Radiol* 2019
4. Griffin N, Charles-Edwards G, Grant LA. Magnetic resonance cholangiopancreatography: The ABC of MRCP. *Insights Imaging* 2012;3:11-21.
5. Wang Y, Wang Y, Yang T, Chen Y. Value of Magnetic Resonance Cholangiopancreatography Combined with Dynamic Contrast Enhanced CT in Differential Diagnosis of Benign and Malignant Biliary Stricture; 2017;28;16.
6. Rajab L. Correlation of MRCP and Surgical Findings in Patients with Obstructive Jaundice at MNH: Muhimbili University of Health and Allied Sciences; 2017.
7. Suthar M, Purohit S, Bhargav V, Goyal P. Role of MRCP in differentiation of benign and malignant causes of biliary obstruction. *J Clin Diagn Res* 2015;9:TC08-12.
8. Dillman JR, Patel RM, Lin TK, Towbin AJ, Trout AT. Diagnostic performance of magnetic resonance cholangiopancreatography (MRCP) versus endoscopic retrograde cholangiopancreatography (ERCP) in the pediatric population: A clinical effectiveness study. *Abdom Radiol (NY)* 2019;44:2377-83.
9. Saxena S, Prajapati D, Doctor M, Patel H. Role of 3T magnetic resonance cholangiopancreatography (MRCP) in biliary strictures in adult population of western India. *Int J Sci Res* 2019;8:63-66.
10. Abdelrahman AS, Muhammed ZM. Role of magnetic resonance cholangio-pancreaticography in differentiating between benign and malignant causes of biliary obstruction. *Egypt J Hosp Med* 2017;68:954-66.
11. Katabathina VS, Dasyam AK, Dasyam N, Hosseinzadeh K. Adult bile duct strictures: Role of MR imaging and MR cholangiopancreatography in characterization. *Radiographics* 2014;34:565-86.
12. Lee WJ, Lim HK, Jang KM, Kim SH, Lee SJ, Lim JH, *et al.* Radiologic spectrum of cholangiocarcinoma: Emphasis on unusual manifestations and differential diagnoses. *Radiographics* 2001;21:S97-116.
13. Joo I, Lee JM, Yoon JH. Imaging diagnosis of intrahepatic and perihilar cholangiocarcinoma: Recent advances and challenges. *Radiology* 2018;288:7-13.
14. Yu XR, Huang WY, Zhang BY, Li HQ, Geng DY. Differentiation of infiltrative cholangiocarcinoma from benign common bile duct stricture using three-dimensional dynamic contrast-enhanced MRI with MRCP. *Clin Radiol* 2014;69:567-73.
15. Kim JY, Lee JM, Han JK, Kim SH, Lee JY, Choi JY, *et al.* Contrast-enhanced MRI combined with MR cholangiopancreatography for the evaluation of patients with biliary strictures: Differentiation of malignant from benign bile duct strictures. *J Magn Reson Imaging* 2007;26:304-12.
16. Boninsegna E, Manfredi R, Negrelli R, Avesani G, Mehrabi S, Pozzi Mucelli R. Pancreatic duct stenosis: Differential diagnosis between malignant and benign conditions at secretin-enhanced MRCP. *Clin Imaging* 2017;41:137-43.
17. Kawada N, Uehara H, Nagata S, Tsuchishima M, Tsutsumi M, Tomita Y. Mural nodule of 10 mm or larger as predictor of malignancy for intraductal papillary mucinous neoplasm of the pancreas: Pathological and radiological evaluations. *Pancreatology* 2016;16:441-8.
18. Uribarri-Gonzalez L, Keane MG, Pereira SP,

Iglesias-García J, Dominguez-Muñoz JE, Lariño-Noia J. Agreement among magnetic resonance imaging/magnetic resonance cholangiopancreatography (MRI-MRCP) and endoscopic ultrasound (EUS) in the evaluation of morphological features of Branch Duct Intraductal Papillary Mucinous

Neoplasm (BD-IPMN). *Pancreatology* 2018;18:170-5.

19. Yagi Y, Masuda A, Zen Y, Shiomi H, Toyama H, Sofue K, *et al.* Pancreatic inflammation and atrophy are not associated with pancreatic cancer concomitant with intraductal papillary mucinous neoplasm. *Pancreatology* 2018;18:54-60.