

A Very Rare Association of Fuchs Heterochromic Uveitis and Ectropion Uvea in Usher Syndrome

Abstract

Usher syndrome is a heterogeneous genetic disease that is the most common cause of hereditary blindness–deafness. This syndrome is the most prevalent syndrome associated with retinitis pigmentosa. A 25-year-old man referred to us with hearing loss and vision diminution since childhood which has gradually worsened. Visual acuity of both eyes was 20/100. Slit lamp examination of the left eye revealed endothelial stellate keratic precipitates, mild anterior chamber reaction, iris heterochromia, ectropion of uvea, and mild posterior subcapsular cataract. There were also no crypts and abnormal vessels in the left eye iris. His intraocular pressure was 14 mmHg in the right eye and 18 mmHg in the left one. Funduscopy demonstrated waxy pallor optic nerve, marked arterial narrowing, and retinal bone spicule pigment formation in both eyes. We report for the first time a very rare association between Usher syndrome, Fuchs heterochromic uveitis (FHU), and ectropion uvea. To our knowledge, no association has been reported between ectropion uvea, FHU, and Usher syndrome.

Keywords: Cataract, deafness, heterochromia iridis, iridocyclitis, retinitis pigmentosa, usher syndrome, uveitis

Introduction

Usher syndrome is a heterogeneous genetic disease that is inherited autosomal recessive and is the most common cause of hereditary blindness–deafness. The clinical symptoms of Usher syndrome include hearing loss, balance disorders, and loss of vision in the form of retinitis pigmentosa (RP).^[1] Furthermore, RP is a group of hereditary diseases that is known as retinal cell degeneration and has a classic triad called posterior segment RP findings that include mid peripheral bone spicules pigmentary degeneration, arterial narrowing, and a waxy pallor in the optic disc.^[2]

About 13 genes are involved in, with approximately half of the patients having mutations in the *USH2A* gene.^[3]

Usher syndrome consists of three types, classified by severity of symptoms and age of onset. Type 1 is the most severe type, characterized by severe deafness at birth and preadolescent visual disturbances, usually associated with vestibular disorders. Type 2 hearing disorders are milder and

vision disorders appear after puberty. Type 3 has the least prevalence and the onset of visual and auditory symptoms is variable.^[4,5]

Fuchs heterochromic uveitis (FHU) is a rare chronic nongranulomatous uveitis that is typically unilateral.^[6,7] It is characterized by stellate keratic precipitates, iris heterochromia, low-grade iridocyclitis, cataract, glaucoma, iris atrophy with or without nodules, vitreous opacification, and lack of posterior synechiae.^[8,9] Various etiologies for FHU have been mentioned, but infections with rubella virus, toxoplasmosis, and toxocariasis have recently been strongly debated.^[8,10]

Ectropion uvea is a rare anomaly defined by the appearance of the posterior iris pigment epithelium at its anterior surface. Information on the prevalence and incidence of this disorder is not known. Most of them are acquired and caused by traction of iris membranes due to other causes such as diabetic retinopathy, retinal vein obstruction, ocular ischemia, trauma, tumor, and intraocular surgery, but it also has congenital cases that are either singular or in association with anterior segment anomalies, such as coloboma

**Leila Rezaei,
Rashed Ahmadyani¹**

Associate Professor of Ophthalmology, Clinical Research Development Center, Imam Khomeini and Mohammad Kermanshahi and Farabi Hospitals, Kermanshah University of Medical Sciences, ¹Students Research Committee, Kermanshah University of Medical Sciences, Kermanshah, Iran

Address for correspondence:

*Dr. Leila Rezaei,
Department of Ophthalmology,
Clinical Research Development
Center, Imam Khomeini and
Mohammad Kermanshahi and
Farabi Hospitals, Kermanshah
University of Medical
Sciences, Kermanshah, Iran.
E-mail: leyla_rezaei60@yahoo.
com*

Received: 05 December 2020

Revised: 13 April 2021

Accepted: 26 April 2021

Published: 25 December 2021

Access this article online

Website: www.advbiores.net

DOI: 10.4103/abr.abr_286_20

Quick Response Code:



How to cite this article: Rezaei L, Ahmadyani R. A very rare association of fuchs heterochromic uveitis and ectropion uvea in usher syndrome. *Adv Biomed Res* 2021;10:50.

This is an open access journal, and articles are distributed under the terms of the Creative Commons Attribution-NonCommercial-ShareAlike 4.0 License, which allows others to remix, tweak, and build upon the work non-commercially, as long as appropriate credit is given and the new creations are licensed under the identical terms.

For reprints contact: WKHLRPMedknow_reprints@wolterskluwer.com

and ptosis, or in association with systemic diseases such as neurofibromatosis, Prader-Willi Syndrome, and Rieger anomaly.^[11-13] Acquired ectropion uvea is caused by the formation of a neovascular membrane, which usually results in iris atrophy and changes in the sphincter and dilator iris muscles. The congenital ectropion uvea (CEU) is typically unilateral and may be due to endothelial overactivity and/or late developmental arrest of neural crest cells. Unlike the acquired one, in CEU, the iris has a round, glassy, crypt-free appearance, and reactive to light.^[11]

In this paper, we report a very rare case of Usher syndrome associated with FHU and ectropion uvea.

Case Report

A 25-year-old man patient referred to the Ophthalmology Clinic of Imam Khomeini Hospital in Kermanshah presented with a chief complaint of exacerbated vision diminution. It should be noted that before writing the case report, a personal consent form was obtained from the patient. He has had hearing loss and vision diminution since childhood which has gradually worsened. The patient had normal speech and no impairment of balance. He had no other problem at past medical history. Visual acuity of both eyes was 20/100. Relative afferent pupillary defect was negative. Slit lamp examination of the left eye revealed endothelial stellate keratic precipitates [Figure 1], mild

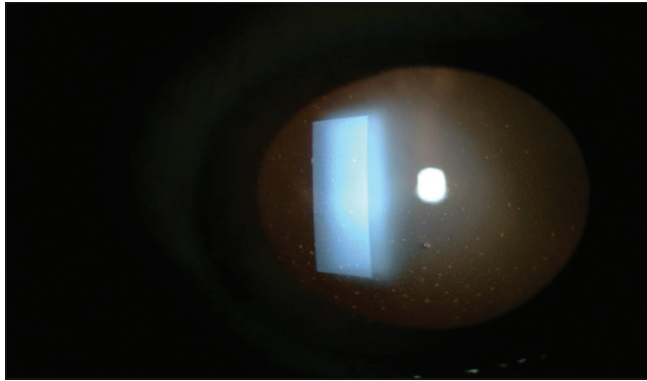


Figure 1: Retroillumination of the left eye that shows diffuse stellate keratic precipitates

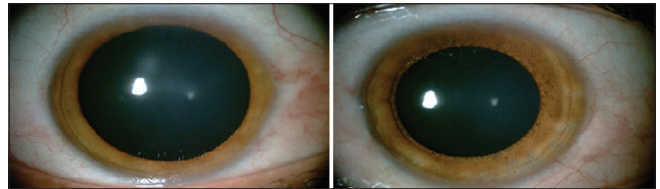


Figure 2: Color photograph of patient's eyes that show left iris heterochromia

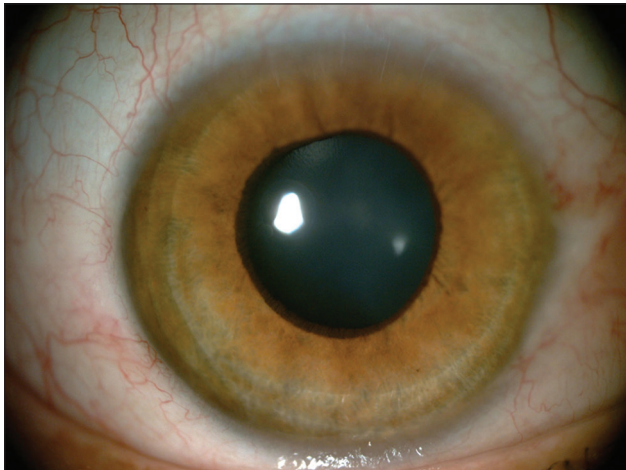


Figure 3: Color photograph of the left eye showing ectropion uvea

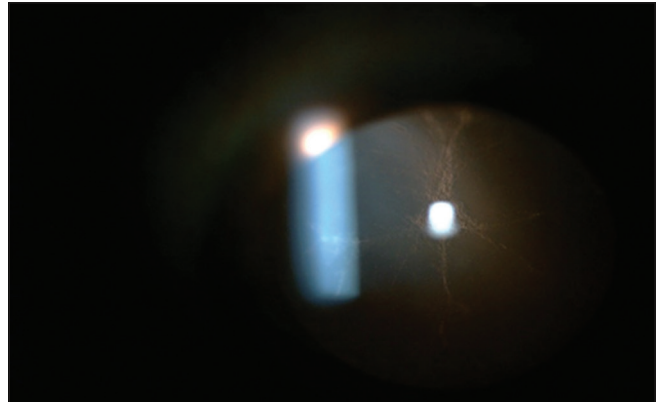


Figure 4: Retroillumination of the left eye shows posterior subcapsular cataract

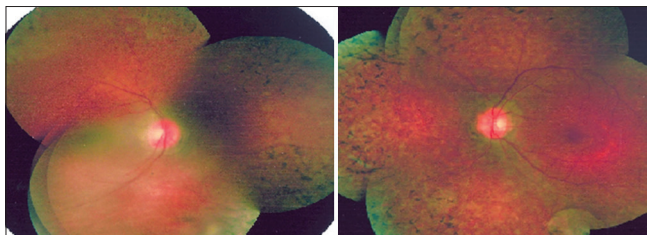


Figure 5: Montaged fundus photograph of both eyes that show waxy pallor optic nerve, marked arterial narrowing, and retinal bone spicule pigment formation with a normal macula

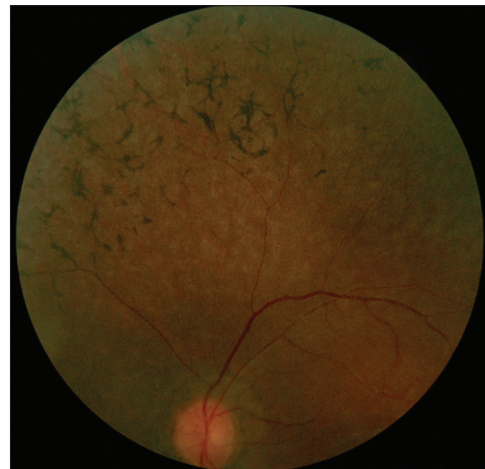

Figure 6: Peripheral of the left eye fundus showing retinal bone spicule pigment formation

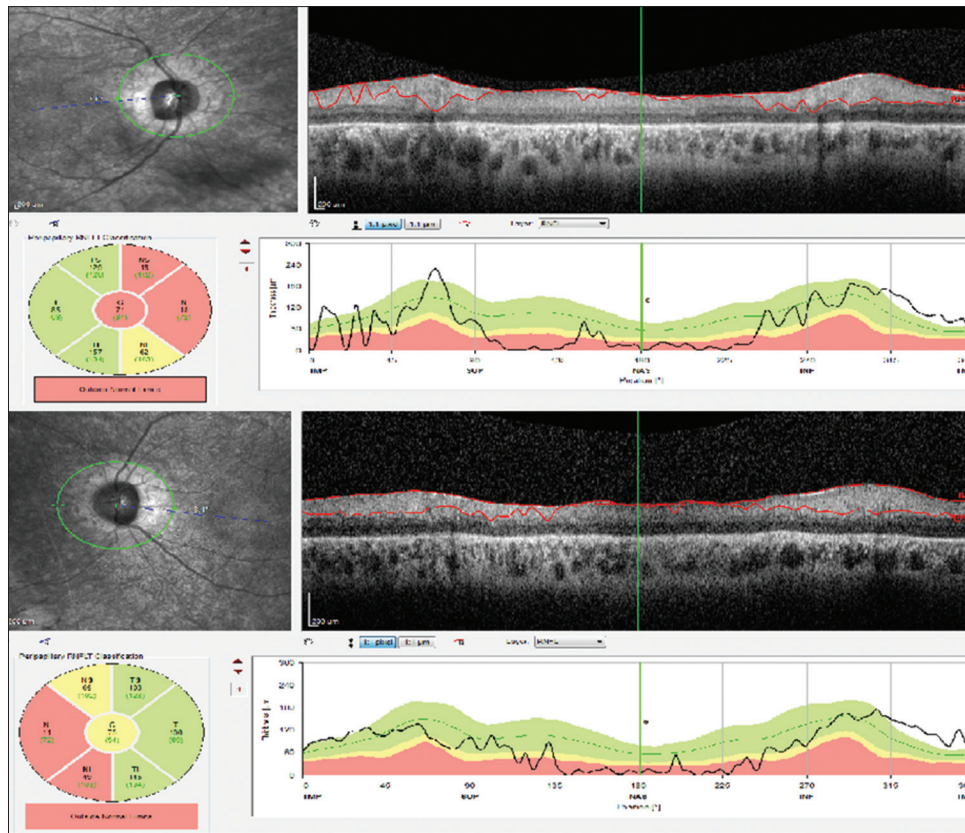


Figure 7: Bilateral optic nerve head OCT of patient demonstrates reduced volume and thickness in nasal area

anterior chamber reaction, iris heterochromia [Figure 2], ectropion of uvea [Figure 3], and mild posterior subcapsular cataract [Figure 4]. There were also no crypts and abnormal vessels in the left eye iris. Anterior segment of the right eye was normal. His intraocular pressure was 14 mmHg in the right eye and 18 mmHg in the left one. Funduscopy demonstrated waxy pallor optic nerve, marked arterial narrowing, and retinal bone spicule pigment formation in both eyes [Figures 5 and 6]. For patient bilateral optic nerve head, OCT was performed; OCT demonstrated reduced volume and thickness in the nasal area of optic nerve head in both eyes [Figure 7]. Due to hearing loss, audiometry and tympanography were performed. Audiometry revealed bilateral profound sensory neural hearing loss [Figure 8], and tympanogram showed type C [Figure 9]. Other physical examination was normal, and the patient's relatives were not involved. Based on these findings, we diagnosed Usher syndrome associated with FHU and ectropion uvea for the patient.

Discussion

Usher syndrome is a heredity autosomal recessive disease, there are various reports of the prevalence of it, but it is estimated at about 3 in 100,000.^[4] This syndrome is the most prevalent syndrome associated with RP and accounts for about 14% of cases of RP.^[14] FHU is a rare disorder that accounts for about 3% of uveitis, and its incidence in the

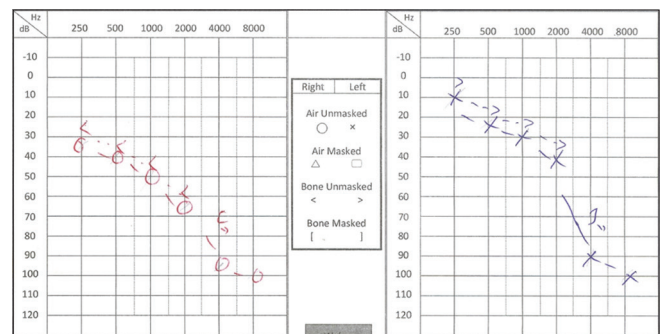


Figure 8: Audiometry of patient showing profound sensorineural hearing loss

general population is about 1 in 100,000.^[10] Furthermore, CEU is a rare anomaly defined by the appearance of the posterior iris pigment epithelium at its anterior surface at birth; information on the prevalence and incidence of this disorder is not known.^[13] Due to the low prevalence and incidence of these three anomalies, the occurrence of all three together is very rare. There have been numerous reports of a relationship between pigmented retinitis and FHU, but only three cases of the association between Usher syndrome and FHU have been reported.^[14,15] Furthermore, though there have been reports of ocular diseases in neural crest cell migration defects such as coloboma in Hirschsprung's disease^[16] and bilateral bicolored irides in Hirschsprung's disease,^[17] to our knowledge, no

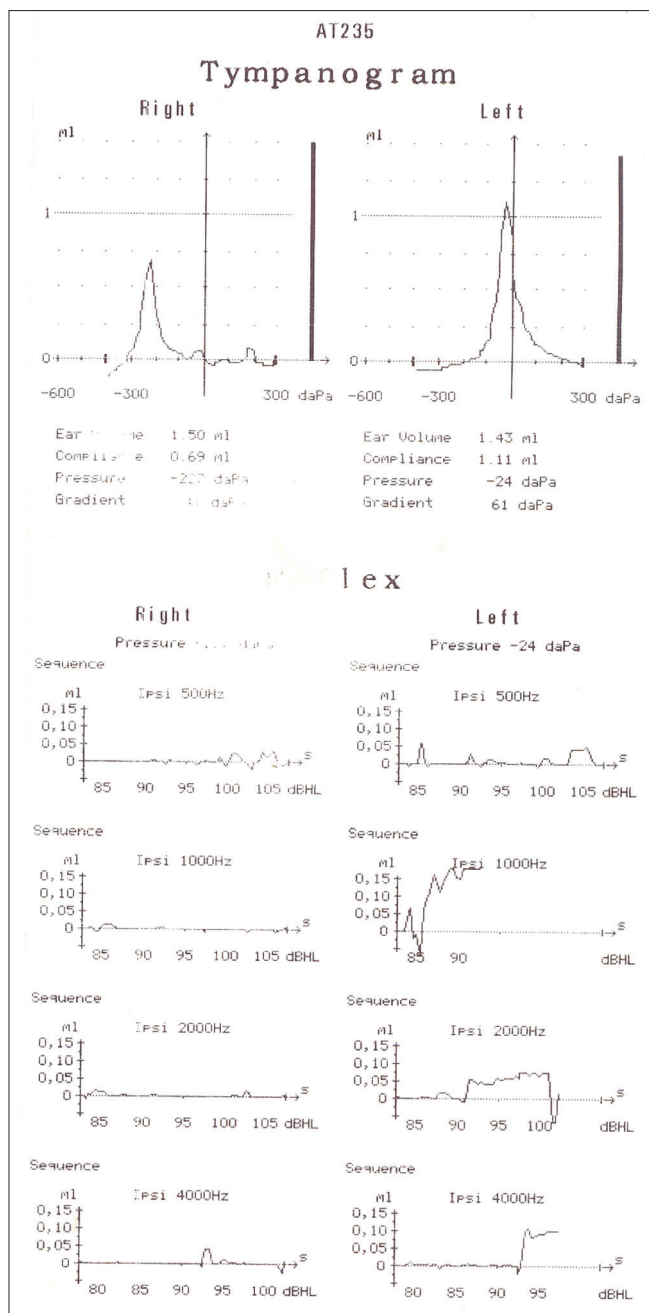


Figure 9: Tympanography of the patient showing Type C

association has been reported between ectropion uvea, FHU, and Usher syndrome to date. We report, for the first time, a very rare association between Usher syndrome, FHU, and ectropion uvea.

Retinal S antigens present in the retinal rod cells are responsible for inflammatory reactions in many uveitis and retinal diseases. Patients with pigmented retinitis have been shown to react with S antigens in cells A and B, which represent the inflammatory reactions of pigmented retinitis as well as Usher syndrome, which expresses their innate ability to convert to uveitis. S antigens are present in about 15% of patients with RP, whereas in patients with

Usher syndrome, this is 80%.^[4,14,18] All of these illustrate the association between Usher syndrome and FHU, which is related to inflammatory reactions. CEU is a rare nonprogressive condition for which hypotheses have been raised, including a failure of neural crest cell migration that leads to epithelial cell hyperplasia.^[11,19,20] The certain cause of the CEU and FHU is unclear, but both are typically unilateral, and there is iris involvement in both; glaucoma is also the most common CEU complication, accounting for about 80%–90% of cases, which is also seen in FHU.^[8,9,12,13]

Conclusion

Although the occurrence of these three anomalies may be coincidental, the existence of an inflammatory tendency in FHU and Usher syndrome, as well as a similar pattern of ocular involvement between CEU and FHU, suggests a common etiology. We hope that this case report will lead to a better understanding of the physiopathology and etiology of these disorders or be a trigger to detect a new syndrome.

Declaration of patient consent

The authors certify that they have obtained all appropriate patient consent forms. In the form the patient(s) has given his consent for his images and other clinical information to be reported in the journal. The patients understand that their names and initials will not be published and due efforts will be made to conceal their identity, but anonymity cannot be guaranteed.

Financial support and sponsorship

Nil.

Conflicts of interest

There are no conflicts of interest.

References

- Mathur P, Yang J. Usher syndrome: Hearing loss, retinal degeneration and associated abnormalities. *Biochim Biophys Acta* 2015;1852:406-20.
- Ilhan C, Citirik M. Glial proliferation and atrophy: Two poles of optic disc in patients with retinitis pigmentosa. *J Curr Ophthalmol* 2019;31:416-21.
- Fuster-García C, García-García G, González-Romero E, Jaijo T, Sequedo MD, Ayuso C, *et al.* USH2A gene editing using the CRISPR system. *Mol Ther Nucleic Acids* 2017;8:529-41.
- Benson MD, MacDonald IM. Bilateral uveitis and Usher syndrome: A case report. *J Med Case Rep* 2015;9:60.
- Slijkerman RW, Vaché C, Dona M, García-García G, Claustres M, Hetterschijt L, *et al.* Antisense oligonucleotide-based splice correction for USH2A-associated retinal degeneration caused by a frequent deep-intronic mutation. *Mol Ther Nucleic Acids* 2016;5:e381.
- Gohari M, Mehrjardi HZ, Jahanifard V. Implantation of Artisan lens in a patient with subluxated lens and Fuchs' heterochromic iridocyclitis. *J Case Rep* 2019;7:1-3.

7. Vallinayagam M, Anudeep K, Balla SC, Sahu J. Unilateral megalocornea associated with Fuchs' heterochromic iridocyclitis. *TNOA J Ophthalmic Sci Res* 2019;57:180.
8. Touhami S, Vanier A, Rosati A, Bojanova M, Benromdhane B, Lehoang P, *et al.* Predictive factors of intraocular pressure level evolution over time and glaucoma severity in Fuchs' heterochromic iridocyclitis. *Invest Ophthalmol Vis Sci* 2019;60:2399-405.
9. Jones NP. Fuchs' heterochromic uveitis: A reappraisal of the clinical spectrum. *Eye (Lond)* 1991;5:649-61.
10. Esfandiari H, Loewen NA, Hassanpour K, Fatourehchi A, Yazdani S, Wang C, *et al.* Fuchs heterochromic iridocyclitis-associated glaucoma: a retrospective comparison of primary Ahmed glaucoma valve implantation and trabeculectomy with mitomycin C. *F1000Research*. 2018;7.
11. Kolomeyer AM, Kim BJ. Bilateral, presumed congenital ectropion uveae in a patient with pathologic myopia. *Am J Ophthalmol Case Rep* 2018;11:119-20.
12. Shifa JZ, Nkomazana O, Bekele NA, Kassa MW. A young Botswana patient with congenital iris ectropion uvea. *Pan Afr Med J* 2016;25:42.
13. Wang GM, Thuente D, Bohnsack BL. Angle closure glaucoma in congenital ectropion uvea. *Am J Ophthalmol Case Rep* 2018;10:215-20.
14. Turan-Vural E, Torun-Acar B, Tükenmez N, Sevim MŞ, Buttanri B, Acar S. Usher syndrome associated with Fuchs' heterochromic uveitis: A case report. *Clin Ophthalmol* 2011;5:557-9.
15. Lichtinger A, Chowers I, Amer R. Usher syndrome associated with Fuchs' heterochromic uveitis. *Graefes Arch Clin Exp Ophthalmol* 2010;248:1481-5.
16. Hurst JA, Markiewicz M, Kumar D, Brett EM. Unknown syndrome: Hirschsprung's disease, microcephaly, and iris coloboma: A new syndrome of defective neuronal migration. *J Med Genet* 1988;25:494-7.
17. Liang JC, Juarez CP, Goldberg MF. Bilateral bicolored irides with Hirschsprung's disease. A neural crest syndrome. *Arch Ophthalmol* 1983;101:69-73.
18. McMurtrey JJ, Tso MO. A review of the immunologic findings observed in retinitis pigmentosa. *Surv Ophthalmol* 2018;63:769-81.
19. Kumari R, Saha BC. Congenital ectropion uveae with glaucoma: A case report. *Int Ophthalmol* 2018;38:2623-6.
20. Kianersi F, Rezaei L, Ghanbari H, Dehghani A. Central serous chorioretinopathy following kidney transplantation. *Saudi J Kidney Dis Transpl* 2014;25:615-20.