

Ultra-Widefield Fundus Fluorescein Angiography Findings in Patients with Fuchs' Uveitis Syndrome

Abstract

Background: The aim of this study was to evaluate ultra-widefield (UWF) fundus fluorescein angiography (FFA) findings in patients with Fuchs' uveitis syndrome (FUS). **Materials and Methods:** This cross-sectional study was conducted in patients with FUS. All the patients underwent a complete ophthalmologic examination, and FFA was carried out with Optos UWF retinal imaging. Standard FFA and image acquisition consisted of early phase (15–45 s) images, and late-phase (5–10 min) images were also obtained for both eyes. **Results:** Forty eyes from twenty unilateral FUS patients, including 11 females (55%), who had a mean age of 38.50 ± 6.97 years, were enrolled. Eighty-five percent of the FUS eyes had optic disc hyperfluorescence (ODH) in the FFA. A significant relationship was observed between ODH and iris heterochromia ($P = 0.004$). ODH was seen in all the patients with iris heterochromia ($n = 16$). Peripheral vascular leakage (PVL), capillary nonperfusion, chorioretinal scar, and vascular sheathing were observed in 3, 3, 2, and 8 of the patients' eyes, respectively. **Conclusion:** UWF FFA imaging seemed to be mandatory for evaluating the prognosis of the FUS patients, and another investigation may require to be conducted to evaluate the effect of antivascular endothelial growth factor agents for the management of PVL in these patients.

Keywords: Diagnostic imaging, Fluorescein Angiography, iris diseases, uveitis

Introduction

Fuchs' uveitis syndrome (FUS) is a chronic inflammatory ocular condition characterized by an asymptomatic inflammatory process.^[1,2] The classic clinical findings in FUS are stellate keratic precipitates, iris atrophy with or without heterochromia, mild flare and minimal cells in the anterior chamber, and vitreous involvement.^[2-4]

With the development of imaging systems in ophthalmology in the past years, a link has been identified between posterior segment involvement and FUS.^[5-9] For example, in a study by Kardes *et al.*,^[1] choroidal thinning has been observed in eyes with FUS, probably due to the inflammatory processes at play. Furthermore, some studies showed that optic disc hyperfluorescence (ODH) and peripheral vascular leakage (PVL) can be identified in patients with FUS.^[2-4] These findings in the posterior segment revealed that FUS might be associated with inflammation involving the posterior segment.^[6,7]

This is an open access journal, and articles are distributed under the terms of the Creative Commons Attribution-NonCommercial-ShareAlike 4.0 License, which allows others to remix, tweak, and build upon the work non-commercially, as long as appropriate credit is given and the new creations are licensed under the identical terms.

For reprints contact: WKHLRPMedknow_reprints@wolterskluwer.com

Peripheral retina is an important element in the effective diagnosis and management of retinal diseases. Currently, with the advances in fundus imaging and technologies and the improvements in the utilization of ultra-widefield (UWF) imaging in the evaluation of the far periphery of the posterior segment, our understanding of pathologic findings about various vitreoretinal disorders has improved.^[5,6] UWF can be defined as a single-capture image centered on the fovea that captures retinal anatomical features anterior to the vortex vein ampulla in all four quadrants.^[7,8] One of the current UWF imaging systems involves the use of an Optos camera. This camera was the first UWF imaging system and produces a 200° view of the retina, equal to about 82% of the surface area.^[5,9,10] The multimodal Optos system is now capable of performing fundus fluorescein angiography (FFA).

There are limited data about peripheral retina fundoscopic and FFA findings in patients with FUS. The present study was therefore conducted to evaluate the findings

How to cite this article: Nasrollahi K, Fazel F, Mirjani T, Kianersi F, Fazel M, Pourazizi M. Ultra-widefield fundus fluorescein angiography findings in patients with Fuchs' uveitis syndrome. *Adv Biomed Res* 2022;11:1.

Kobra Nasrollahi,
Farhad Fazel,
Taha Mirjani,
Farzan Kianersi,
Mohammadreza
Fazel,
Mohsen Pourazizi

Isfahan Eye Research Center,
Department of Ophthalmology,
Isfahan University of Medical
Sciences, Isfahan, Iran

Address for correspondence:

Dr. Farhad Fazel,
Isfahan Eye Research Center,
Department of Ophthalmology,
Isfahan University of Medical
Sciences, Isfahan, Iran.
E-mail: fazel@med.mui.ac.ir

Received: 23 December 2020

Revised: 05 January 2022

Accepted: 16 January 2022

Published: 31 January 2022

Access this article online

Website: www.advbiores.net

DOI: 10.4103/abr.abr_305_20

Quick Response Code:



of UWF FFA and their applications to clinical practice in FUS.

Materials and Methods

Participants

This cross-sectional study was conducted at the academic referral center for the diagnosis and management of uveitis at Isfahan University of Medical Sciences (IUMS), which is one of the main centers for the treatment of uveitis in Iran, between November 2018 and September 2019. The study protocol was approved by the Ethics Committee of IUMS in Isfahan, Iran (IR.MUI.MED.REC.1398.495). The study protocol was explained to all the patients, and informed consent was obtained from them before entering the study.

Consecutive cases of unilateral FUS aged above 18 years after an ocular and systemic evaluation included the study. The patients who were pregnant or had a history of retinal or macular abnormalities, ocular trauma, laser photocoagulation, and/or intraocular surgery (except cataract surgery) were excluded from the study. The diagnosis of FUS was based on clinical signs^[11] including unilateral anterior uveitis, absence of acute symptoms, typical KPs, absence of synechia, iris atrophy and heterochromia, posterior subcapsular cataract, glaucoma, and absence of cystoid macular edema. If there was any suspicion to viral causes of uveitis including herpes, more objective test such as polymerase chain reaction of aqueous was requested.

Study protocol and Optos fundus fluorescein angiography

All the patients underwent a complete ophthalmologic examination including distance best-corrected visual acuity (BCVA), manifest refractions, slit-lamp biomicroscopy, and funduscopy. The UWF FFA was carried out with Optos UWF retinal imaging (Optos PLC, Dunfermline, UK). Five milliliters of 10% sodium fluorescein were administered via the antecubital vein for FFA. Standard FFA and image acquisition consisted of early phase (15–45 s) images, and late-phase (5–10 min) images were also obtained for both eyes. Venous staining and vascular leakage were investigated in the optimal image from the late phase at minute 5.

The retinal vascular leakage identified was classified as either peripheral leakage, posterior pole leakage, diffuse leakage (both the peripheral retina and posterior pole), or no leakage. The peripheral retina was defined as the region from the equator to the ora serrata. Optic nerve hyperfluorescence was investigated in the late-phase images at minute 5.

Statistical analysis

Descriptive statistics were used to summarize the patients' characteristics. The results were reported as

mean \pm standard deviation for the quantitative variables and as percentages for the categorical variables. Fisher's exact test and the independent sample *t*-test were used to examine possible relationships between clinical characteristics and other fundus parameters. BCVA was transformed into the logarithm of the minimum angle of resolution (LogMAR) for the statistical analysis. Data were analyzed in SPSS (version 22) software (Statistical Procedures for the Social Sciences, Chicago, Illinois, USA). *P* < 0.05 was considered significant in all the tests.

Results

Forty eyes from twenty patients with unilateral FUS were examined. The mean age of the patients was 38.50 ± 6.97 years, and there were 11 females (55%) among them. The chief complaint of most patients was floaters (75%). Vitritis was seen in all the patients. Small-to medium-sized stellate KPs and iris heterochromia were noted in 19 (95%) and 16 (80%) eyes, respectively. Table 1 presents the patients' demographics and clinical findings [Table 1].

Eighty-five percent of the FUS eyes had ODH in the FFA [Figure 1]. Capillary nonperfusion (CNP) was noted in three eyes [Figure 1] including in one eye with FUS and in two of the unaffected eyes of the patients. The fundal examination revealed chorioretinal scar in two patients.

Table 1: The demographic and clinical characteristics of the patients

Variable	n (%)
Age	
Mean \pm SD	38.50 \pm 6.97
Median (minimum-maximum)	39 (25-52)
Sex	
Male	9 (45)
Female	11 (55)
Laterality	
Right	10 (50)
Left	10 (50)
BCVA	
$\geq 6/18$	15 (75)
6/18-6/60	3 (15)
6/60-3/60	2 (10)
IOP	
Mean \pm SD	14.10 \pm 3.21
Median (minimum-maximum)	14 (10-21)
Slit lamp examination	
Iris heterochromia	16 (80)
Vitritis	20 (100)
KP	19 (95)
PSCC	13 (65)
PCIOL	4 (20)

BCVA: Best-corrected visual acuity, IOP: Intra-ocular pressure, KP: Keratic precipitate, PSCC: Posterior subcapsular cataract, PCIOL: Posterior chamber intraocular lens, SD: Standard deviation

The chorioretinal scar was found in one eye with FUS and in the unaffected eye of the other patient [Figure 2]. Eight eyes with FUS showed vascular sheathing [Figure 3], and PVL was noted in three eyes [Figure 4].

Table 2 presents the relationships between the fundus findings in FUS and variables including age, BCVA LogMAR, gender, and iris heterochromia. A significant relationship was also observed between ODH and iris heterochromia ($P = 0.004$). ODH was seen in all the patients with iris heterochromia ($n = 16$) [Table 3].

A significant relationship was found between PVL and the BCVA LogMAR ($P < 0.001$). The mean BCVA LogMAR was higher in the eyes with PVL (1.1 ± 0.1 in the FUS with PVL vs. 0.35 ± 0.18 in the FUS without PVL) [Table 3]. In addition, the mean BCVA LogMAR of the eyes with vascular sheathing was higher and marginally significant (0.62 ± 0.38 in the FUS with vascular sheathing vs. 0.36 ± 0.23 in the FUS without vascular sheathing; $P = 0.06$) [Table 3].

Discussion

Our study showed that ODH was the most common FFA finding in FUS. There was a significant relationship between ODH and iris heterochromia, and ODH was observed in all the patients with iris heterochromia. Other findings regarding the posterior segment included PVL, CNP, chorioretinal scar, and vascular sheathing.

To the best of our knowledge, this is the first study conducted to evaluate FFA findings through UWF imaging in patients with FUS. A number of studies reported that UWF FFA shows new peripheral pathologies in many diseases that could not have been detected through other clinical examinations and conventional FFA.^[5,12]

In this study, we used UWF imaging for FUS. The peripheral findings that may sometimes be missed using standard angiography can be detected by UWF imaging, thus facilitating more precise diagnosis.^[12] We found CNP and PVL in the peripheral fundus findings of the FUS patients. The information regarding the far periphery of the retina and vascular leakage in FUS obtained by FFA can be integral to the management of FUS. The FFA showed PVL in 15% of our patients. Other studies have reported the rate of PVL as 12.5%–60%^[2-4,13] In agreement with the results of other studies, the present findings using UWF imaging indicate that subclinical retinal involvement may be a feature of FUS. The significant relationship between PVL and BCVA in the present study was mainly due to the role of inflammation in affected eyes. The chorioretinal scar was seen at fundus examination in two eyes but never presented as a pathological hyperfluorescence on FFA. These may be the result of an old injury and incidental findings.

The reported ODH rate varied between 22% and 97.7%.^[2-4,13] ODH was seen in 85% of the patients in the

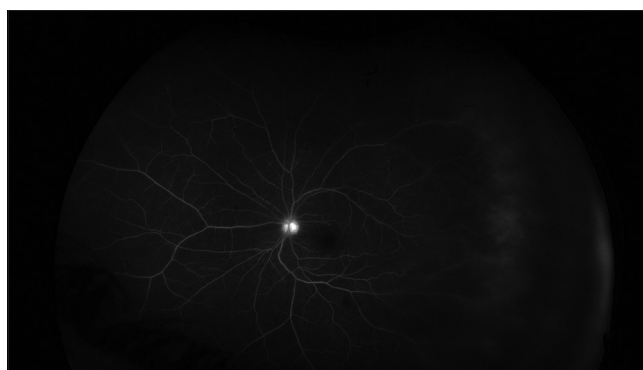

Figure 1: Ultra-widefield fundus fluorescein angiography showed retinal capillary nonperfusion and optic disc hyperfluorescence in a patient with unilateral Fuchs' uveitis syndrome

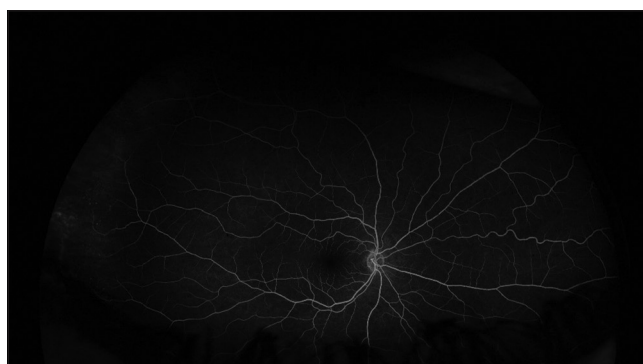

Figure 2: Ultra-widefield fundus fluorescein angiography showed chorioretinal scar in a patient with unilateral Fuchs' uveitis syndrome

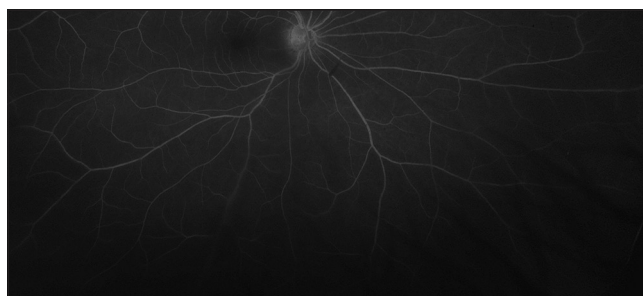

Figure 3: Ultra-widefield fundus fluorescein angiography showed vascular sheathing in a patient with unilateral Fuchs' uveitis syndrome

Table 2: Fundus finding of the patients

Fundus findings	n (%)
Optic disc hyperfluorescence	17 (85)
Peripheral vessel leakage	3 (15)
Vascular sheathing	8 (40)
Capillary non-perfusion	3 (15)
Chorioretinal scar	2 (10)

present study. Similarly, high rates have been reported in some previous studies.^[2,3,13] The high frequency of ODH in FFA could be due to the inflammatory breakdown of the blood-ocular barrier, similar to the blood-aqueous barrier breakdown shown in iris FFA studies.^[14-16] Mechanical traction by a heavily infiltrated vitreous proximal to the

Table 3: Relationships between the fundus findings in Fuchs' uveitis syndrome and variables including age, best-corrected visual acuity logarithm of the minimum angle of resolution, gender and iris heterochromia

Fundus findings	Age		BCVA LogMAR		Sex			Iris heterochromia		
	Mean±SD	P*	Mean±SD	P*	Male, n (%)	Female, n (%)	P**	Yes, n (%)	No, n (%)	P**
ODH										
Yes	38.35±7.50	0.82	0.49±0.34	0.07	6 (35.3)	11 (64.7)	0.07	16 (94.1)	1 (5.9)	0.004
No	39.33±3.05		0.3±0.1		3 (100)	0 (0)		0 (0)	3 (100)	
Vascular sheathing										
Yes	40.75±7.55	0.24	0.62±0.38	0.06	4 (50)	4 (50)	0.99	6 (75)	2 (25)	0.99
No	37.00±6.43		0.36±0.23		5 (41.7)	7 (58.3)		10 (83.3)	2 (16.7)	
PVL										
Yes	39.33±10.6	0.82	1.1±0.1	<0.001	0 (0)	3 (100)	0.21	3 (100)	0 (0)	0.49
No	38.35±6.6		0.35±0.18		9 (52.9)	8 (47.1)		13 (76.5)	4 (23.5)	

*Independent sample *t*-test, **Fisher's exact test. SD: Standard deviation, ODH: Optic disc hyperfluorescence, PVL: Peripheral vascular leakage, BCVA: Best-corrected visual acuity, LogMAR: Logarithm of the minimum angle of resolution

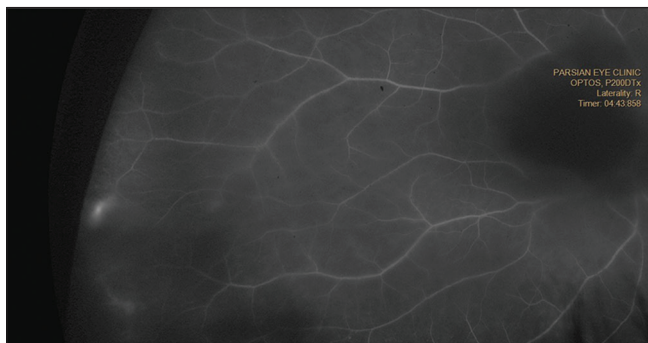


Figure 4: Ultra-widefield fundus fluorescein angiography showed peripheral vascular leakage in a patient with unilateral Fuchs' uveitis syndrome

optic disc could be one of the secondary hypothetical mechanisms explaining ODH in FUS.^[3] Nonetheless, Bouchenaki and Herbot noticed that a pronounced ODH can be found even in a very slightly infiltrated vitreous.^[3]

The incorporation of FFA, optical coherence tomography (OCT), OCT angiography, and additional imaging technologies may improve the diagnosis and management of FUS. Recent studies demonstrated that FUS affects not only the anterior uvea and vitreous but also the retinal microvasculature and the peripapillary total retinal and nerve fiber layer in FUS eyes.^[12,17,18] These findings regarding FUS suggest that FUS might be associated with inflammation involving the whole uvea.

Iris heterochromia was noticed in 80% of the patients in the present study. In addition, ODH was seen in all the patients with iris heterochromia in a significant manner. Heterochromia is one of the important manifestations of FUS, caused by inflammation in the iris stroma and the loss of the iris-pigmented epithelium.^[19-21] The significant relationship between ODH and iris heterochromia in the present study suggests the role of inflammation in both anterior and posterior segments in FUS. It seems that inflammation occurring in the anterior uveitis also involves the optic disc.

The importance of the present study lies in its provision of new evidence about posterior involvement in FUS. The limitations of the study include the relatively small sample size; therefore, the present findings need to be confirmed in large prospective studies. Although cataract surgery potentially can affect FFA findings due to postoperation inflammation, but this effect usually occurs in acute phase of postsurgical period. In our study, due to limitation of patient's selection, the patients with cataract surgery postchronic phase were not excluded from the study.

Conclusion

UWF imaging is useful in patients with FUS, which have the potential to evaluate of peripheral fundus lesions for FUS and another investigation may require to be conducted to evaluate the effect of antivascular endothelial growth factor agents for the management of PVL in these patients. Further long-term studies with larger cases are now needed to evaluate whether or not peripheral vascular pattern changes and the presence of leakage at angiography in the long-term are important.

Financial support and sponsorship

Nil.

Conflicts of interest

There are no conflicts of interest.

References

- Kardes E, Sezgin Akçay BI, Unlu C, Ergin A. Choroidal thickness in eyes with Fuchs uveitis syndrome. *Ocul Immunol Inflamm* 2017;25:259-66.
- Aziz S, Arya B, Westcott M, Pavesio C. An investigation of the disc hyperfluorescence in Fuchs uveitis syndrome using optical coherence tomography imaging. *Ocul Immunol Inflamm* 2015;23:152-6.
- Bouchenaki N, Herbot CP. Fluorescein angiographic findings and clinical features in Fuchs' uveitis. *Int Ophthalmol* 2010;30:511-9.
- Yang P, Fang W, Jin H, Li B, Chen X, Kijlstra A. Clinical features of Chinese patients with Fuchs' syndrome. *Ophthalmology*

- 2006;113:473-80.
5. Callaway NF, Mruthyunjaya P. Widefield imaging of retinal and choroidal tumors. *Int J Retina Vitreous* 2019;5:49.
 6. Choudhry N, Golding J, Manry MW, Rao RC. Ultra-widefield steering-based spectral-domain optical coherence tomography imaging of the retinal periphery. *Ophthalmology* 2016;123:1368-74.
 7. Kato Y, Inoue M, Hirakata A. Quantitative comparisons of ultra-widefield images of model eye obtained with Optos((R)) 200T×and Optos((R)) California. *BMC Ophthalmol* 2019;19:115.
 8. Choudhry N, Duker JS, Freund KB, Kiss S, Querques G, Rosen R, *et al.* Classification and Guidelines for Widefield Imaging: Recommendations from the International Widefield Imaging Study Group. *Ophthalmol Retina* 2019;3:843-9.
 9. Hirano T, Imai A, Kasamatsu H, Kakihara S, Toriyama Y, Murata T. Assessment of diabetic retinopathy using two ultra-wide-field fundus imaging systems, the Clarus® and Optos™ systems. *BMC Ophthalmol* 2018;18:332.
 10. Xu A, Chen C. Clinical application of ultra-widefield fundus autofluorescence. *Int Ophthalmol* 2022;41:727-41.
 11. Kimura SJ, Hogan MJ, Thygeson P. Fuchs' syndrome of heterochromic cyclitis. *AMA Arch Ophthalmol* 1955;54:179-86.
 12. Patel SN, Shi A, Wibbelsman TD, Klufas MA. Ultra-widefield retinal imaging: an update on recent advances. *Ther Adv Ophthalmol* 2020;12:2515841419899495.
 13. Tugal-Tutkun I, Güney-Tefekli E, Kamaci-Duman F, Corum I. A cross-sectional and longitudinal study of Fuchs uveitis syndrome in Turkish patients. *Am J Ophthalmol* 2009;148:510-50.
 14. Norrsell K, Holmér AK, Jacobson H. Aqueous flare in patients with monocular iris atrophy and uveitis. A laser flare and iris angiography study. *Acta Ophthalmol Scand* 1998;76:405-12.
 15. Zarei M, KhaliliPour E, Ebrahimiadib N, Riazi-Esfahani H. Quantitative analysis of the iris surface smoothness by anterior segment optical coherence tomography in Fuchs uveitis. *Ocul Immunol Inflamm.* 2020; 1-6. DOI: 10.1080/09273948.2020.1823424.
 16. Zarei M, Ebrahimiadib N, Riazi-Esfahani H. Using anterior segment optical coherence tomography to compare the smoothness of anterior iris surface between two eyes in unilateral Fuchs' uveitis syndrome. *Graefes Arch Clin Exp Ophthalmol* 2019;257:2799-800.
 17. Aksoy FE, Altan C, Basarir B, Garip D, Pasaoglu I, Perente I, *et al.* Analysis of retinal microvasculature in Fuchs' uveitis syndrome. *Retinal microvasculature in Fuchs' uveitis. J Fr Ophtalmol* 2020;43:324-9.
 18. Zarei M, Abdollahi A, Darabeigi S, Ebrahimiadib N, Roohipoor R, Ghassemi H, *et al.* An investigation on optic nerve head involvement in Fuchs uveitis syndrome using optical coherence tomography and fluorescein angiography. *Graefes Arch Clin Exp Ophthalmol* 2018;256:2421-7.
 19. Mohamed Q, Zamir E. Update on Fuchs' uveitis syndrome. *Curr Opin Ophthalmol* 2005;16:356-63.
 20. Bonfioli AA, Curi AL, Orefice F. Fuchs' heterochromic cyclitis. *Semin Ophthalmol* 2005;20:143-6.
 21. Moshirfar M, Villarreal A, Ronquillo Y. Fuchs uveitis syndrome. In: *StatPearls. Treasure Island (FL): StatPearls Publishing Copyright© 2020, StatPearls Publishing LLC; 2020.*