

Case Report

Parsonage-Turner Syndrome following COVID-19 Infection: A Rare and Unique Case

Abstract

Parsonage-Turner syndrome (PTS) is a rare syndrome of unknown etiology; however, it is believed that an abnormality of immune response after a previous infection may be the cause of the disease. We report neuralgic amyotrophy in a patient with a history of kidney transplantation with severe acute respiratory distress syndrome coronavirus 2 infection. This literature is reviewed regarding clinical presentation, etiology, treatment, and prognosis of PTS after COVID-19 infection. We should consider PTS as another complication of COVID-19 infection.

Keywords: *Brachial plexus neuritis, COVID-19, Parsonage-Turner syndrome*

Introduction

Although severe acute respiratory distress syndrome coronavirus 2 (SARS-CoV-2) (COVID-19) is a novel entity characterized mainly by respiratory symptoms, and multiorgan dysfunction such as neurological symptoms is in a critical condition. Both central and peripheral nervous system (CNS and PNS) disorders have been reported following COVID-19. Damage to the CNS or PNS, such as Guillain-Barre syndrome, could be caused by the virus directly or by the body's immune responses to the infection.^[1]

We report a case of upper trunk brachial plexopathy in a patient following laboratory-confirmed infection with SARS-CoV-2.

Case Report

Our patient was a 54-year-old male who had a medical history of kidney failure due to polycystic kidney disease. In January 2020, the patient had a kidney transplant as a treatment for his end-stage renal disease. To maintain the transplanted kidney, the patient has received strong immunosuppressives, such as prednisolone, tacrolimus, and mycophenolate mofetil. In September 2020, the patient was admitted to Alzahra Hospital (a major referral hospital

affiliated with Isfahan University of Medical Sciences) with fever, coryza, and signs of lower respiratory tract infection. He tested positive for COVID-19 RNA using nasopharyngeal swabs. He was treated with levofloxacin, nasal O₂ supplement, and dexamethasone due to an O₂ saturation <94%, as per the local protocol for the management of moderate-to-severe COVID-19. After 5 days, the patient's condition exacerbated. Remdesivir was administered for his high fever and progressive ground-glass opacity in the lung [Figure 1]. After 1 week, he showed improvement and was discharged. Five days after leaving the hospital, the patient was re-admitted after several days of experiencing severe pain in his left scapular region, followed by proximal left upper limb weakness. He described his pain as diffuse and dull along the cervical spine and medial scapula. A prompt neurologic examination revealed proximal left upper limb muscle weakness with intact distal muscle strength. Reductions were observed in the elevation, abduction, and external rotation of the left shoulder. Deep tendon reflexes were absent in the left biceps. The examination also revealed sensory deficit in the lateral arm and forearm. Cervical and brachial plexus magnetic resonance imaging (MRI) was performed without gadolinium (due to the kidney transplant). There was a slight C3–C4 disc herniation, and the plexus MRI was

**Behnaz Ansari^{1,2},
Alireza Eishi
Oskouei^{3,4}, Firouzeh
Moeinzadeh⁵**

¹Isfahan Neuroscience Research Center, Alzahra Research Institute, Isfahan University of Medical Sciences, ²Department of Neurology, Isfahan University of Medical Sciences, ³Department of Neurology, Neuroscience Research Center, Isfahan University of Medical Sciences, ⁴Medical Student Research Center, Isfahan University of Medical Sciences, ⁵Isfahan Kidney Diseases Research Center, Isfahan University of Medical Sciences, Isfahan, Iran

Address for correspondence:

Dr. Firouzeh Moeinzadeh, Isfahan Kidney Diseases Research Center, Isfahan University of Medical Sciences, Isfahan, Iran.
E-mail: f_moinzade@med.mui.ac.ir

Received: 15 June 2021
Revised: 20 September 2021
Accepted: 09 October 2021
Published: 31 January 2022

Access this article online

Website: www.advbiores.net

DOI: 10.4103/abr.abr_167_21

Quick Response Code:



How to cite this article: Ansari B, Eishi Oskouei A, Moeinzadeh F. Parsonage-Turner syndrome following COVID-19 infection: A rare and unique case. *Adv Biomed Res* 2022;11:7.

This is an open access journal, and articles are distributed under the terms of the Creative Commons Attribution-NonCommercial-ShareAlike 4.0 License, which allows others to remix, tweak, and build upon the work non-commercially, as long as appropriate credit is given and the new creations are licensed under the identical terms.

For reprints contact: WKHLRPMedknow_reprints@wolterskluwer.com

otherwise normal. An electromyography (EMG) nerve conduction velocity was performed for the patient, which showed that his sensory radial and median nerves were reduced [Table 1]. The motor conduction study was normal. In the needle EMG, spontaneous activity was detected in the left biceps, deltoid, supraspinatus, and rhomboid muscles, and upper trunk brachial plexopathy was reported. The evaluation of vasculitis, including antinuclear antibody, antineutrophil cytoplasmic antibody, complement assay, and infections was all normal. Therefore, based on the patient's clinical features and after ruling out similar diseases, a diagnosis of brachial amyotrophy or Parsonage-Turner syndrome (PTS) was confirmed. We treated our patient with an increased dose of oral prednisolone (25 mg) for 3 weeks followed by tapering. At the follow-up visit 21 days after the initiation of the treatment, he reported partial improvement in his strength. At the 2-month follow-up, the patient's shoulder examination showed normal results without pain or functional limitations.

After completion of treatment, he received anti-COVID vaccine, Sinopharm, inactivated virus vaccine, Wuhan, China, and recurred symptoms 2 weeks after completion of vaccination. We decided to add IVIg for him.

Discussion

PTS is an acute neuropathy affecting the brachial plexus or its branches that is characterized by pain, followed by muscle weakness, amyotrophy, and

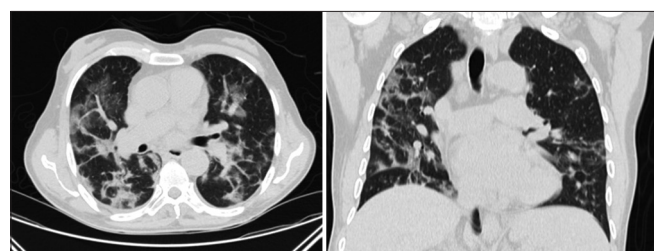


Figure 1: The chest computed tomography revealed ground-glass opacity in both lungs

sensory abnormality. The etiopathogenesis of PTS remains unknown, but it is believed that an abnormality of the immune response after previous infection may be the cause of the disease. The most common triggering factor for the occurrence of PTS seems to be viral illness, with the most common virus being hepatitis E virus, which has been reported in 10% of the cases.^[2]

Our case of upper trunk plexopathy following infection with COVID-19 points to the possible association of PTS with COVID-19 infection. Some cases of autoimmune neuropathy, such as Guillain-Barre and Miller-Fisher syndrome, with COVID-19 infection were reported that are frequently postinfectious process,^[3] but neurologic amyotrophy linked to the activation of the immune system with COVID-19 has been reported in only two case reports.^[4,5]

Whether PTS was mediated in our patient by the direct viral infection of the plexus or was a consequence of autoimmune responses following infection with COVID-19 remains ambiguous, but the clinical course of development of PTS after COVID-19 is more in favor of the autoimmune response.

Our case highlights the importance of considering PTS as another complication of COVID-19 infection.

Conclusion

To the best of the researchers' knowledge, this is the third reported case of PTS following COVID-19 infection. It is therefore important to consider a possible association between PTS and COVID-19 as another morbidity caused by this virus.

Ethical approval and consent to participate

The patient agreed to the proposed diagnostic and therapeutic plan and signed the informed consent and all the necessary permits according to the Declaration of Helsinki and current Ukrainian legislation. Approval was obtained from an Ethics Committee in Isfahan University of Medical Sciences, approval ID, IR.MUI.MED.REC.1399.686.

Table 1: The nerve conduction study results

Variable	Left median nerve	Left ulnar nerve	Left radial
Sensory			
SNAP amplitude (μ V)	16.5 (≥ 20)	17 (≥ 17)	5.2 (≥ 15)
Velocity (m/s)	58.5 (≥ 50)	50.1 (≥ 50)	55.2 (≥ 50)
Motor			
Distal latency (ms)	4.4 (≤ 4.4)	3.1 (≤ 3.5)	2.6 (≤ 3.1)
CMAP distal amplitude (mv)	13.9 (≥ 4)	9.5 (≥ 6)	12.3 (≥ 2)
CMAP proximal amplitude (mv)	13 (≥ 4)	8.4 (≥ 6)	12 (≥ 2)
Velocity (m/s)	62.5 (≥ 49)	62.5 (≥ 49)	46.4 (≥ 49)
F-latency (ms)	25 (≤ 32)	32 (≤ 32)	

The data in brackets represent reference values used in the NCV. CMAP: Compound muscle action potential, SNAP: Sensory nerve action potential, NCV: Nerve conduction study

Declaration of patient consent

The authors certify that they have obtained all appropriate patient consent forms. In the form, the patient has given his consent for his images and other clinical information to be reported in the journal. The patient understand that name and initials will not be published and due efforts will be made to conceal identity, but anonymity cannot be guaranteed.

Financial support and sponsorship

Nil.

Conflicts of interest

There are no conflicts of interest.

References

1. Ellul MA, Benjamin L, Singh B, Lant S, Michael BD, Easton A, *et al.* Neurological associations of COVID-19. *Lancet Neurol* 2020;19:767-83.
2. Seror P. Neuralgic amyotrophy. An update. *Joint Bone Spine* 2017;84:153-8.
3. Alberti P, Beretta S, Piatti M, Karantzoulis A, Piatti ML, Santoro P, *et al.* Guillain-Barré syndrome related to COVID-19 infection. *Neurol Neuroimmunol Neuroinflamm* 2020;7:e741.
4. Siepmann T, Kitzler HH, Lueck C, Platzek I, Reichmann H, Barlinn K. Neuralgic amyotrophy following infection with SARS-CoV-2. *Muscle Nerve* 2020;62:E68-70.
5. Cacciavillani M, Salvalaggio A, Briani C. Pure sensory neuralgic amyotrophy in COVID-19 infection. *Muscle Nerve* 2021;63:E7-8.