

## Bone Densitometry and Fat Index after Sleeve and Subleeve Gastrectomy in Animal Model

### Abstract

**Background:** Previous studies have reported that gastrectomy and fundectomy can induce osteopenia. Body fat index is a new index of obesity that shows central obesity and other risks of obesity. Sleeve gastrectomy (SG) is a bariatric surgery and a new technique introduced as subleeve, which only resected fundus of the stomach. In this study, it has been shown the effect of subleeve and SG on fat index and bone densitometry in an animal model. **Materials and Methods:** Rabbits were underlined SG, fundectomy (surgical removal of fundus), or sham-operated (controls without any resection), and after 12 weeks, fat index and bone densitometry were obtained. **Results:** Our study showed that there was no significant difference between SG and fundectomy groups in bone mass density and fat mass after surgery in comparison with presurgery condition. SG group were associated with lower fat index and bone density, and it showed significantly decrease in weight after 1.5 months. **Conclusion:** Sub-SG did not show any significant effect on fat index and bone densitometry in comparison with SG. However, we found lower fat index in sleeve group of rabbits, but it was not statistically significant.

**Keywords:** Body mass index, densitometry, gastrectomy, morbid obesities, rabbits

### Introduction

However, sleeve gastrectomy (SG) may have different short-and long-term postoperative complications such as weight loss, disturbed nutrition intake, anemia, abnormal digestion, and absorption. Sub-SG is a new experimental technique that has been introduced recently. Its effectiveness is not clarified yet. Osteopenia is assessed after gastrectomy in experimental animals and humans.<sup>[1,2]</sup> Previous reports have described the bone tissue in the men represented a significant decrease of volumetric bone mineral density (up to 16.8% within the trabecular and 10.0% in cortical bone compartments of lumbar spine) after total gastrectomy.<sup>[2]</sup>

Overweight and obesity are the abnormal and high levels of fat accumulation in the body that endanger people's health in many ways and are considered a public health difficult situation worldwide.<sup>[3]</sup> Since 1975 thus far, obesity has nearly tripled.<sup>[4]</sup>

Recent studies have shown that body mass index (BMI) itself could be a strong predictor of overall mortality.<sup>[5]</sup> Attempts

toward losing weight are unsuccessful in several patients.<sup>[6]</sup> Bariatric surgery is a referral surgery for morbid obesity that is performed for at least 6–12 months after failing medical treatment and causes rapid weight loss.<sup>[7]</sup> According to European guidelines on obesity management, bariatric surgery is recommended in patients with a BMI >50 kg/m<sup>2</sup> or those with a BMI ≥35 who have concomitant disease (such as psychological, dermatologic, orthopedic, cardiopulmonary, endocrine, and metabolic diseases).<sup>[7]</sup> Surgical interventions to treat morbid obesity can be divided into two groups, including surgeries that limit gastric volume (such as adjustable gastric bandage and SG) and surgeries that reduce absorption (such as gastric bypass or biliopancreatic path deviation).<sup>[8]</sup> Mid-term and long-term studies have shown that weight loss using bariatric surgery methods can cause nutrient and micronutrient deficiencies and decreased bone mineral density (BMD).<sup>[9]</sup> Digestion of micronutrients such as calcium, Vitamin D, and essential proteins are also reduced. Rapid weight loss by reducing bone mechanical susceptibility can contribute to bone mass loss.<sup>[10]</sup> Bone mass loss after

Hajar Khazraei<sup>1</sup>,  
Seyed Vahid  
Hosseini<sup>1</sup>,  
Masood Amini<sup>2</sup>,  
Saeed Amirzadeh<sup>3</sup>,  
Amirreza  
Dehghanian<sup>4</sup>,  
Zahra Sobhani<sup>2</sup>,  
Hengameh  
Kasraei<sup>1,5</sup>

<sup>1</sup>Colorectal Research Center, Shiraz University of Medical Sciences, <sup>2</sup>Laparoscopic Research Center, Shiraz University of Medical Sciences, <sup>3</sup>Gastroenterology Research Center, Shiraz University of Medical Sciences, <sup>4</sup>Molecular Pathology and Cytogenetics Division, Shiraz University of Medical Sciences, <sup>5</sup>General Physician Faculty of Medicine, Student Research Committee, Shiraz University of Medical Sciences, Shiraz, Iran

### Address for correspondence:

Prof. Masood Amini,  
Laparoscopic Research  
Center, Shiraz University of  
Medical Sciences, Shiraz, Iran.  
E-mail: [amini.mas2018@gmail.com](mailto:amini.mas2018@gmail.com)

Received: 31 May 2020  
Revised: 11 October 2020  
Accepted: 19 April 2021  
Published: 29 June 2022

### Access this article online

Website: [www.advbiores.net](http://www.advbiores.net)

DOI: 10.4103/abr.abr\_124\_20

### Quick Response Code:



**How to cite this article:** Khazraei H, Hosseini SV, Amini M, Amirzadeh S, Dehghanian A, Sobhani Z, et al. Bone densitometry and fat index after sleeve and subleeve gastrectomy in animal model. *Adv Biomed Res* 2022;11:48.

This is an open access journal, and articles are distributed under the terms of the Creative Commons Attribution-NonCommercial-ShareAlike 4.0 License, which allows others to remix, tweak, and build upon the work non-commercially, as long as appropriate credit is given and the new creations are licensed under the identical terms.

For reprints contact: [WKHLRPMedknow\\_reprints@wolterskluwer.com](mailto:WKHLRPMedknow_reprints@wolterskluwer.com)

bariatric surgeries, which has been mostly in the proximal part of the femur bone, has been reported in several studies.<sup>[11]</sup>

Low BMI is additionally a crucial risk factor for osteoporosis, and moderate overweight and obesity is a protective issue for the development of osteoporosis. On the other hand, some studies have shown that morbid obesity (BMI > 35) has adverse effects on bone formation.<sup>[12]</sup> Research has shown that patients undergoing bariatric surgery are at increased risk of secondary hyperparathyroidism and decreased BMD.<sup>[13]</sup> There seems to be a direct relationship between the percentage of bone loss and the rate of weight loss.<sup>[14]</sup>

It is troublesome to interpret bone condensation leads to the rapid weight loss phase due to technical errors related to reduce subcutaneous fat thickness. Since the second year after gastric bypass surgery, measuring of BMD has been the gold standard for assessing bone status.<sup>[15]</sup>

In the SG procedure, 70%–75% of the gastric capacity decreased, but sub-SG might be more conservative<sup>[16]</sup> because we hypothesized that only removing the gastric fundus did not have effect on bone loss. Therefore, we tested a new surgical procedure called sub-SG in obese rabbits. The new procedure was evaluated by comparing the body weights, fat index, and bone density among rabbits after 3 months. We decided to evaluate its effects on body fat index and bone densitometry.

## Materials and Methods

Fifteen male New Zealand White rabbits were obtained from Animal Laboratory, Shiraz University of medical sciences, Shiraz, Iran. The rabbits were maintained in individual cages under standard conditions (temperature, humidity, and light) with free access to standard food and tap water.

Rabbits were divided into weight-matched groups (BMI approximately 10). Finally, 15 rabbits divided in three groups ( $n = 5$ ): SG ( $2657.5 \pm 208.0$  g), fundus resection ( $2936.0 \pm 142.5$  g), and controls (sham-operated) ( $3133.3 \pm 221.5$  g) were included in this study. Control animals (sham-operated) were given the same amount of food eaten by the surgical groups, in order to measure the weight-loss effects of surgeries.

All procedures were approved by the Ethics Committee of Animal Research in Shiraz University of Medical Sciences.

### Surgical procedures

After 48 h fasting, rabbits were anesthetized with IM injection of ketamine (50 mg/kg) and xylazine (10 mg/kg). As prophylactic therapy, piperacillin (0.4 g/ml/kg) through IM injection was administered immediately after surgery and 3 following days.

In the SG, first, a 1.5-cm upper midline incision was made, then the stomach was externalized, and scissors were used

to remove approximately 90% of the forestomach. The excised part was then sutured with 4-0 nonadsorbable polypropylene suture (Prolene, Ethicon). To perform the fundectomy, first, a 1.5-cm upper midline incision was made, then the stomach was externalized, and fundus of gastric curvature excised and sutured by 4-0 nonabsorbable polypropylene suture (Prolene, Ethicon). For the sham-operated groups, after making an incision, the stomach was externalized, manipulated, and then returned to the abdomen. Abdomen then closed by using 4-0 adsorbable coated polyglactin (Vicryl, Ethicon) followed by 4-0 adsorbable coated polyglactin (Vicryl Rapid, Ethicon) for the skin.

Rabbits were returned to their home cages, and they were restricted to only water–sugar diet on the first postoperative day and for 3 following days placed on milk and multi-vitamin (5 drops/500 cc milk), and afterward, all animals had access to standard rabbit food until the end of the trial.

Before and after surgery bodyweight of all rabbits was recorded. Whole-body composition reference values involving fat, lean, and bone from each rabbit were determined after 3 months and compared between three groups (HOLOGIC discovery Wi (S/N88108), version 13.4.2. Inc., Bedford, MA, USA). After measurements, the rabbits were sacrificed, and the different parts of their bodies were used for autopsy. Histopathology evaluation of the affected parts of their body was done.

### Statistical analysis

Results are shown as means  $\pm$  standard error mean. Kruskal–Wallis test was used for comparison of the means between the groups, and  $P < 0.05$  was considered to be statistically significant.

## Results

Rabbits in fundectomy and control groups displayed body weight gain after 3 months, but it was not statistically significant [ $P > 0.05$ ; Figure 1]. There was no difference in relative body fat content, assessed by the percentage of body fat index among the three groups of rabbits [Table 1]. The weight of rabbits in subsleeve group became stable after 3 months. Figure 2 shows the sleeve and subsleeve surgery.

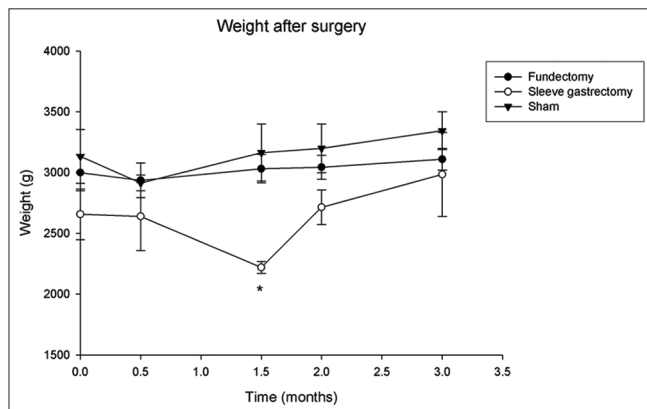
Body fat was not significantly different after 3 months among different groups ( $P > 0.05$ ). Fat weight was also lower in rabbits submitted to SG compared with controls.

### Pathologic findings

After measurements, the rabbits were sacrificed and the different parts of their bodies were used for histopathological study. Pathologic findings after 3 months showed that in fundectomised rabbits, gastric mucosal congestions were found in three of the rabbits. Histopathology sections of

**Table 1: Results of body fat index in rabbits 3 months after surgery (dual energy X-ray absorptiometry results summary)**

Groups	Height (cm)	Bone mass content (g)	Fat mass (g)	Lean mass (g)	Total mass (g)	Percentage fat	Bone mass density (g/cm <sup>3</sup> )
Fundectomy	51.25±2.4	89.96±4.34	818.37±99.68	2221.6±52.99	3129.95±147.64	25.87±2.0	0.37±0.02
Sleeve	55.00±5.0	75.66±10.7	700.40±124.4	2131.15±281.55	2907.2±416.6	23.95±0.8	0.34±0.02
Sham	45.0±5.0	79.25±13.5	713.35±175.3	2339.3±0.1	3131.9±188.8	22.55±4.2	0.35±0.0
<i>P</i>	0.200	0.062	0.081	0.069	0.108	0.165	0.081

**Figure 1: Total body weight (g ± standard error mean) of rabbits after surgeries (\**P* < 0.05)**

the rabbits' liver show mild portal infiltration and kidneys of two of them show mild tubulo-interstitial nephritis. In the sleeve group, transmural necrosis in one of the rabbits' stomach was seen, and it has not been shown any specific changes in others' brain, spleen, kidney, liver, and stomach after 3 months.

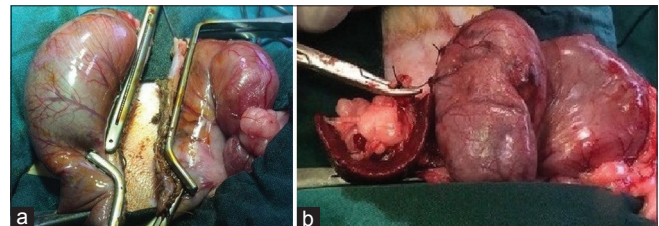
There was no significant pathological difference in bony trabecular thickness and arrangement among the three groups.

## Discussion

It is necessary to evaluate the body composition of patients in postoperative visits in order to diagnose the bone loss after bariatric surgeries. The dual-energy X-ray absorptiometry (DXA) is considered as the gold standard for the evaluation of body composition, but the use is limited due to its high cost.<sup>[17]</sup>

Comparing the mid-term and long-term effects of bariatric surgical procedures on laboratory animals can help prevent possible complications in patients with morbid obesity that is undergoing surgery. In this study, a comparison of weight loss among three groups of rabbits (fundectomy, sleeve, and sham) did not show a statistically significant difference [Figure 1].

The results of comparing body fat index showed that there was not a statistically significant difference in none of its factors, including bone mass content, fat mass, lean mass, total mass, fat percentage, and bone mass density, among the three groups of rabbits.

**Figure 2: The sleeve gastrectomy (a) and subsleeve gastrectomy (b) surgery**

Studies have shown that the DXA in measuring bone density is more sensitive to added soft tissue and changes in body composition than computerized tomography, which can affect the ability to detect changes over time.<sup>[18]</sup> However, there was no distinction in bone mass density in our study. The study conducted by Adamczyk *et al.* on 36 patients who underwent SG surgery showed that after 12 months, and the total amount of BMD was decreased, but the amount of fat, lean body mass and total mass were decreased significantly.<sup>[6]</sup> There was an inconsiderable decrease in bone density throughout the body and spine, which was not statistically significant. The overall rate of bone density in the hip bone and femoral head was significantly reduced in their study, which required a review of supplements used in patients and postoperative nutrition. Such as the Adamczyk study's lack of precise control of dietary and physical activity has been mentioned as limitations of the study.<sup>[6]</sup>

Many studies have reported a reduction in bone density after bariatric surgeries.<sup>[9,13,19]</sup> In general, the baseline of BMD in obese patients is higher than in the general population, and a small decrease in BMD after weight loss can be justified in this way.<sup>[11]</sup> The Hsin *et al.* study focused on getting enough micronutrients to try to control bone density loss, but still found a decrease in BMD after weight loss.<sup>[20]</sup> Due to differences in diet and supplementation intake after surgery in patients, more comparative studies are needed in different groups of patients.

According to the reports on histological changes after bariatric operations in other studies, samples of brain, spleen, kidney, liver, stomach, and femoral bone were prepared and evaluated in this study. Apart from necrosis of gastric tissue, which was observed in one of the rabbits of the sleeve group, the histological changes in different organs such as stomach, kidney, and liver were more in the fundectomy group.

Depending on the role of the stomach in maintaining calcium homeostasis in the body, different methods of bariatric surgeries can have different effects on bone density by creating changes in the structure of the stomach. In this study, femoral bone tissue was compared in three groups: sham, sleeve, and fundectomy groups; and there was no difference in their trabeculae and bone marrow space. In the study conducted by Lehto-Axtelius *et al.* on three rat groups, it was shown that osteopenic changes in calvaria in the fundectomy group is similar to the group in which gastrectomy was performed, but these changes are less in the group underwent antrectomy than in the other two groups, as well as enlarged bone marrow space in calvaria and loss of trabeculae in the tibia have also been reported after gastrectomy and fundectomy.<sup>[1]</sup> This difference in findings in the two studies could be due to differences in the time of investigation (Lehto *et al.* were examined at various times after the operations) and differences in animal model (Lehto *et al.* were used rats in their study).

Epidemiological studies have shown that obesity may be a risk issue for chronic nephropathy. Histological changes as secondary focal segmental sclerosis are more common in obese patients than in people who are in a normal range of weight.<sup>[21]</sup> In the present study, comparison of changes in renal histology was performed after bariatric surgeries, and no changes in renal tissue were observed in both sleeve and sham groups. In the group undergoing fundectomy, mild tubule interstitial nephritis was observed in 2 cases, and secondary focal segmental sclerosis was not reported in any groups.

Liver tissue pathological changes are present in a significant percentage of obese patients, and various studies have shown a comparative recovery after weight loss.<sup>[22,23]</sup> One of the shortcomings of this study was the lack of investigating pathological changes in the liver before and after surgery in each rabbit, and only a comparison of pathological changes among groups was performed, in which mild portal infiltration was shown in 3 rabbits of the fundectomy group. There was no difference among the three groups in terms of nonalcoholic fatty liver disease.

There are many differences in the results of various studies on bariatric surgical procedures regarding gastric histological changes after these surgeries.<sup>[24,25]</sup> In the present study, postoperative histological changes were observed only in the group of fundectomy as the mucosal congestion in the three rabbits. One of the rabbits in the sleeve group had some degrees of gastric necrosis. There were no significant histological changes in the sham group. Further studies should be performed to compare the results. The study conducted by Atef *et al.* on balloon placement in the stomach reported to reduce weight, local inflammation, and increased proliferative activity, which these were not observed in the present study.<sup>[24]</sup>

## Conclusion

Sub-SG did not show any significant effect on fat index and bone densitometry in comparison with SG. However, we found lower fat index in the sleeve group of rabbits.

## Acknowledgments

The authors thanks to the Vice-Chancellor of Shiraz University of Medical Sciences for support us.

## Financial support and sponsorship

Nil.

## Conflicts of interest

There are no conflicts of interest.

## References

1. Lehto-Axtelius D, Stenström M, Johnell O. Osteopenia after gastrectomy, fundectomy or antrectomy: An experimental study in the rat. *Regul Pept* 1998;78:41-50.
2. Krupski W, Tataru MR, Bury P, Szabelska A, Charuta A, Maciejewski R, *et al.* Negative effects of total gastrectomy on bone tissue metabolism and volumetric bone mineral density (vBMD) of lumbar spine in 1-year study in men. *Medicine (Baltimore)* 2016;95:e2817.
3. Arroyo-Johnson C, Mincey KD. Obesity epidemiology worldwide. *Gastroenterology Clin* 2016;45:571-9.
4. Organization WH. World Health Organization obesity and overweight fact sheet. 2016.
5. Whitlock G, Lewington S, Sherliker P, Clarke R, Emberson J, Halsey J, *et al.* Prospective Studies Collaboration: Body-mass index and cause-specific mortality in 900 000 adults: collaborative analyses of 57 prospective studies. *Lancet* 2009;373:1083-96.
6. Adamczyk P, Buźga M, Holéczy P, Švagera Z, Zonča P, Sievänen H, *et al.* Body Size, bone mineral density, and body composition in obese women after laparoscopic sleeve gastrectomy: A 1-year longitudinal study. *Hormone and Metabolic Res* 2015;47:873-9.
7. Yumuk V, Tsigos C, Fried M, Schindler K, Busetto L, Micic D, *et al.* Obesity Management Task Force of the European Association for the Study of O. European guidelines for obesity management in adults. *Obes Facts* 2015;8:402-24.
8. Geoffroy M, Charlot-Lambrecht I, Chrusciel J, Gaubil-Kaladjian I, Diaz-Cives A, Eschard JP, *et al.* Impact of bariatric surgery on bone mineral density: Observational study of 110 patients followed up in a specialized center for the treatment of obesity in France. *Obesity Surg* 2019;29:1765-72.
9. Vilarrasa N, San José P, García I, Gómez-Vaquero C, Miras PM, de Gordejuela AGR, *et al.* Evaluation of bone mineral density loss in morbidly obese women after gastric bypass: 3-year follow-up. *Obesity Surg* 2011;21:465-72.
10. Campanha-Versiani L, Pereira DAG, Ribeiro-Samora GA, Ramos AV, de Sander Diniz MFH, De Marco LA, *et al.* The effect of a muscle weight-bearing and aerobic exercise program on the body composition, muscular strength, biochemical markers, and bone mass of obese patients who have undergone gastric bypass surgery. *Obesity Surg* 2017;27:2129-37.
11. Lalmohamed A, de Vries F, Bazelier MT, Cooper A, Van Staa T-P, Cooper C, *et al.* Risk of fracture after bariatric surgery in the United Kingdom: population based, retrospective cohort study. *Bmj.* 2012;345:e5085.
12. Buźga M, Šmajstrla V, Bortlík L, Švagera Z, Závacká I,

- Holéczy P. Surprisingly low bone density in obese patients undergoing bariatric surgery. *Osteologicky Bulletin* 2012;17:43-9.
13. Coates PS, Fernstrom JD, Fernstrom MH, Schauer PR, Greenspan SL. Gastric bypass surgery for morbid obesity leads to an increase in bone turnover and a decrease in bone mass. *J Clin Endocrinology Metabolism* 2004;89:1061-5.
  14. de Vasconcelos RS, Viégas M, Marques TF, Diniz ET, Lucena CS, Neto JBC, *et al.* Factors associated with secondary hyperparathyroidism in premenopausal women undergoing Roux-en-y gastric bypass for the treatment of obesity. *Arquivos Brasileiros de Endocrinologia e Metabologia* 2010;54:233-8.
  15. Ferrario C, Giusti V. How to identify the risk for osteoporosis after bariatric surgery? *French Revue Medicale Suisse*. 2013;9:674-8.
  16. Bananzadeh A, Hosseini S V, Khazraei H, Lashkarizadeh MM, Ghahramani L, *et al.* Sleeve Gastrectomy vs. Fundus Resection in Bariatric Surgery (Animal Study), *Shiraz E-Med J* 2020;21:e95198.
  17. Silva LK. Technological assessment in health: bone densitometry and alternative therapies in postmenopausal osteoporosis. *Public Health Cad* 2003;19:987-1003.
  18. Knapp KM, Welsman JR, Hopkins SJ, Fogelman I, Blake GM. Obesity increases precision errors in dual-energy X-ray absorptiometry measurements. *J Clin Densitometry* 2012;15:315-9.
  19. Casagrande DS, Repetto G, Mottin CC, Shah J, Pietrobon R, Worni M, *et al.* Changes in bone mineral density in women following 1-year gastric bypass surgery. *Obesity Surg* 2012;22:1287-92.
  20. Hsin MC, Huang CK, Tai CM, Yeh LR, Kuo HC, Garg A. A case-matched study of the differences in bone mineral density 1 year after 3 different bariatric procedures. *Surg Obesity and Related Dis* 2015;11:181-5.
  21. Amann K, Benz K. Structural renal changes in obesity and diabetes. *Seminars Nephrol* 2013;33:23-33.
  22. Salman MA, Salman AA, Abdelsalam A, Atallah M, Shaaban HE, El-Mikkawy A, *et al.* Laparoscopic Sleeve Gastrectomy on the Horizon as a Promising Treatment Modality for NAFLD. *Obes Surg* 2020;30:87-95.
  23. Esquivel CM, Garcia M, Armando L, Ortiz G, Lascano FM, Foscarini JM. Laparoscopic Sleeve Gastrectomy Resolves NAFLD: Another Formal Indication for Bariatric Surgery? *Obes Surg* 2018;28:4022-33.
  24. Atef E, Zalata KR, Atef H, Abdel-Hamid AA. increased proliferative activity accompanies the local inflammatory response of gastric mucosa after intragastric balloon insertion. *Digestive Dis Sci* 2016;61:3498-505.
  25. Dietz J, Ulbrich-Kulczynski JM, Souto KE, Meinhardt NG. Prevalence of upper digestive endoscopy and gastric histopathology findings in morbidly obese patients. *Arquivos de gastroenterologia* 2012;49:52-5.