

## Case Report

# Masson's Tumor of the Distal Phalanx May Present Like a Felon, Report of a Rare Case

### Abstract

Also known as intravascular papillary endothelial hyperplasia, Masson's tumor is a relatively rare soft-tissue vascular tumor that usually arises in the hand. Felon is an abscess formation in the distal phalanx that usually occurs following a penetrating microtrauma. We present a 30-year-old patient who was referred to our clinic with a palpable mass in the distal phalanx of the index finger after a needle stick injury. At first, the lesion was treated as a felon but finally and after treatment failure, a complete reevaluation revealed the lesion to be a Masson's tumor of the distal phalanx.

**Keywords:** *Distal phalanx, felon, Masson's tumor*

### Introduction

First described by Pierre Masson in 1923,<sup>[1,2]</sup> Masson's tumor, also known as intravascular papillary endothelial hyperplasia (IPEH), vegetant intravascular hemangioendothelioma, intravascular angiomatosis, and Masson's pseudoangiosarcoma is a relatively rare soft tissue neoplasm. In his study of a 68-year-old male with a painful, ulcerated hemorrhoid, Masson reported a papillary endothelial tumor associated with thrombosis, fibrin deposits, and the consequent obliteration of the vascular lumen.<sup>[2]</sup>

Despite comprising only 2%–4% of all skin and soft-tissue vascular tumors,<sup>[3-6]</sup> multiple cases of Masson's tumors have been described arising in the hand, forearm, neck, oral mucosa, and salivary glands as well as in both arteries and veins.<sup>[6-10]</sup>

The importance of IPEH lies in the differential diagnosis of malignant vascular neoplasms, such as angiosarcoma, to avoid unnecessary aggressive treatment.<sup>[2]</sup> We herein report a patient with an unusual presentation of Masson's tumor of the hand.

### Case Report

A 30-year-old gentleman was referred to our outpatient clinic with a 1-month history of pain and swelling in the volar region of the distal phalanx of the index finger of his left

hand. The patient mentioned an accidental needle-stick injury of the index finger during a venous catheterization 1 week before the onset of the symptoms. His previous medical history was unremarkable. Physical examination revealed a round induration that was about 1.5 cm in diameter with mild tenderness on palpation with an unaffected range of motion of the distal interphalangeal joint [Figure 1]. Considering the history of needle stick injury and almost typical physical examination, a distal pulp felon was suspected and surgical drainage was done through a volar midline incision the same day. A short course of oral antibiotics was prescribed. The immediate postoperative period was uneventful. Eight months after the index surgery, the patient presented with a recurrence of his symptoms in the same anatomic site. This time, physical examination divulged a palpable tender bluish mass in the distal phalanx. A plain roentgenogram of the index finger was obtained, which revealed an ill-defined lytic lesion of the P3F2 bone with evident swelling of the surrounding soft tissue but without obvious calcification [Figure 2].

Magnetic resonance imaging revealed a large (20 × 9 mm) lobulated mass lesion within the soft tissue volar to the distal phalanx of the second finger, with a round low-signal area in favor of calcification. Also, cortical erosion and disruption in the nearby distal phalanx with bone marrow

**Alireza Manafi Rasi,  
Shahram Sayyadi<sup>1</sup>,  
Ali Pourmojarab,  
Mohamadsadegh  
Rezayian,  
Hassan Barati,  
Reza Tavakoli  
Darestani**

*Department of Orthopedic and Trauma Surgery, Shahid Beheshti University of Medical Sciences, <sup>1</sup>Department of Anesthesiology, School of Medicine, Imam Hossein Hospital, Shahid Beheshti University of Medical Sciences, Tehran, Iran*

### Address for correspondence:

*Dr. Reza Tavakoli Darestani,  
Department of Orthopedic and Trauma Surgery, Shahid Beheshti University of Medical Sciences, Tehran, Iran.  
E-mail: rezatavakolidarestani@yahoo.com*

**Received:** 15 June 2021

**Revised:** 2 August 2021

**Accepted:** 24 August 2021

**Published:** 29 April 2022

### Access this article online

**Website:** [www.advbiores.net](http://www.advbiores.net)

**DOI:** 10.4103/abr.abr\_170\_21

### Quick Response Code:




**How to cite this article:** Manafi Rasi A, Sayyadi S, Pourmojarab A, Rezayian M, Barati H, Tavakoli Darestani R. Masson's tumor of the distal phalanx may present like a felon, report of a rare case. *Adv Biomed Res* 2022;11:32.

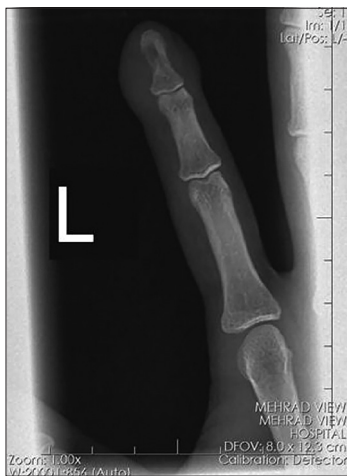This is an open access journal, and articles are distributed under the terms of the Creative Commons Attribution-NonCommercial-ShareAlike 4.0 License, which allows others to remix, tweak, and build upon the work non-commercially, as long as appropriate credit is given and the new creations are licensed under the identical terms.

For reprints contact: [WKHLRPMedknow\\_reprints@wolterskluwer.com](mailto:WKHLRPMedknow_reprints@wolterskluwer.com)

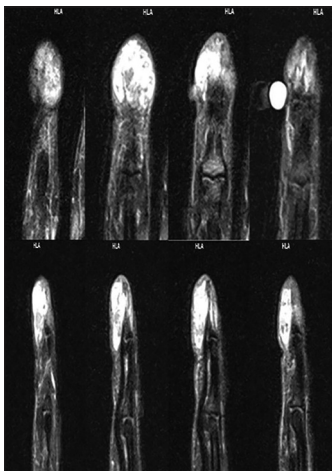
edema were evident. The lesion was in proximity to the collateral ligament but was independent of it [Figure 3]. A surgical excisional biopsy was planned. Upon incision,



**Figure 1:** The gross appearance of the lesion in the distal phalanx of the index finger



**Figure 2:** Roentgenogram showing a lytic lesion with ill-defined borders and swelling without calcification of soft-tissue



**Figure 3:** Magnetic resonance imaging showing the lobulated mass

an irregular multinodular mass lesion with tan-brown gross appearance and adhesions to the surrounding tissue was found. The specimen was sent for histopathologic examination. The microscopic examination showed a vascular proliferation composed of dilated medium to large caliber vascular spaces with IPEH and the presence of highly eosinophilic appearance in a few of the papillary stalks without evidence of necrosis, atypia, or atypical mitosis. These findings corresponded to the diagnosis of an IPEH or Masson's hemangioma.

## Discussion

Masson's tumor represents approximately 2% of benign and malignant vascular tumors of the skin and subcutaneous tissues,<sup>[11]</sup> which are found more frequently in women than in men, but they show no age or race predilection.<sup>[12,13]</sup>

Masson's tumor presents most commonly in the third and fourth decades of life. Despite the fact that it is predominately found in the skin and subcutis of the fingers and head and neck regions, there are reports of lesions arising in the oral soft tissues, mandible, thyroid, tongue, orbit, maxillary sinus, superior vena cava, popliteal artery, lung, parotid gland, cervix, renal vein, adrenal gland, and liver.<sup>[9,12-16]</sup>

There are generally three distinct recognized types: (1) a primary (pure) form that occurs in dilated vessels, (2) a secondary (mixed) form that exists in varices, hemangiomas, pyogenic granulomas, and lymphangiomas, and (3) an extravascular form that occurs very infrequently.<sup>[7]</sup>

On histochemical staining, an abundance of vascular papillary formations and irregularly organized capillaries differentiate Masson's tumors from other vascular tumors.<sup>[14]</sup> Although intravascular epithelial papillary hyperplasia is a benign process, accurate histopathologic diagnosis is crucial because of its similarity to other vascular tumors, particularly angiosarcomas, which are unlike.

Masson's tumors are malignant and have a predilection for recurrence after resection.<sup>[7]</sup>

A felon is a subcutaneous abscess of the distal pulp of a finger or thumb usually after a traumatic event that generally requires antibiotics with or without drainage.

In our patient, the physical examination disclosed a tender, palpable mass in the distal phalanx that started appearing after a needle stick injury. The final diagnosis of Masson's tumor indicates that the initial presentation of this entity could be misleading and a more precise evaluation and a high degree of clinical suspicion are needed for a timely and proper diagnosis of the lesion.

## Declaration of patient consent

The authors certify that they have obtained all appropriate patient consent forms. In the form the patient(s) has/have given his/her/their consent for his/her/their images and

other clinical information to be reported in the journal. The patients understand that their names and initials will not be published and due efforts will be made to conceal their identity, but anonymity cannot be guaranteed.

#### Financial support and sponsorship

Nil.

#### Conflicts of interest

There are no conflicts of interest.

#### References

1. Masson P. Hemangioendotheliome végétant intravasculaire. *Bull Soc Anat (Paris)* 1923;93:517-23.
2. Espinosa A, González J, García-Navas F. Intravascular papillary endothelial hyperplasia at foot level: A case report and literature review. *J Foot Ankle Surg* 2017;56:72-4.
3. Clifford PD, Temple HT, Jorda M, Marecos E. Intravascular papillary endothelial hyperplasia (Masson's tumor) presenting as a triceps mass. *Skeletal Radiol* 2004;33:421-5.
4. Schwartz SA, Taljanovic MS, Harrigal CL, Graham AR, Smyth SH. Intravascular papillary endothelial hyperplasia: Sonographic appearance with histopathologic correlation. *J Ultrasound Med* 2008;27:1651-3.
5. Lee SH, Suh JS, Lim BI, Yang WI, Shin KH. Intravascular papillary endothelial hyperplasia of the extremities: MR imaging findings with pathologic correlation. *Eur Radiol* 2004;14:822-6.
6. Lysy O, Schwartz I, Kolander Y, Strauss S. Sonographic features of intravascular papillary endothelial hyperplasia (Masson's tumor) in the forearm. *J Clin Ultrasound* 2011;39:301-3.
7. Bologna-Molina R, Amezcua-Rosas G, Guardado-Luevanos I, Mendoza-Roaf PL, González-Montemayor T, Molina-Frechero N. Intravascular papillary endothelial hyperplasia (Masson's Tumor) of the mouth – A case report. *Case Rep Dermatol* 2010;2:22-6.
8. Sartore L, Voltan A, Tomat V, Bassetto F, Salmaso R. Masson's disease in hand surgery: A clinicopathologic study of four cases. *J Hand Surg Eur Vol* 2011;36:694-7.
9. Pantanowitz L, Duke WH. Intravascular lesions of the hand. *Diagn Pathol* 2008;3:24.
10. Chang K, Barlaben A, Farley S. Masson's tumor in the ulnar artery. *J Vasc Surg* 2012;56:223-5.
11. Akhtar M, Aslam M, Al-Mana H, Bamefleh H, Al-Khateeb SS, Lindstedt E. Intravascular papillary endothelial hyperplasia of renal vein: Report of 2 cases. *Arch Pathol Lab Med* 2005;129:516-9.
12. Meadows MC, Sun X, Dardik M, Tarantino DR, Chamberlain RS. Intraabdominal intravascular papillary endothelial hyperplasia (Masson's tumor): A rare and novel cause of gastrointestinal bleeding. *Case Rep Gastroenterol* 2010;4:124-32.
13. Wagh VB, Kyprianou I, Burns J, Brown LJ, Vaidhyanath R, Sampath R. Periorbital Masson's tumor: A case series. *Ophthalmic Plast Reconstr Surg* 2011;27:e55-7.
14. Susini T, Molino C, Castiglione F, Olivieri S. Masson's vegetant hemangioendothelioma arising in the uterine cervix during pregnancy: A case report. *J Womens Health (Larchmt)* 2010;19:1759-62.
15. Shah AK, Grant I. Intravascular papillary endothelial hyperplasia (Masson's tumour) causing a soft-tissue mass in the upper limb. *Hand Surg* 2010;15:31-3.
16. McMahon GS, Mikhail HM, Molyneux AJ, Thomas DV, Hicks RC. "Masson's pseudoangiosarcoma" in a popliteal aneurysm: Tumor or thrombus? Cause or effect? *Ann Vasc Surg* 2010;24:257.e1-3.